SECTION IV

Neuroscience

Peripheral Nervous System

1

Neural tube
Skeletal motor neurons
preganglionic aut. neurons

Neural crest
sensory neurons
postganglionic autonomic neurons → all ganglia in PNS (either)
chromaffin
Schwann cells

CELLULAR ELEMENTS

The peripheral nervous system (PNS) contains cranial and spinal nerves that consist of neurons that give rise to axons, which grow out of the neural tube, and neurons derived from neural crest cells. Skeletal motor neurons and axons of preganglionic autonomic neurons are derived from the neural tube (Figs IV-1-1, IV-1-2, IV-1-3, IV-1-4, and IV-1-5).

Neural crest cells form sensory neurons and postganglionic autonomic neurons. The neuronal cell bodies of these neurons are found in ganglia. Therefore, all ganglia found in the PNS contain either sensory or postganglionic autonomic neurons and are derived from neural crest cells.

Chromaffin cells are neural crest cells, which migrate into the adrenal medulla to form postganglionic sympathetic neurons.

Schwann cells are glial cells that make myelin for PNS axons. Unlike oligodendrocytes, which make CNS myelin, individual Schwann cells myelinate only a small part of a single axon. At the junction between two Schwann cells, there are discontinuities in the myelin called nodes of Ranvier. Here, action potentials skip from node to node in saltatory conduction.

Clinical Correlate

Peripheral Neuropathies

Peripheral neuropathies such as Guillain-Barré syndrome affect PNS myelinated axons.

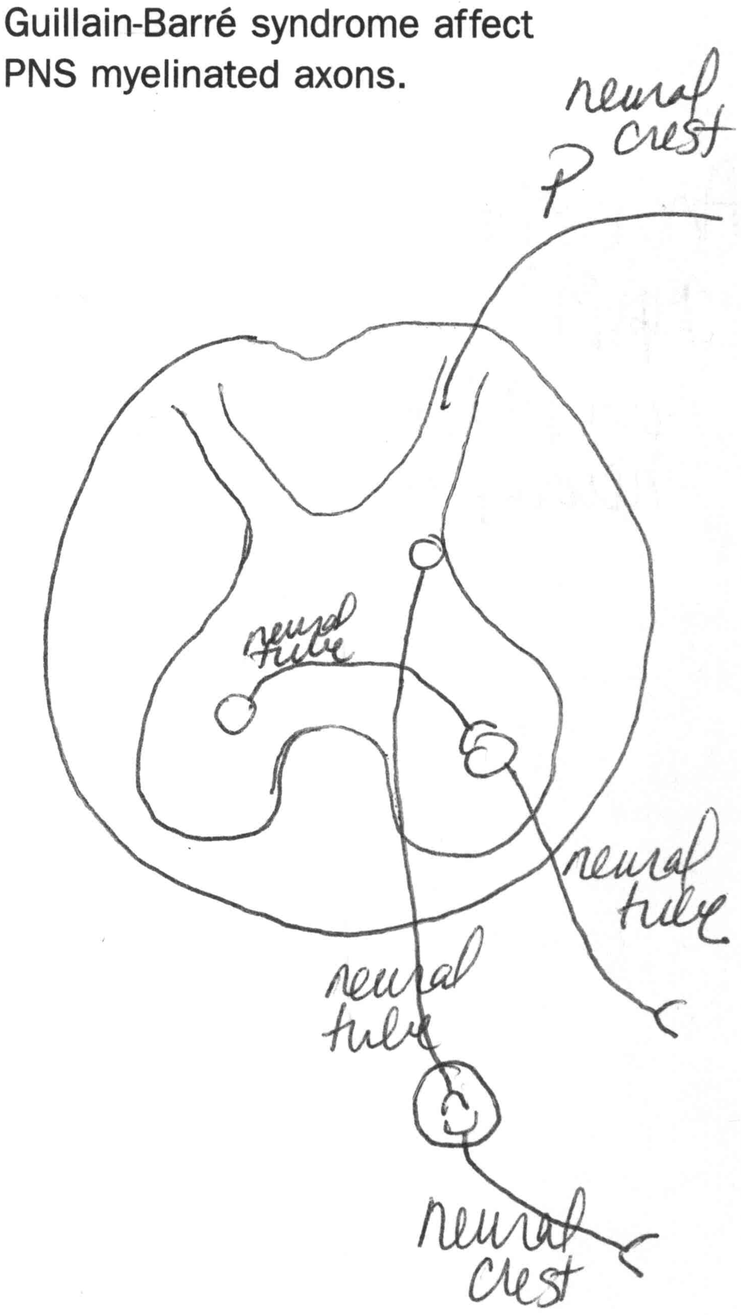

Clinical Correlate

Reduced levels of alpha-feto protein are seen in mothers of fetuses with Down syndrome.

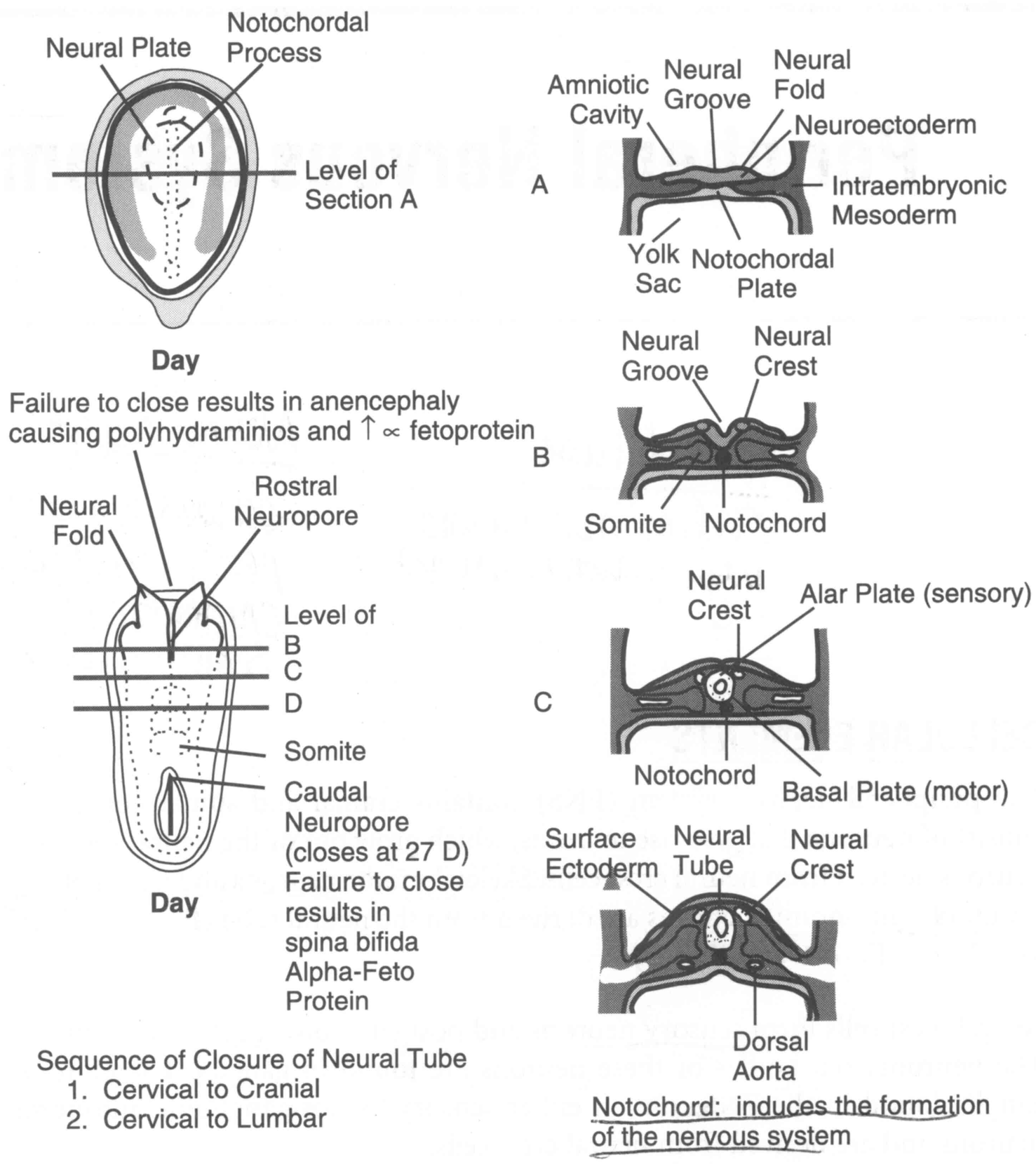

Figure IV-1-1. Third Week–Neurulation

Anencephaly:
↑AFP
any ↑AFP caused by neural tube defect

Table IV-1-1. Germ Layer Derivatives

Ectoderm	Mesoderm	Endoderm
Surface ectoderm	Muscle	**Forms Epithelial parts of:**
Epidermis	Smooth	Tonsils
Hair	Cardiac	Thymus
Nails	Skeletal	Pharynx
Inner ear	Connective tissue	Larynx
Enamel of teeth	All serous membranes	Trachea
Lens of eye	Bone and cartilage	Bronchi
Anterior pituitary	Blood, lymph, cardiovascular organs	Lungs
Parotid gland	Adrenal cortex	Urinary bladder
	Gonads and internal reproductive organs	Urethra
Neuroectoderm	Spleen	Tympanic cavity
Neural tube	Kidney and ureter	Auditory tube
Central nervous system	Duramater	GI tract
Retina		
Pineal gland		**Forms parenchyma of:**
Neurohypophysis		Liver
Glial Cells		Pancreas
		Tonsils
Neural crest		Thyroid gland
Adrenal Medulla		Parathyroid glands
Ganglia		Glands of the GI tract
Sensory		Submandibular gland
Autonomic		Sublingual gland
Pigment cells		
Schwann cells		
Satellite cells		
Meninges		
Pia and arachnoid mater		
Pharyngealarch cartilage		
Odontoblasts		
Parafollicular (C) cells		
Aorticopulmonary septum		
Endocardial cushions		

Yolk sac derivatives:

Primordial germ cells
Early blood and blood vessels
Epithelia of the gut not derived from endoderm

AUTONOMIC NERVOUS SYSTEM: GENERAL ORGANIZATION

The Autonomic Nervous System (ANS) is responsible for the motor innervation of smooth muscle, cardiac muscle, and glands of the body. The ANS is composed of two divisions: (1) Sympathetic and (2) Parasympathetic.

In both divisions there are two neurons in the peripheral distribution of the motor innervation.

1. Preganglionic neuron with cell body in CNS
2. Postganglionic neuron with cell body in a ganglion in the PNS.

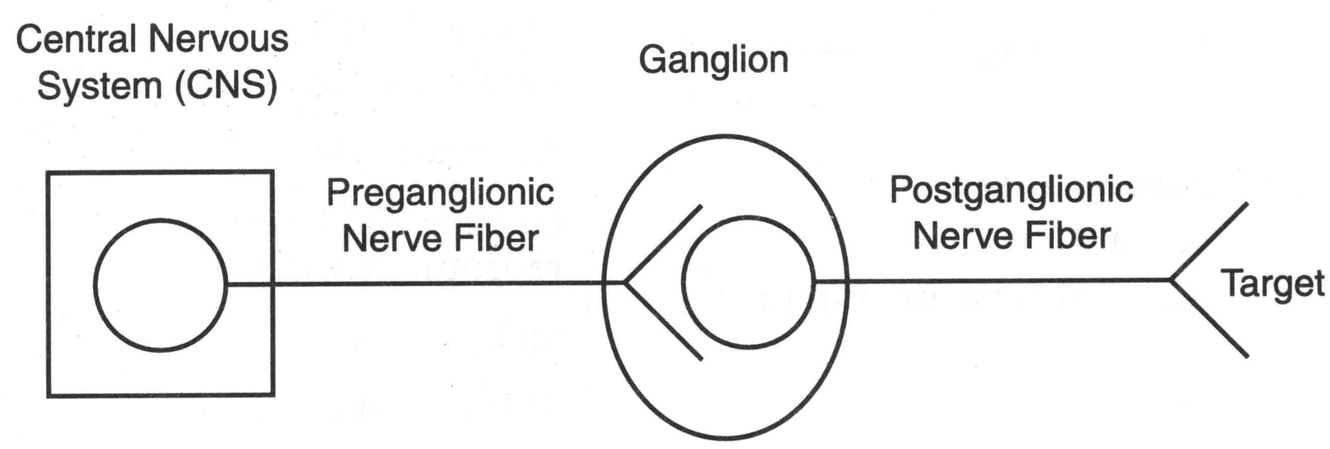

Figure IV-1-2. Autonomic Nervous System

Table IV-1-2. Sympathetic = Thoracolumbar Outflow

Origin	Site of Synapse	Innervation
Spinal cord levels T1-L2	Sympathetic chain ganglia (paravertebral ganglia)	Smooth muscle, cardiac muscle and glands of body wall and limbs, head and thoracic viscera.
Thoracic splanchnic nerves T5-12	Prevertebral ganglia, abdom. aorta (e.g. celiac, aorticorenal superior mesenteric ganglia synapse near organ they supply	Smooth muscle and glands of the foregut and midgut
Lumbar splanchnic nerves L 1, 2	Prevertebral ganglia, e.g. inferior mesenteric and pelvic ganglia	Smooth muscle and glands of the pelvic viscera and hindgut

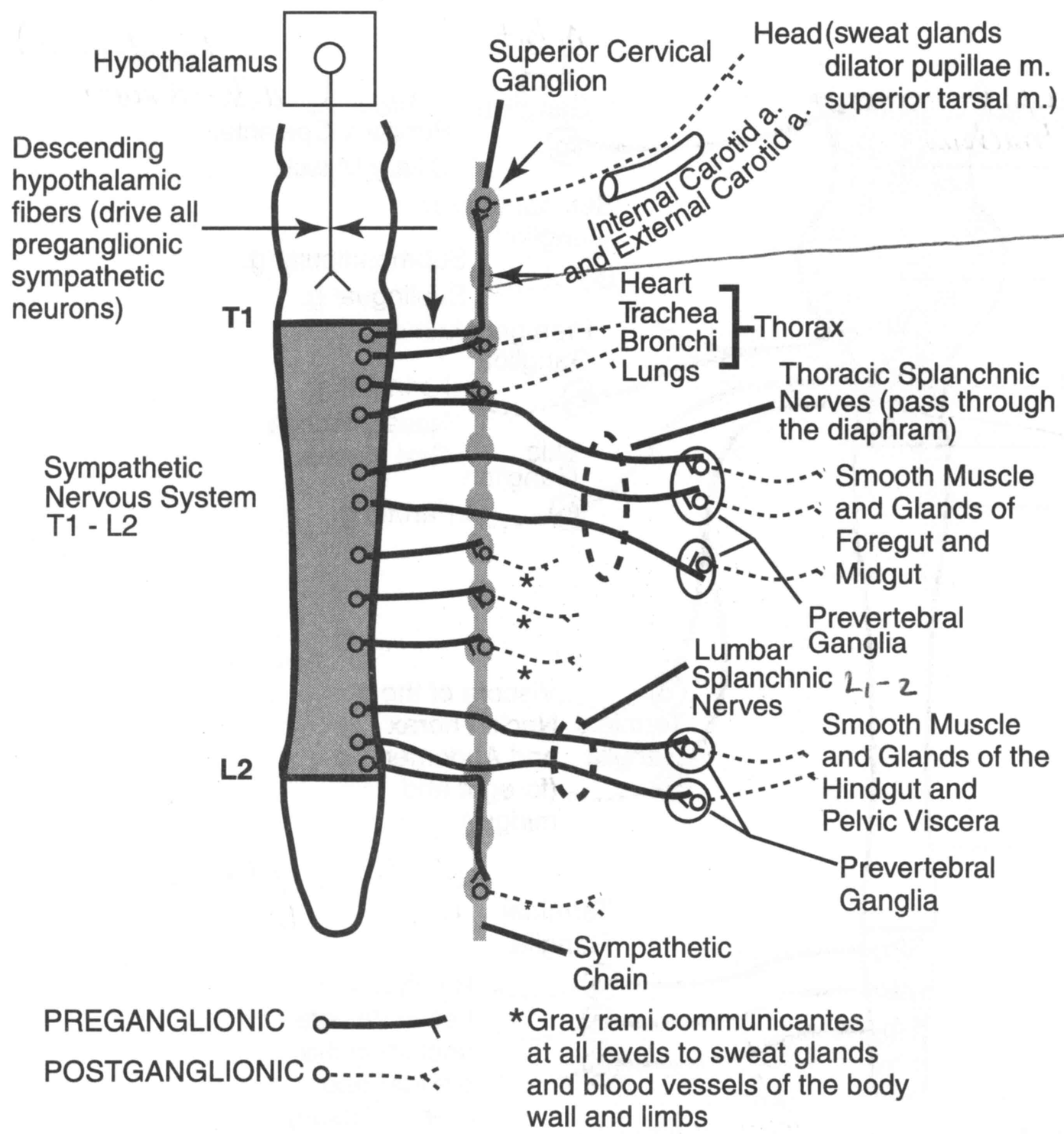

Figure IV-1-3. Overview of Sympathetic Outflow

Clinical Correlate

Lesions at arrows result in Horner's syndrome.
- partial ptosis
- miosis
- anhydrosis (w/o sweat)

lesion in desc. hypothalamic fibers → also can give Horners syndrome.

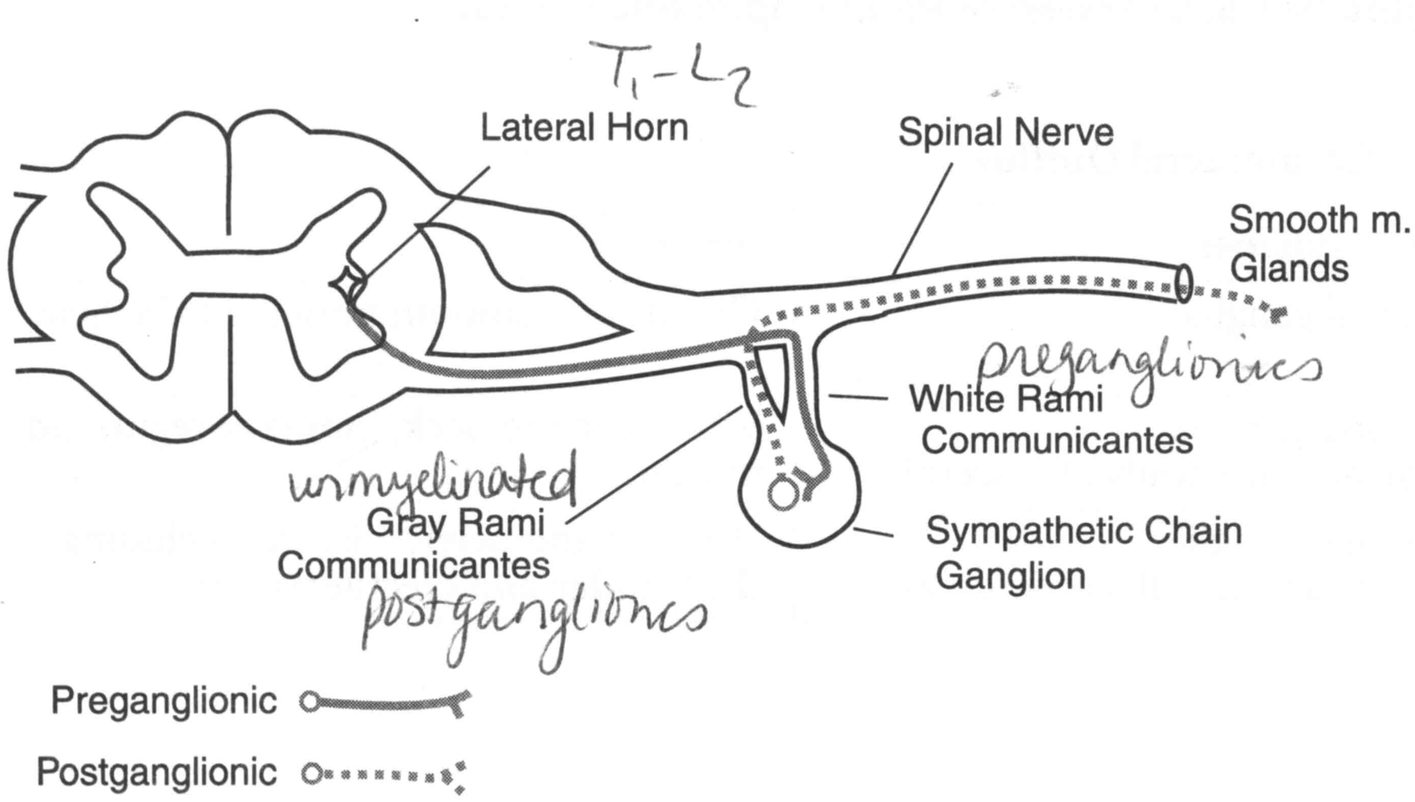

Figure IV-1-4. Spinal Cord Showing Sympathetic Outflow T1-L2

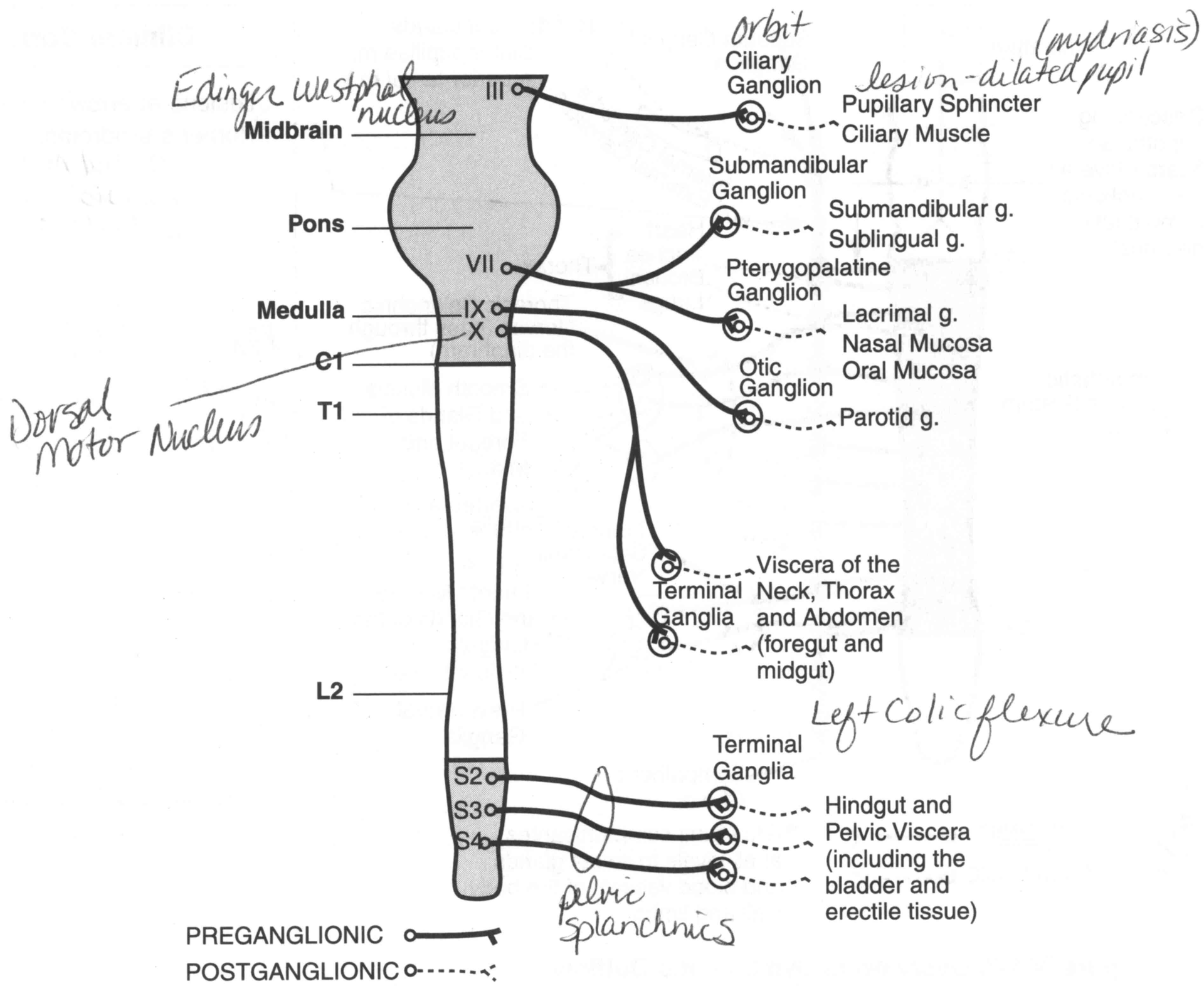

Figure IV-1-5. Overview of Parasympathetic Outflow

Table IV-1-3. Parasympathetic = Craniosacral Outflow

Origin	Site of synapse	Innervation
Cranial nerves III, VII, IX	4 cranial ganglia	Glands and smooth muscle of the head
Cranial nerve X	Terminal ganglia (in or near the walls of viscera)	Viscera of the neck, thorax, foregut, and midgut
Pelvic splanchnic nerves S 2, 3, 4	Terminal ganglia (in or near the walls of viscera)	Hindgut and pelvic viscera (including the bladder and erectile tissue)

Central Nervous System

2

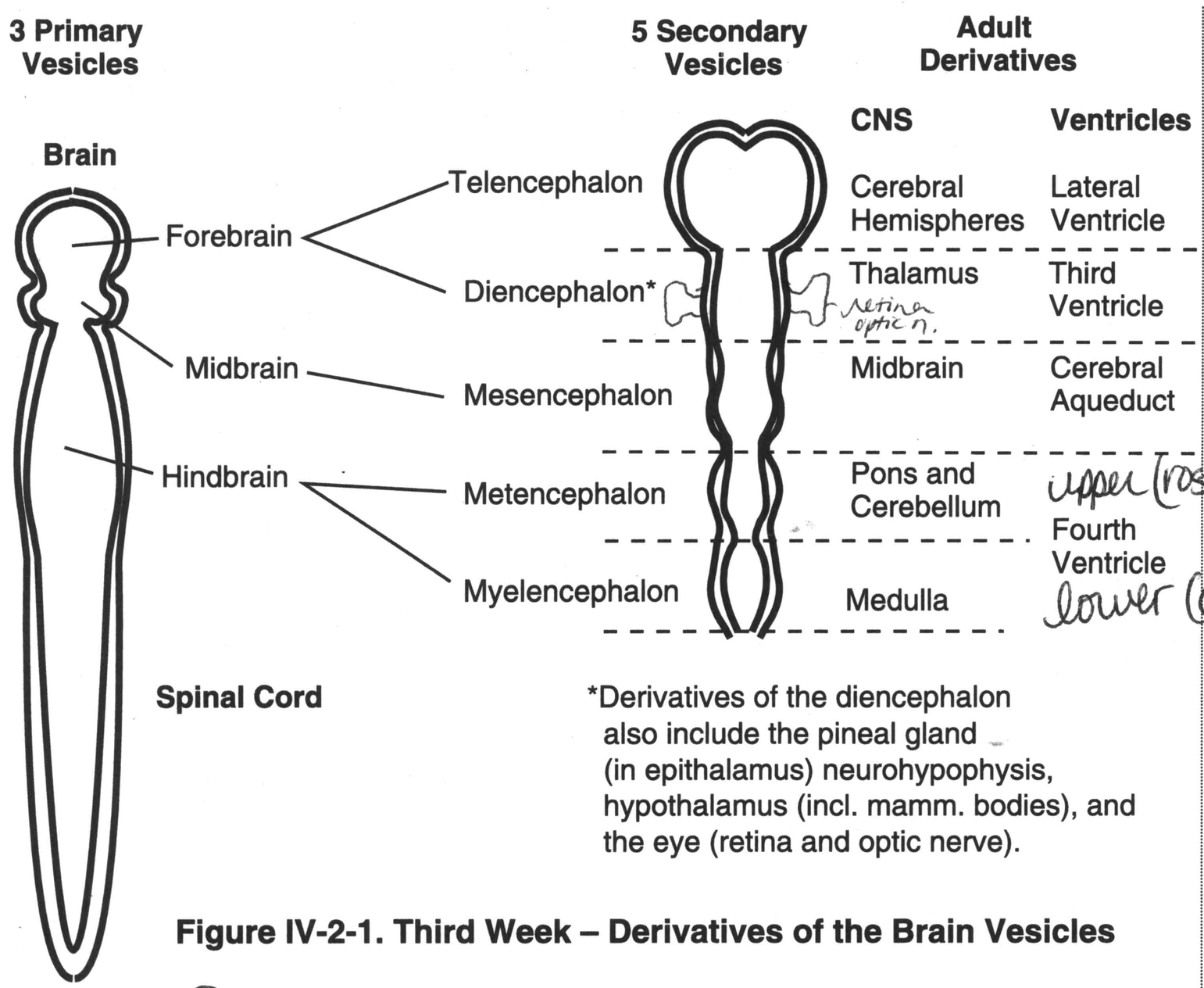

Figure IV-2-1. Third Week – Derivatives of the Brain Vesicles

The roots of 31 spinal nerves enter or exit segmentally from the spinal cord.

The anterior pituitary (adenohypophysis) is an outgrowth of oral ectoderm (Rathke's pouch) and is not derived from the CNS.

Clinical Correlate

Remnants of Rathke's pouch form cranio pharyngiomas that compress optic chiasm.

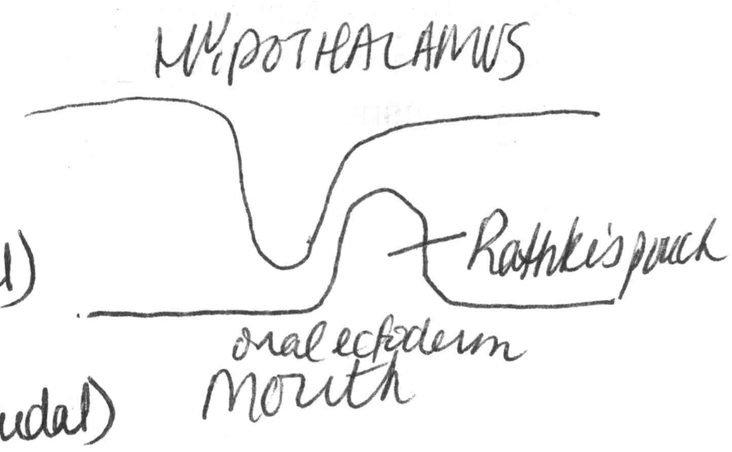

Clinical Correlate

Axonal polyneuropathies produce distal "glove and stocking" weakness or sensory deficits, and are related to axonal transport failure. Diabetes mellitus patients present with sensory neuropathies.

Clinical Correlate

Axons utilize anterograde and retrograde axonal transport to move subcellular elements toward or away from the axon terminal. Anterograde transport utilizes microtubules, is mediated by Kinesin, and moves vesicles and protein to the axon terminal. Retrograde axonal transport also uses microtubules, is mediated by dynein, and transports lysosomes and recycled membrane. Exogenous substances such as herpesvirus, polio virus, and tetanus toxin affect neuron cell bodies as a result of retrograde axonal transport.

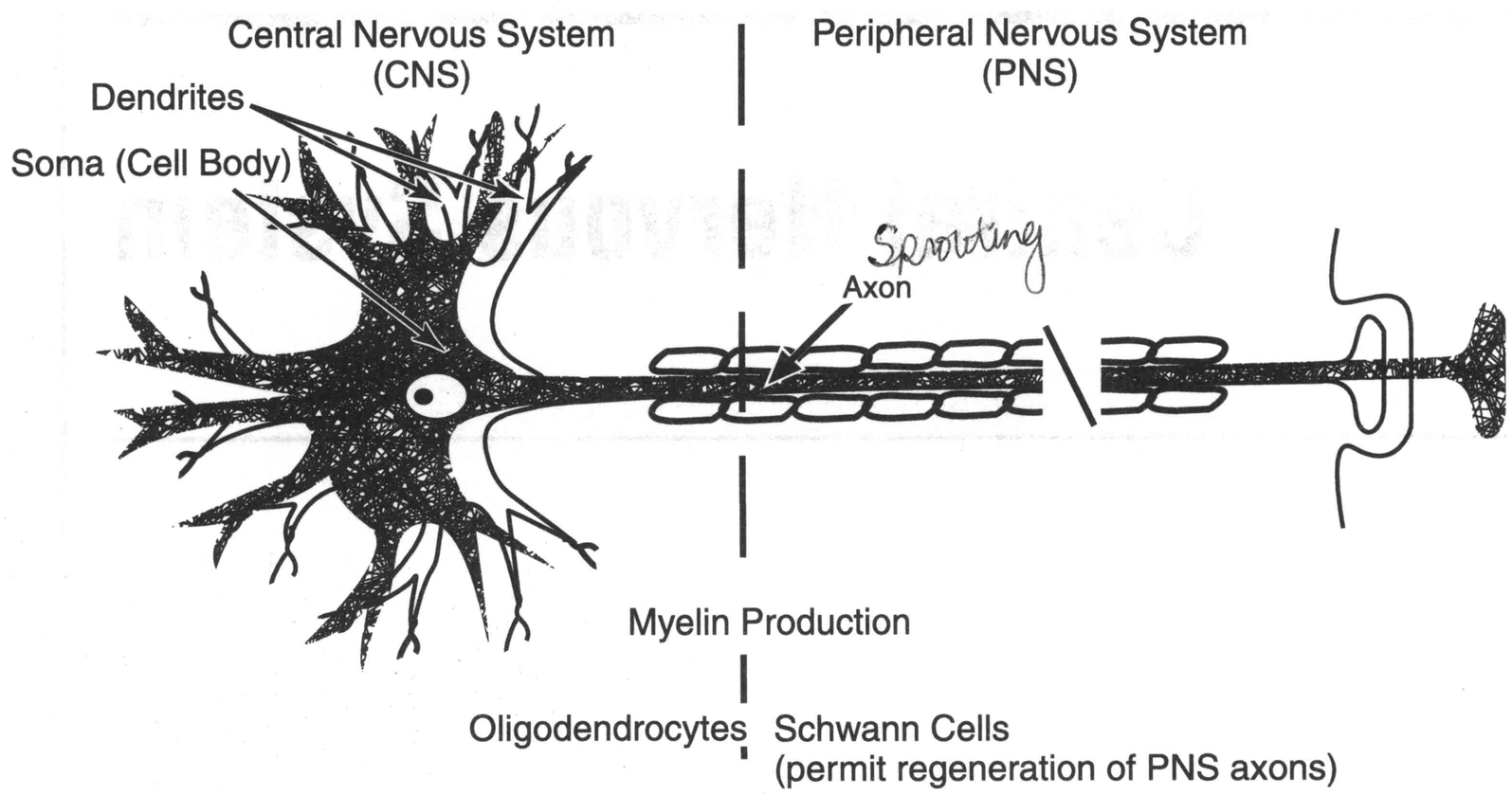

Figure IV-2-2. The Neuron

A. Spina Bifida Occulta: a defect in the vertebral arches; asymptomatic.

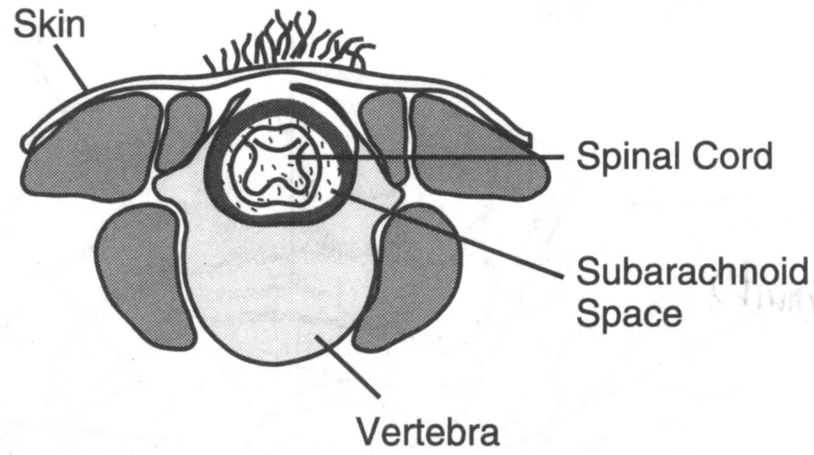

Spina Bifida Cystica

Spina Bifida Cystica

B. Spina Bifida with Meningocele: occurs when the meninges project through the vertebral defect; elevated alpha-feto protein levels.

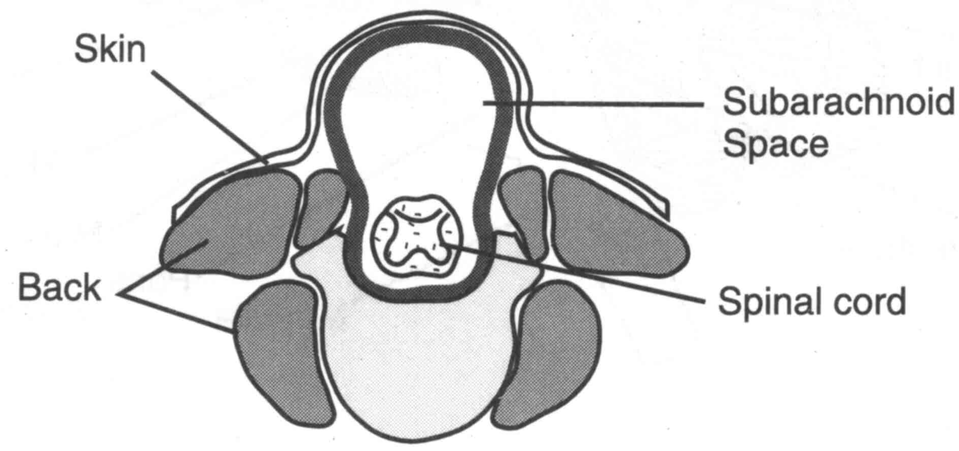

C. Spina Bifida with Meningomyelocele: occurs when the meninges and spinal cord project through the vertebral defect; elevated alpha-feto protein levels.

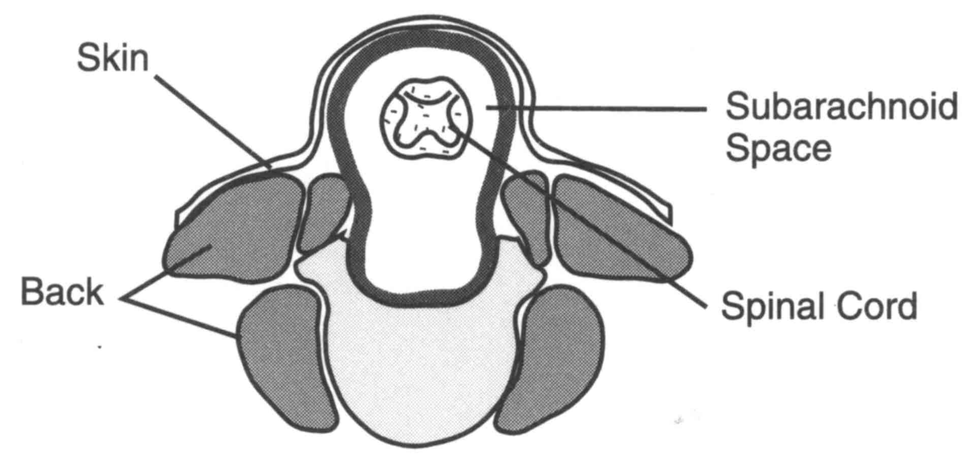

Arnold Chiari syndrome
↳ lower part of brain stem slides through foramen magnum and drags cerebellum through to tonsils

D. Spina Bifida with Myeloschisis: results in an open neural tube that lies on the surface of the back; most severe variation; elevated alpha-feto protein levels.

Rachischisis

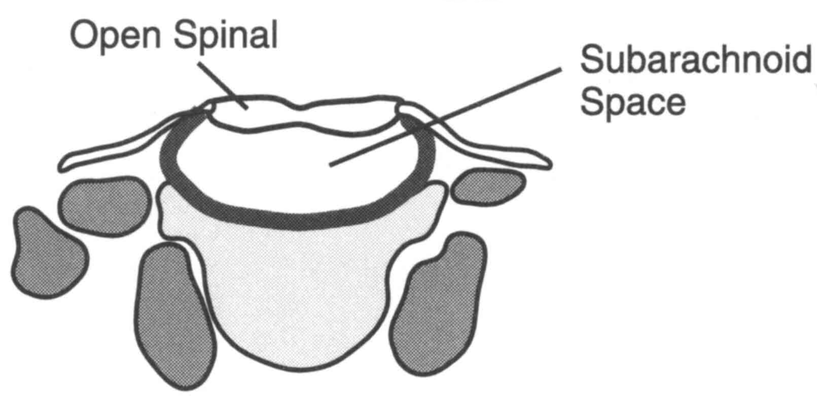

Figure IV-2-3. Malformations of the Vertebral Column or Spinal Cord

To prevent Spina Bifida folic acid

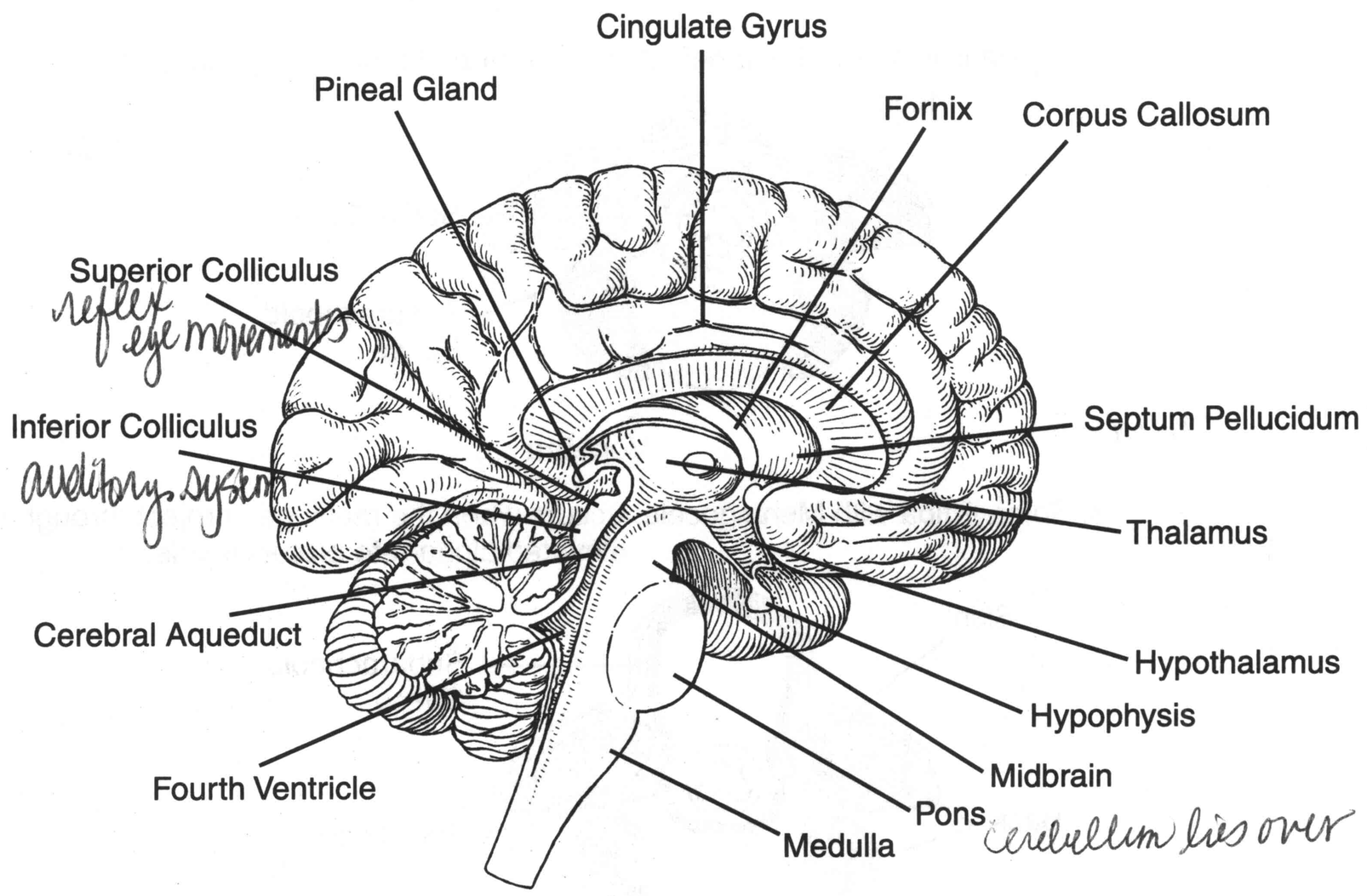

Figure IV-2-4 Brain: Sagittal Section

All cranial n. exit ventrally
except trochlear (IV) it exits dorsally

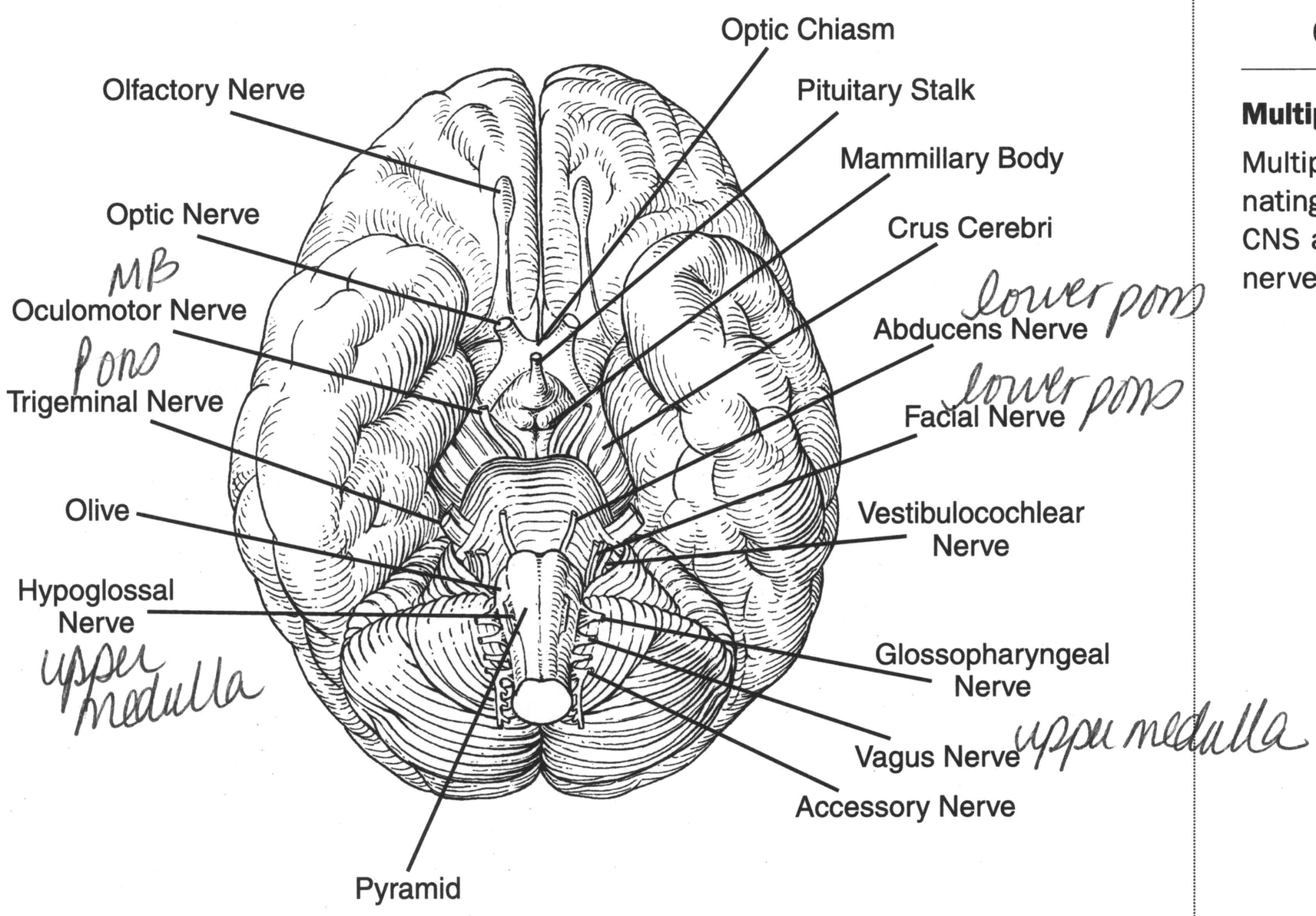

Figure IV-2-5. Brain: Inferior View

Clinical Correlate

Multiple Sclerosis

Multiple sclerosis is a demyelinating disease, which affects CNS axons including the optic nerve, but not other nerves.

Cellular Elements

Neurons of the neural tube form all CNS interneurons, skeletal motoneurons, and preganglionic autonomic neurons.

Skeletal motoneurons and preganglionic autonomic neurons send their axons out of the CNS in cranial and spinal nerves.

Glial cells derived from the neural tube include ependymal cells, astrocytes, and oligodendrocytes.

Ependymal cells line the ventricles. Cilia on their luminal surfaces move CSF.

Astrocytes control the microenvironment of CNS neurons and participate in the blood–brain barrier. They also guide migrating cortical neurons in development and proliferate in response to CNS injury.

Oligodendrocytes form myelin for axons in the CNS. An individual oligodendrocyte is able to myelinate as many as 50 axons. In the CNS, myelination begins during the fourth month of development and continues into the second decade of life. Microglia are derived from mesoderm, migrate into the CNS, and act as scavengers to devour cellular debris after injury.

The Ventricular System

3

The brain and spinal cord float within a protective bath of cerebrospinal fluid (CSF), which is produced continuously by the choroid plexus within the ventricles of the brain.

Each part of the CNS contains a component of the ventricular system. There are four interconnected ventricles in the brain: two lateral ventricles, a third ventricle, and a fourth ventricle. A lateral ventricle is located deep within each cerebral hemisphere. Each lateral ventricle communicates with the third ventricle via an interventricular foramen (foramen of Monro). The third ventricle is found in the midline within the diencephalon and communicates with the fourth ventricle via the cerebral aqueduct (of Sylvius), which passes through the midbrain. The fourth ventricle is located between the dorsal surfaces of the pons and upper medulla and the ventral surface of the cerebellum. The fourth ventricle is continuous with the central canal of the lower medulla and spinal cord (Fig IV-3-1).

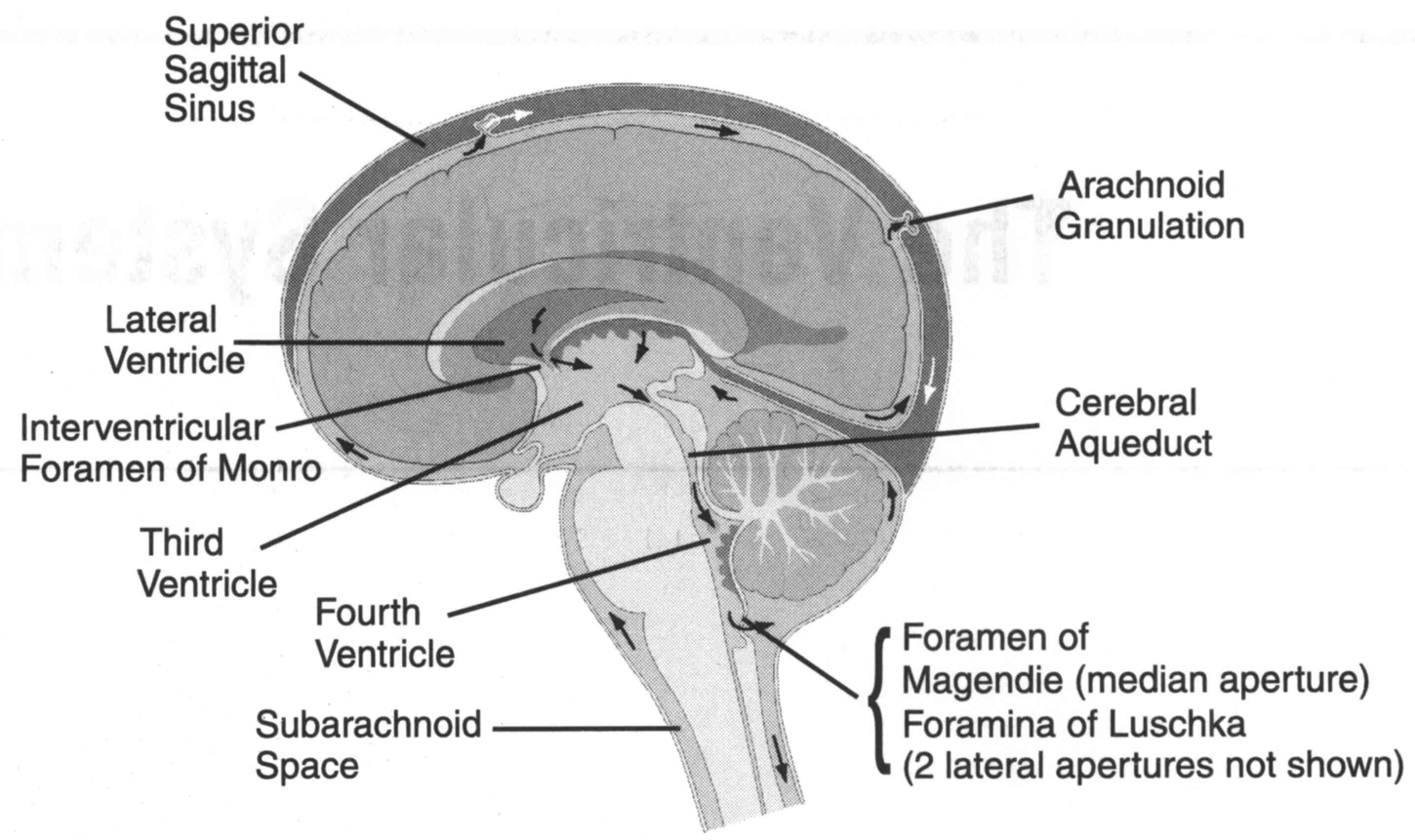

Figure IV-3-1. Sagittal Section of the Brain

CSF DISTRIBUTION, SECRETION, AND CIRCULATION

CSF fills the subarachnoid space and the ventricles of the brain. The average adult has 90 to 150 mL of total CSF, although 400 to 500 mL is produced daily. Only 25 mL of CSF is found in the ventricles themselves.

tight junctions
blood-CSF barrier

Approximately 70% of the CSF is secreted by the choroid plexus, which consists of glomerular tufts of capillaries covered by ependymal cells that project into the ventricles (the remaining 30% represents metabolic water production). The choroid plexus is located in parts of each lateral ventricle, the third ventricle, and the fourth ventricle.

CSF from the lateral ventricles passes through the interventricular foramina of Monro into the third ventricle. From there, CSF flows through the aqueduct of Sylvius into the fourth ventricle. The only sites where CSF can leave the ventricles and enter the subarachnoid space outside the CNS are through three openings in the fourth ventricle, two lateral foramina of Luschka and the median foramen of Magendie.

Within the subarachnoid space, CSF also flows up over the convexity of the brain and around the spinal cord. Almost all CSF returns to the venous system by draining through arachnoid granulations into the superior sagittal dural venous sinus.

Normal CSF is a **clear** fluid, isotonic with serum (290–295 mOsm/L).

The pH of CSF is 7.33 (arterial blood pH, 7.40; venous blood pH, 7.36).

Sodium ion (Na^+) concentration is equal in serum and CSF (≈138 mEq/L).

CSF has a higher concentration of chloride (Cl^-) and magnesium (Mg^{2+}) ions than does serum.

CSF has a lower concentration of potassium (K^+), calcium (Ca^{2+}), and bicarbonate (HCO_3^-) ions, as well as glucose, than does serum.

The concentration of protein (including all immunoglobulins) is much lower in the CSF as compared with serum.

Normal CSF contains 0 to 4 lymphocytes or mononuclear cells per cubic millimeter. Although the presence of a few monocytes or lymphocytes is normal, the presence of polymorphonuclear leukocytes is always abnormal, as in bacterial meningitis.

Red blood cells (RBCs) are not normally found in the CSF but may be present after traumatic spinal tap or subarachnoid hemorrhage.

Increased protein levels may indicate a CNS tumor.

Tumor cells may be present in the CSF in cases with meningeal involvement.

The Blood–Brain Barrier and the Blood–CSF Barrier

The chemical integrity of the brain is protected in a different way by two separate systems.

The Blood–Brain Barrier

The blood–brain barrier is formed by capillary endothelium connected by tight junctions. Astrocytes participate in the maintenance of the blood–brain barrier. They have numerous long processes with expanded vascular end-feet, or pedicels, which attach to the walls of capillaries.

Water diffuses across the blood–brain barrier readily, but glucose, the primary energy source of the brain, requires carrier-mediated transport. Active transport systems are capable of pumping weak organic acids, halides, and extracellular K^+ out of the brain against their respective concentration gradients.

Clinical Correlate

CSF Abnormalities

Hydrocephalus is caused by an excess volume or pressure of CSF, producing ventricular dilatation.

Communicating hydrocephalus is caused by oversecretion of CSF without obstruction in the ventricles or by CSF circulation or absorption problems from the subarachnoid space. Choroid plexus papilloma is a possible cause of oversecretion, a tumor in the subarachnoid space limits circulation, or meningitis may limit absorption into the superior sagittal sinus.

Noncommunicating hydrocephalus is caused by obstruction to the CSF flow inside the ventricular system at a foramen of Monro, in the cerebral aqueduct, or in the fourth ventricle. CSF is prevented from exiting through the foramina of Magendie or Luschka in the fourth ventricle into the subarachnoid space.

Normal pressure hydrocephalus results when CSF is not absorbed by arachnoid villi and the ventricles are enlarged, pressing the cortex against the skull. Patients present with confusion, ataxia, and urinary incontinence.

The Blood–CSF Barrier

Tight junctions located along the epithelial cells of the choroid plexus form the blood–CSF barrier. Transport mechanisms are similar to those described for the blood–brain barrier, although the ability of a substance to enter the CSF does not guarantee it will gain access to the brain.

The Spinal Cord

4

GENERAL FEATURES

The spinal cord is housed in the vertebral canal. It is continuous with the medulla below the pyramidal decussation and terminates as the conus medullaris at the second lumbar vertebra of the adult. The roots of 31 pairs of spinal nerves arise segmentally from the spinal cord.

Brachial Plexus C_5-T_1

There are eight cervical pairs of spinal nerves (C1 through C8). The cervical enlargement (C5 through T1) gives rise to the rootlets that form the brachial plexus, which innervates the upper limbs.

There are 12 thoracic pairs of spinal nerves (T1 through T12). Spinal nerves emanating from thoracic levels innervate most of the trunk.

There are five lumbar pairs of spinal nerves (L1 through L5). The lumbar enlargement (L1 through S2) gives rise to rootlets that form the lumbar and sacral plexuses, which innervate the lower limbs.

There are five sacral pairs of spinal nerves (S1 through S5). Spinal nerves at the sacral level innervate part of the lower limbs and the pelvis.

There is one coccygeal pair of spinal nerves. The cauda equina consists of the dorsal and ventral roots of the lumbar, sacral, and coccygeal spinal nerves.

Inside the spinal cord, gray matter is centrally located and shaped like a butterfly. It contains neuronal cell bodies, their dendrites, and the proximal parts of axons. White matter surrounds the gray matter on all sides. White matter contains bun-

dles of functionally similar axons called tracts or fasciculi, which ascend or descend in the spinal cord (Figs IV-4-1 and IV-4-2).

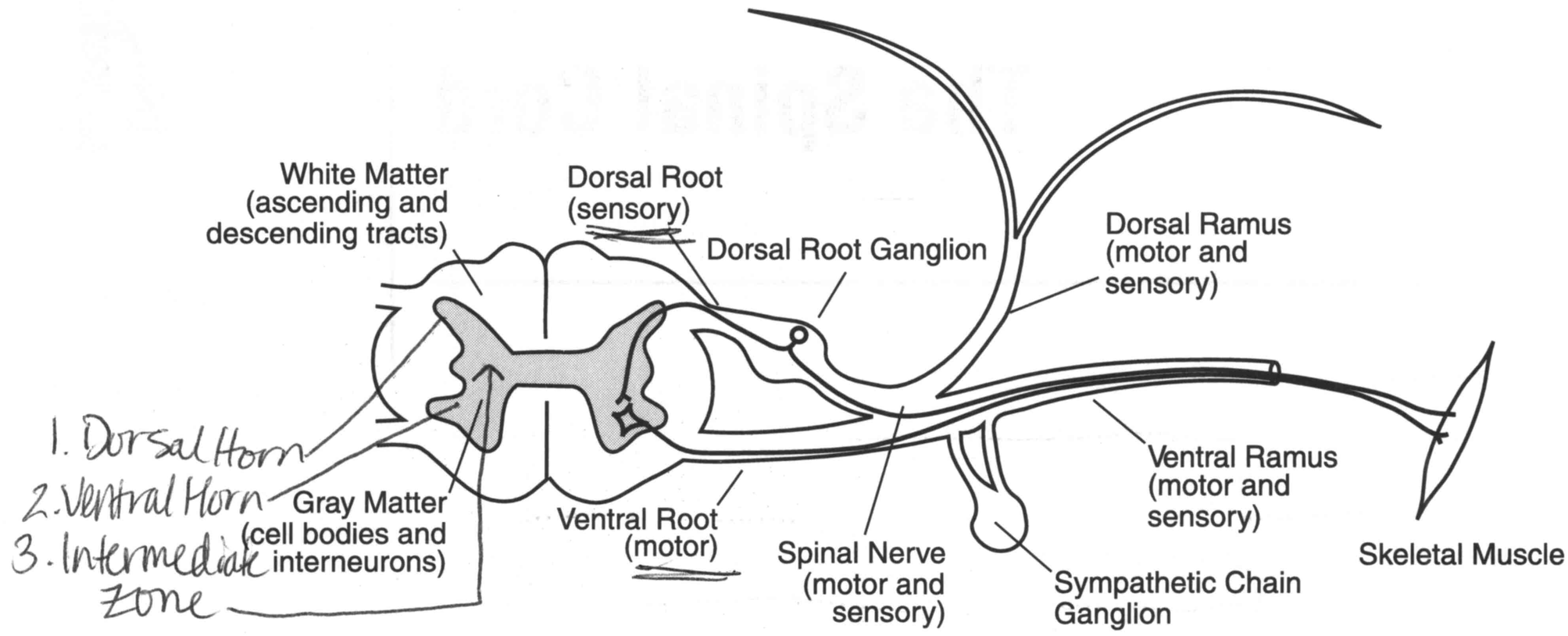

Figure IV-4-1. Cross Section of Spinal Cord and the Components of a Spinal Nerve

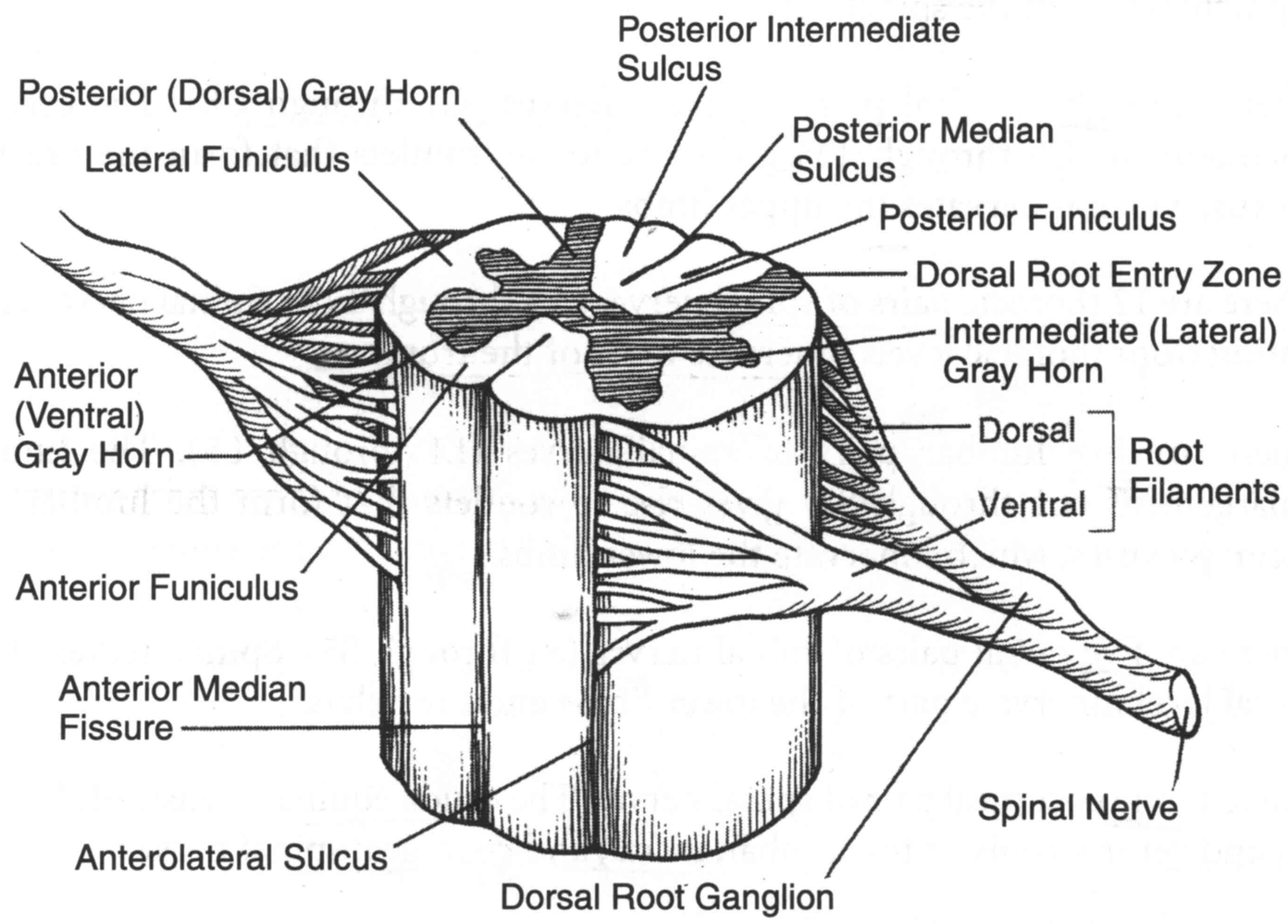

Figure IV-4-2. The Spinal Cord

The gray matter is organized into a dorsal horn, a ventral horn, and an intermediate zone.

Dorsal Horn

The dorsal horn is dominated by neurons that respond to sensory stimulation. All incoming sensory fibers in spinal nerves enter the dorsolateral part of the cord adjacent to the dorsal horn in a dorsal root. Neurons in the dorsal horn project to higher levels of the CNS to carry sensations to the brain stem, cerebral cortex, or cerebellum. Other dorsal horn neurons participate in reflexes.

Ventral Horn

The ventral horn contains alpha and gamma motoneurons. The alpha motoneurons innervate skeletal muscle (extrafusal fibers) by way of a specialized synapse at a neuromuscular junction, and the gamma motoneurons innervate the contractile intrafusal muscle fibers of the muscle spindle. Within the ventral horn, alpha and gamma motoneurons that innervate flexors are dorsal to those that innervate extensors. Alpha and gamma motoneurons that innervate the proximal musculature are medial to those that innervate the distal musculature. Axons of alpha and gamma motoneurons and axons of preganglionic autonomic neurons leave the cord by way of a ventral root.

Intermediate Zone

The intermediate zone of the spinal cord from T1 to L2 contains preganglionic sympathetic neuron cell bodies and Clarke's nucleus, which sends unconscious proprioception to the cerebellum.

NEURAL SYSTEMS

There are three major neural systems in the spinal cord that use neurons in the gray matter and tracts or fasciculi of axons in the white matter. These neural systems have components that can be found at all levels of the CNS from the cerebral cortex to the tip of spinal cord. An understanding of these three neural systems is essential to understanding the effects of lesions in the spinal cord, brain stem, and at higher levels of the CNS.

Motor Systems

Voluntary Innervation of Skeletal Muscle

Upper and Lower Motoneurons

Two motoneurons, an upper motoneuron and a lower motoneuron, together form the basic neural circuit involved in the voluntary contraction of skeletal muscle everywhere in the body. The lower motoneurons are found in the ventral

horn of the spinal cord and in cranial nerve nuclei in the brain stem. Axons of lower motoneurons of spinal nerves exit in a ventral root, then join the spinal nerve to course in one of its branches to reach and synapse directly at a neuromuscular junction in skeletal muscle. Axons of lower motoneurons in the brain stem exit in a cranial nerve.

To initiate a voluntary contraction of skeletal muscle, a lower motoneuron must be innervated by an upper motoneuron (Fig IV-4-3). The cell bodies of upper motoneurons are found in the brain stem and cerebral cortex, and their axons descend into the spinal cord in a tract to reach and synapse on lower motoneurons, or on interneurons, which then synapse on lower motoneurons. At a minimum, therefore, to initiate a voluntary contraction of skeletal muscle, two motoneurons, an upper and a lower, must be involved. The upper motoneuron innervates the lower motoneuron, and the lower motoneuron innervates the skeletal muscle.

The cell bodies of upper motoneurons are found in the red nucleus, reticular formation, and lateral vestibular nuclei of the brain stem, but the most important location of upper motoneurons is in the cerebral cortex. Axons of these cortical neurons course in the corticospinal tract.

Abbreviations

LMN = lower motoneuron
UMN = upper motoneuron

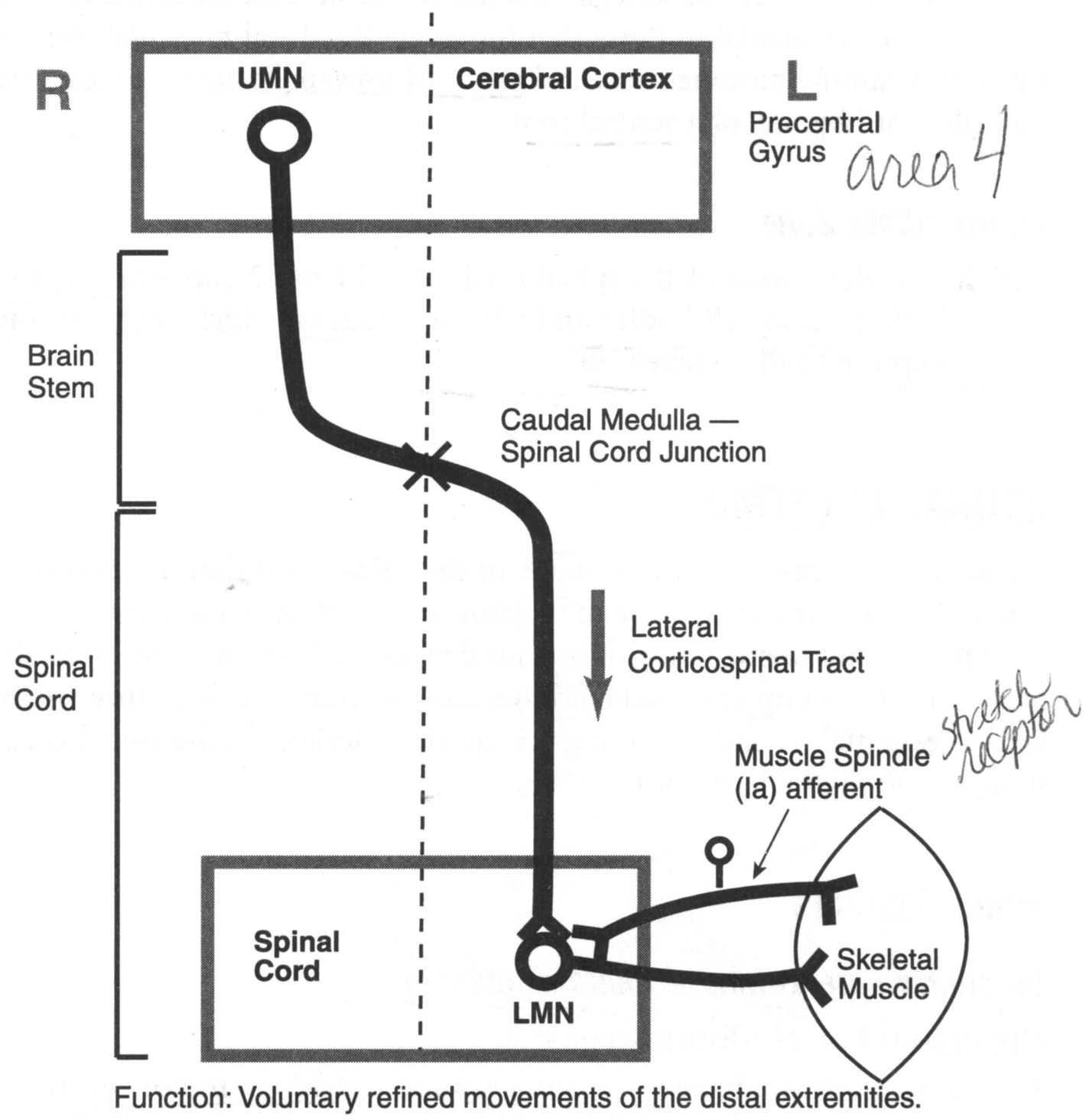

Figure IV-4-3. Corticospinal Tract: Descending Motor Pathway

Corticospinal Tract

The primary motor cortex, located in the precentral gyrus of the frontal lobe, and the premotor area, located immediately anterior to the primary motor cortex, give rise to about 60% of the fibers of the corticospinal tract (Fig IV-4-4). Primary and secondary somatosensory cortical areas located in the parietal lobe give rise to about 40% of the fibers of the corticospinal tract.

Fibers in the corticospinal tract leave the cerebral cortex in the internal capsule, which carries all axons in and out of the cortex. Corticospinal fibers then descend through the length of the brain stem in the ventral portion of the midbrain, pons, and medulla.

In the lower medulla, 80 to 90% of corticospinal fibers cross at the decussation of the pyramids and continue in the contralateral spinal cord as the lateral corticospinal tract. The lateral corticospinal tract descends the full length of the cord in the lateral part of the white matter. As it descends, axons leave the tract and enter the gray matter of the ventral horn to synapse on lower motoneurons.

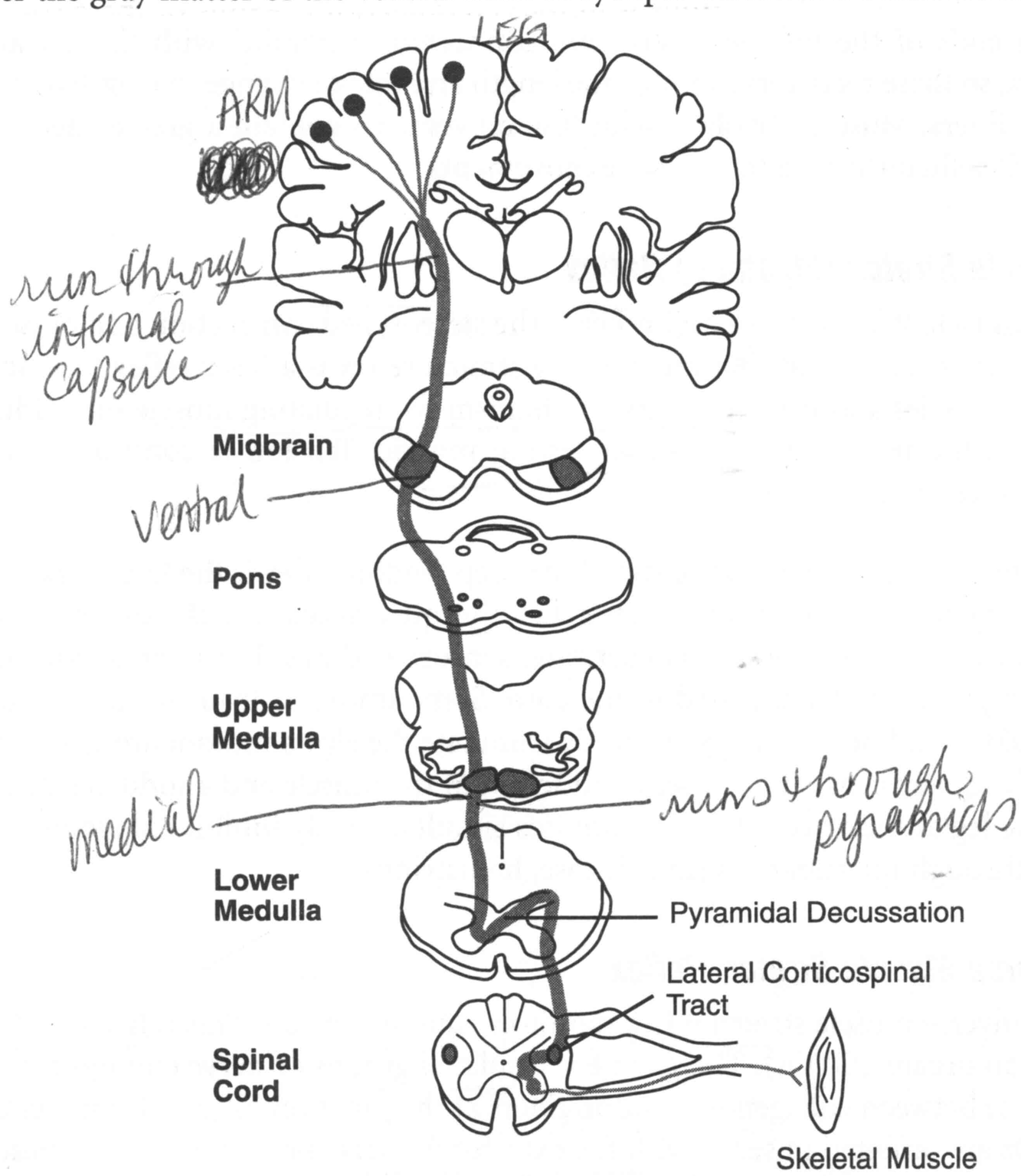

Figure IV-4-4. Corticospinal Tract

Clinical Correlate

Lesions of the Corticospinal Tract

The crossing or decussation of axons of the corticospinal tract at the medulla/spinal cord junction has significant clinical implications. If lesions of the corticospinal tract occur above the pyramidal decussation, a weakness is seen in muscles on the contralateral side of the body; lesions below this level produce an ipsilateral muscle weakness. In contrast to upper motoneurons, the cell bodies of lower motoneurons are ipsilateral to the skeletal muscles that their axons innervate. A lesion to any part of a lower motoneuron will result in an ipsilateral muscle weakness, at the level of the lesion.

Clinical Correlate

Lesions to Ia afferent fibers or lower motoneurons produce areflexia.

Important muscle stretch reflexes to test are:

- knee (L_2 - L_4)
- ankle (S_1)
- biceps (C_5 - C_6)
- triceps (C_7 - C_8)

Reflex Innervation of Skeletal Muscle

A reflex is initiated by a stimulus of a sensory neuron, which in turn innervates a motoneuron and produces a motor response. In reflexes involving skeletal muscles, the sensory stimulus arises from receptors in the muscle, and the motor response is a contraction or relaxation of one or more skeletal muscles. In the spinal cord, lower motoneurons form the specific motor component of skeletal muscle reflexes. Upper motoneurons provide descending control over the reflexes.

Both alpha and gamma motoneurons are lower motoneurons that participate in reflexes. Alpha motoneurons are large cells in the ventral horn that innervate extrafusal muscle fibers. A single alpha motoneuron innervates a group of muscle fibers, which constitutes a motor unit, the basic unit for voluntary, postural, and reflex activity. Gamma motoneurons supply intrafusal muscle fibers, which are modified skeletal muscle fibers. The intrafusal muscle fibers form the muscle spindle, which acts as a sensory receptor in skeletal muscle stretch reflexes.

Both ends of the muscle spindle are connected in parallel with the extrafusal fibers, so these receptors monitor the length and rate of change in length of extrafusal fibers. Muscles involved with fine movements contain a greater density of spindles than those used in coarse movements.

Muscle Stretch (Myotatic) Reflex

The muscle stretch (myotatic) reflex is the stereotyped contraction of a muscle in response to stretch of that muscle. The stretch reflex is a basic reflex that occurs in all muscles and is the primary mechanism for regulating muscle tone. Muscle tone is the tension present in all resting muscle. Tension is controlled by the stretch reflexes.

The best example of a muscle stretch or deep tendon reflex is the knee-jerk reflex. Tapping the patellar ligament stretches the quadriceps muscle and its muscle spindles. Stretch of the spindles activates sensory endings (Ia afferents), and afferent impulses are transmitted to the cord. Some impulses from stretch receptors carried by Ia fibers monosynaptically stimulate the alpha motoneurons that supply the quadriceps. This causes contraction of the muscle and a sudden extension of the leg at the knee. Afferent impulses simultaneously inhibit antagonist muscles through interneurons (in this case, hamstrings).

Inverse Muscle Stretch Reflex

The inverse muscle stretch reflex monitors muscle tension. This reflex uses Golgi tendon organs (GTOs). These are encapsulated groups of nerve endings that terminate between collagenous tendon fibers at the junction of muscle and tendon. GTOs are oriented in series with the extrafusal fibers and respond to increases in force or tension generated in that muscle. Increases in force in a muscle increase the firing rate of Ib afferent neurons that innervate the GTOs, which, in turn, polysynaptically facilitate antagonists and inhibit agonist muscles.

Muscle tone and reflex activity can be influenced by gamma motoneurons and by upper motoneurons. Gamma motoneurons directly innervate the muscle spindles and regulate their sensitivity to stretch. Upper motoneurons innervate gamma motoneurons and also influence the sensitivity of muscle spindles to stretch. Stimulation of gamma motoneurons causes intrafusal muscle fibers located at the pole of each muscle spindle to contract, which activates alpha motoneurons, causing an increase in muscle tone.

Flexor Withdrawal Reflex

The flexion withdrawal reflex is a protective reflex in which a stimulus (usually painful) causes withdrawal of the stimulated limb. This reflex may be accompanied by a crossed extension reflex in which the contralateral limb is extended to help support the body.

Clinical Correlate

Upper Motoneuron Versus Lower Motoneuron Muscle Lesions

A fundamental requirement of interpreting the cause of motor weakness in neuroscience cases is the ability to distinguish between a lesion of an upper versus a lower motoneuron. Because a lesion to either an upper or a lower motoneuron produces a weakness in the ability to voluntarily contract skeletal muscles, the key to distinguishing an upper from a lower motoneuron lesion will be the condition of reflexes of the affected muscles (Fig IV-4-5).

A lesion of any part of a lower motoneuron will result in hypoactive muscle stretch reflexes and a reduction in muscle tone (hypotonicity) because lower motoneurons form the motor component of the reflex. Therefore, lower motoneuron lesions result in a paresis combined with suppressed or absent muscle stretch reflexes. An early sign of a lower motoneuron lesion is muscle fasciculations, which are twitches or contractions of groups of muscle fibers, that may produce a movement visible on the skin. Later, lower motoneuron lesions produce fibrillations, which are invisible 1- to 5-ms potentials, detected with electromyography. Muscles denervated by a lower motoneuron lesion undergo pronounced wasting or atrophy. The constellation of lower motoneuron lesion signs combining paresis with suppressed or absent reflexes, fasciculations, and atrophy is known as a **flaccid paralysis**. With few exceptions, lower motoneuron (LMN) lesions produce a flaccid paralysis ipsilateral and at the level of the lesion.

almost always ipsilateral

Neurologically, upper motoneurons including the corticospinal tract have a net overall inhibitory effect on muscle stretch reflexes. As a result, upper motoneuron lesions combine paresis of skeletal muscles with muscle stretch or deep tendon reflexes that are hyperactive or hypertonic. The hypertonia may be seen as decorticate rigidity (i.e., postural flexion of the arm and extension of the leg) or decerebrate rigidity (i.e., postural extension of the arm and leg) depending on the location of the lesion. Lesions above the midbrain produce decorticate rigidity; lesions below the midbrain produce decerebrate rigidity. Upper motoneuron lesions result in atrophy of weakened muscles only as a result of disuse, because these muscles can still be contracted by stimulating muscle stretch reflexes.

Babinski sign

(continued next page)

Clinical Correlate *(continued)*

Upper motoneuron lesions are also accompanied by reversal of cutaneous reflexes, which normally yield a flexor motor response. The best known of the altered flexor reflexes is the **Babinski reflex.** The test for the Babinski reflex is performed by stroking the lateral surface of the sole of the foot with a slightly painful stimulus. Normally, there is plantar flexion of the big toe. With a lesion of the corticospinal tract, the Babinski reflex is present, which is characterized by extension of the great toe and fanning of the other toes. Two other flexor reflexes, the abdominal and cremasteric, are also lost in upper motoneuron lesions. The constellation of upper motoneuron lesion signs combining paresis with increases or hyperactive reflexes, disuse atrophy of skeletal muscles, and altered cutaneous reflexes is known as a spastic paresis.

In contrast to lower motoneuron lesions, lesions of upper motoneurons result in a **spastic paresis** that is ipsilateral or contralateral and below the site of the lesion. Upper motoneuron lesions anywhere in the spinal cord will result in an ipsilateral spastic paresis below the level of the lesion. Upper motoneuron lesions between the cerebral cortex and the medulla above the decussation of the pyramids will result in a contralateral spastic paresis below the level of the lesion.

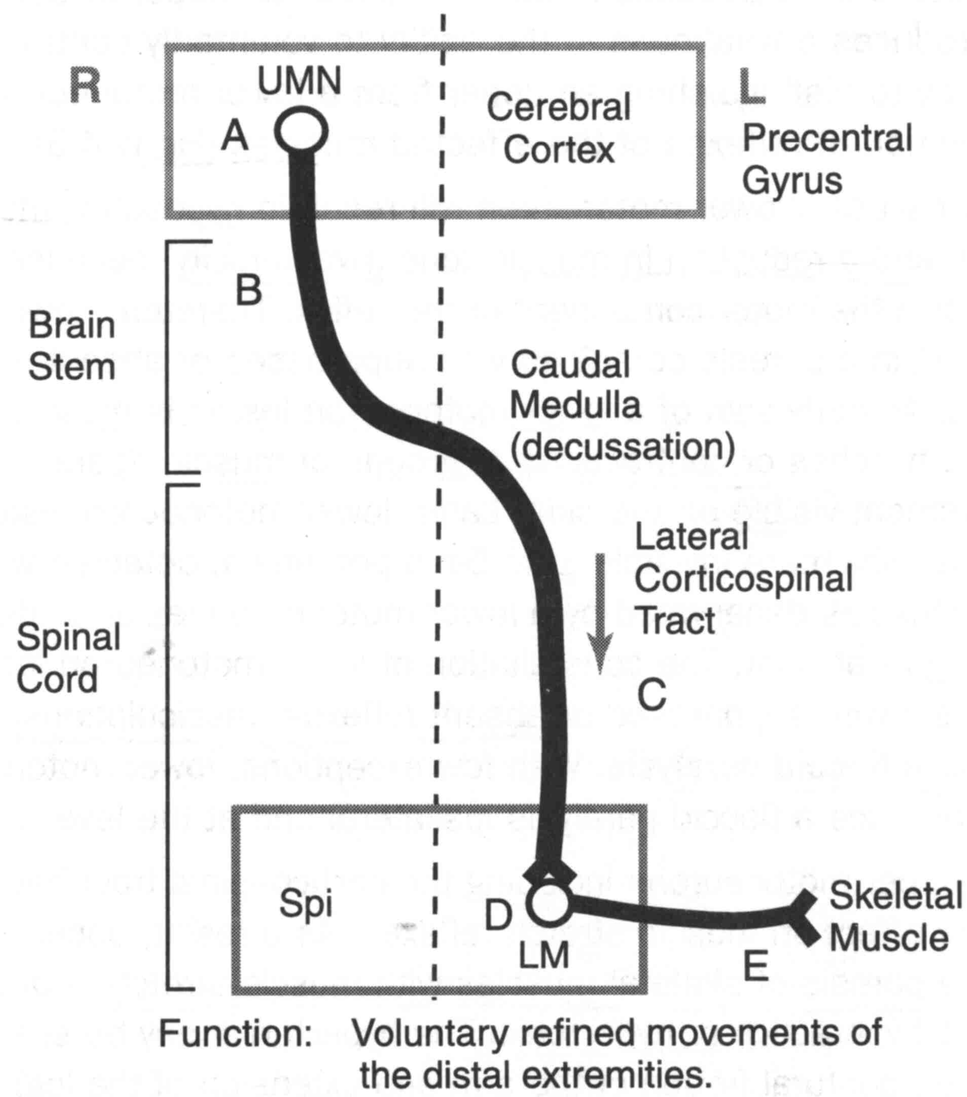

Figure IV-4-5. Upper versus Lower Motoneuron Lesions

Table IV-4-1. Upper versus Lower Motoneuron Lesions

Upper Motor Neuron Lesion	Lower Motor Neuron Lesion
Spastic paralysis	Flaccid paralysis
Hyperreflexia	Areflexia
Babinski sign present	No Babinski
Increased muscle tone	Fasiculations
Muscle weakness	Decreased muscle tone
Disuse atrophy of muscles	Atrophy of muscle(s)
Decreased speed of voluntary movements	Loss of voluntary movements
Large area of the body involved	Small area of body affected

Sensory Systems

Two sensory systems, the dorsal column–medial lemniscal system and the anterolateral (spinothalamic) system, use three neurons to convey sensory information from peripheral sensory receptors to conscious levels of cerebral cortex. In both systems, the first sensory neuron that innervates a sensory receptor has a cell body in the dorsal root ganglion and carries the information into the spinal cord in the dorsal root of a spinal nerve. The first neuron synapses with a second neuron in the brain stem or the spinal cord, and the axon of the second neuron crosses the midline and is carried in a tract in the CNS. The axon of the second neuron then synapses on a third neuron that is in the thalamus. The axon of the third neuron projects to primary somatosensory cortex (Fig IV-4-6).

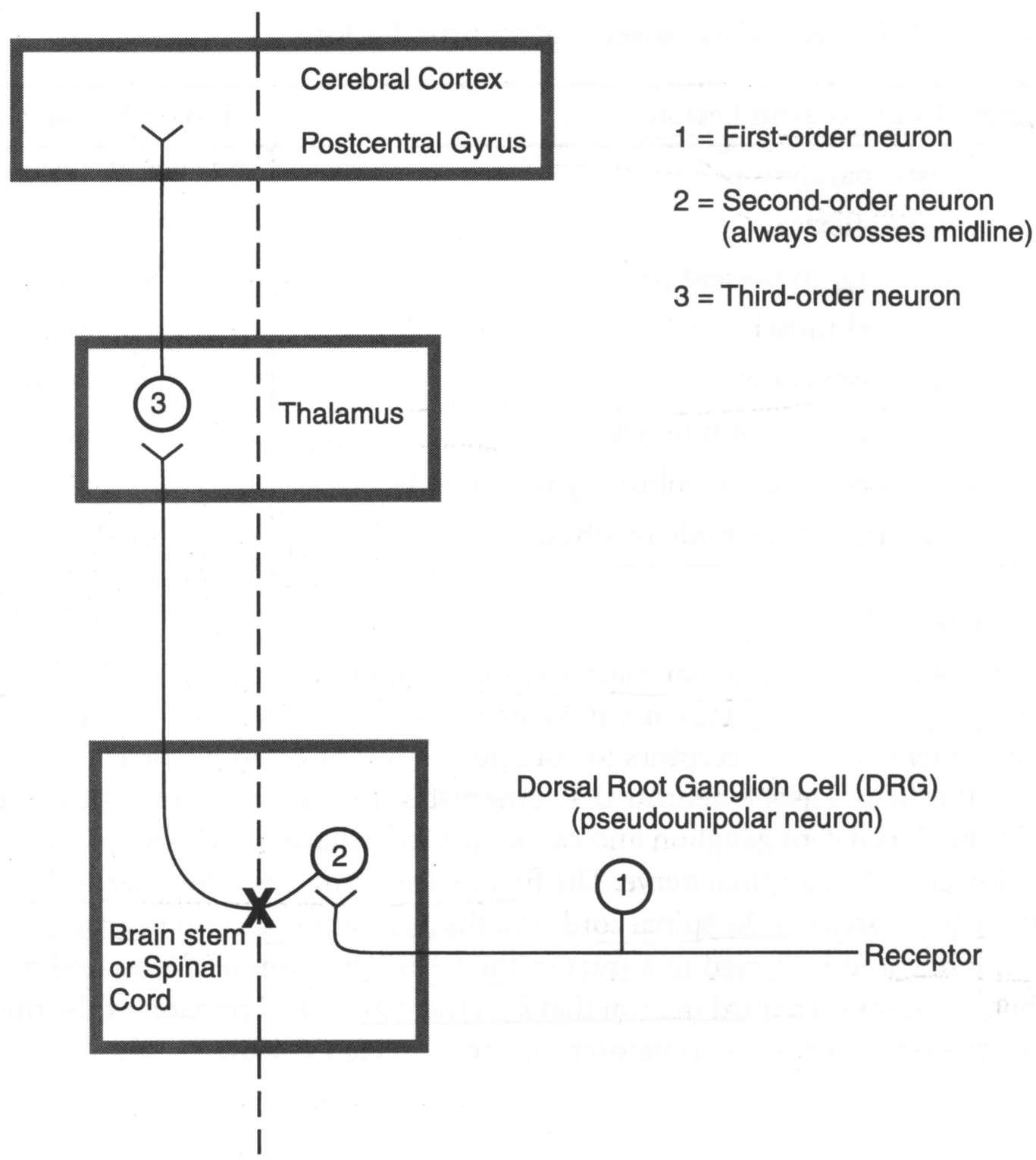

Figure IV-4-6. General Sensory Pathways

Dorsal Column–Medial Lemniscal System

The dorsal column–medial lemniscal system carries sensory information for discriminative touch, joint position (kinesthetic or conscious proprioceptive) sense, vibratory, and pressure sensations from the trunk and limbs (Fig IV-4-7). The primary afferent neurons in this system have their cell bodies in the dorsal root ganglia, enter the cord via class II or A-beta dorsal root fibers, and then coalesce in the fasciculus gracilis or fasciculus cuneatus in the dorsal funiculus of the spinal cord. The fasciculus gracilis, found at all spinal cord levels, is situated closest to the midline and carries input from the lower extremities and lower trunk. The fasciculus cuneatus, found only at upper thoracic and cervical spinal cord levels, is lateral to the fasciculus gracilis and carries input from the upper extremities and upper trunk. These two fasciculi form the dorsal columns of the spinal cord that carry the central processes of dorsal root ganglion cells and ascend the length of the spinal cord to reach their second neurons in the lower part of the medulla.

In the lower part of the medulla, fibers in the fasciculus gracilis and fasciculus cuneatus synapse with the second neurons found in the nucleus gracilis and nucleus cuneatus, respectively. Cells in these medullary nuclei give rise to fibers that cross the midline as internal arcuate fibers and ascend through the brain stem in the medial lemniscus. Fibers of the medial lemniscus terminate on cells of the ventral posterolateral (VPL) nucleus of the thalamus. From the VPL nucleus, thalamocortical fibers project to the primary somesthetic (somatosensory) area of the postcentral gyrus, located in the most anterior portion of the parietal lobe.

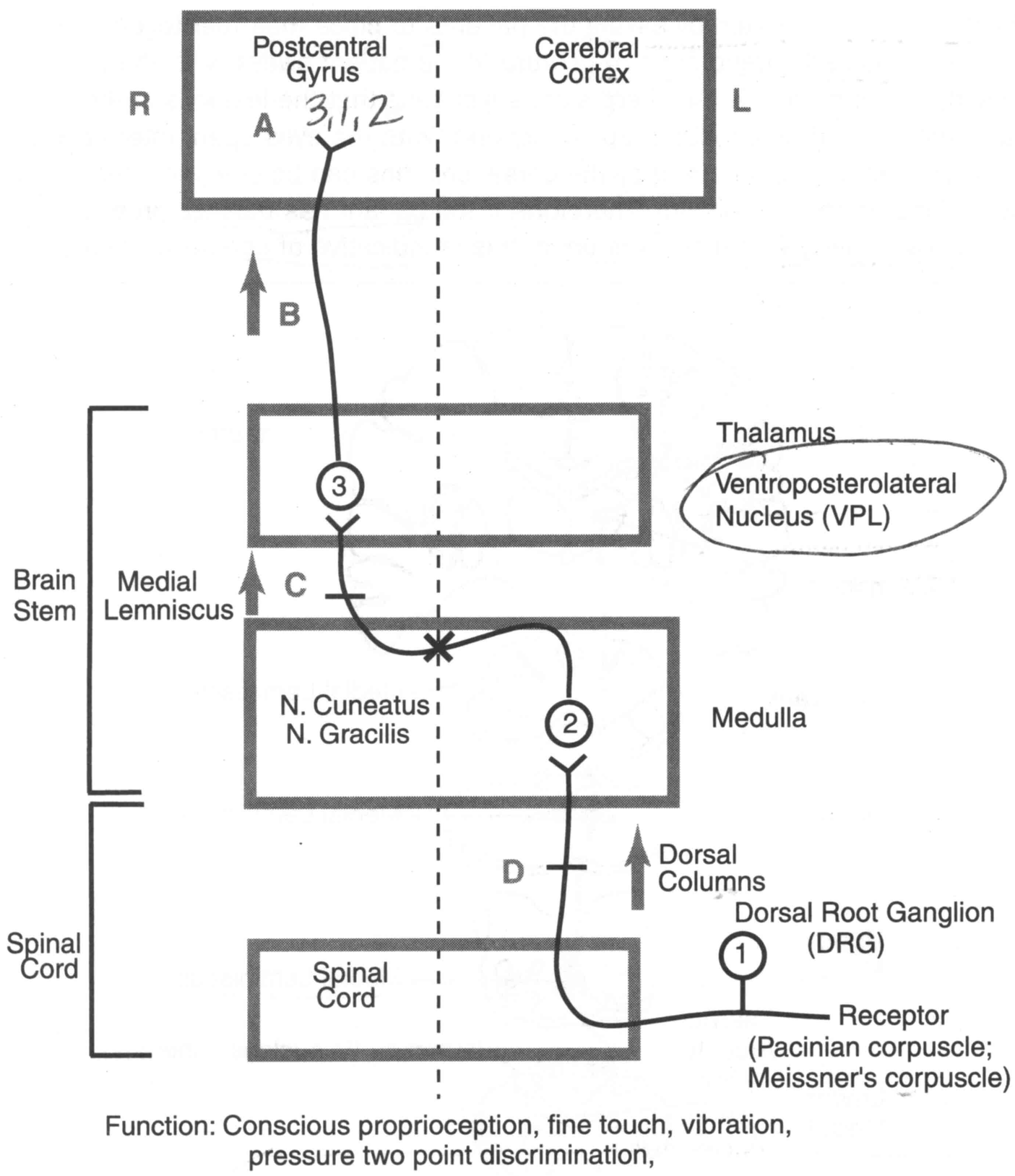

Function: Conscious proprioception, fine touch, vibration, pressure two point discrimination,

Lesion: loss of above senses
Site of lesion: affected side of body
A, B, and **C**: contralateral
D: Ipsilateral

Figure IV-4-7. Dorsal Column Pathway—Medial Lemniscal System

contralat. defect in brainstem & spinal cord
Ipsilateral in brain stem

Clinical Correlate

Lesions of the dorsal columns result in a loss of joint position sensation, vibratory and pressure sensations, and two-point discrimination. There is loss of the ability to identify the characteristics of an object, called astereognosis (e.g., size, consistency, form, shape), using only the sense of touch. Typically, dorsal column–medial lemniscal lesions are evaluated by testing vibratory sense using a 128-Hz tuning fork. Romberg's sign is also used to distinguish between lesions of the dorsal columns and the midline (vermal area) of the cerebellum.

Romberg's sign is tested by asking the patients to place their feet together. If there is a marked deterioration of posture (if the patient sways) with the eyes closed, this is a positive Romberg sign, suggesting that the lesion is in the dorsal columns (or dorsal roots of spinal nerves). With the eyes open, interruption of proprioceptive input carried by the dorsal columns can be compensated for by visual input to the cerebellum. Therefore, if the patient has balance problems and tends to sway with their eyes open, this is indicative of cerebellar damage.

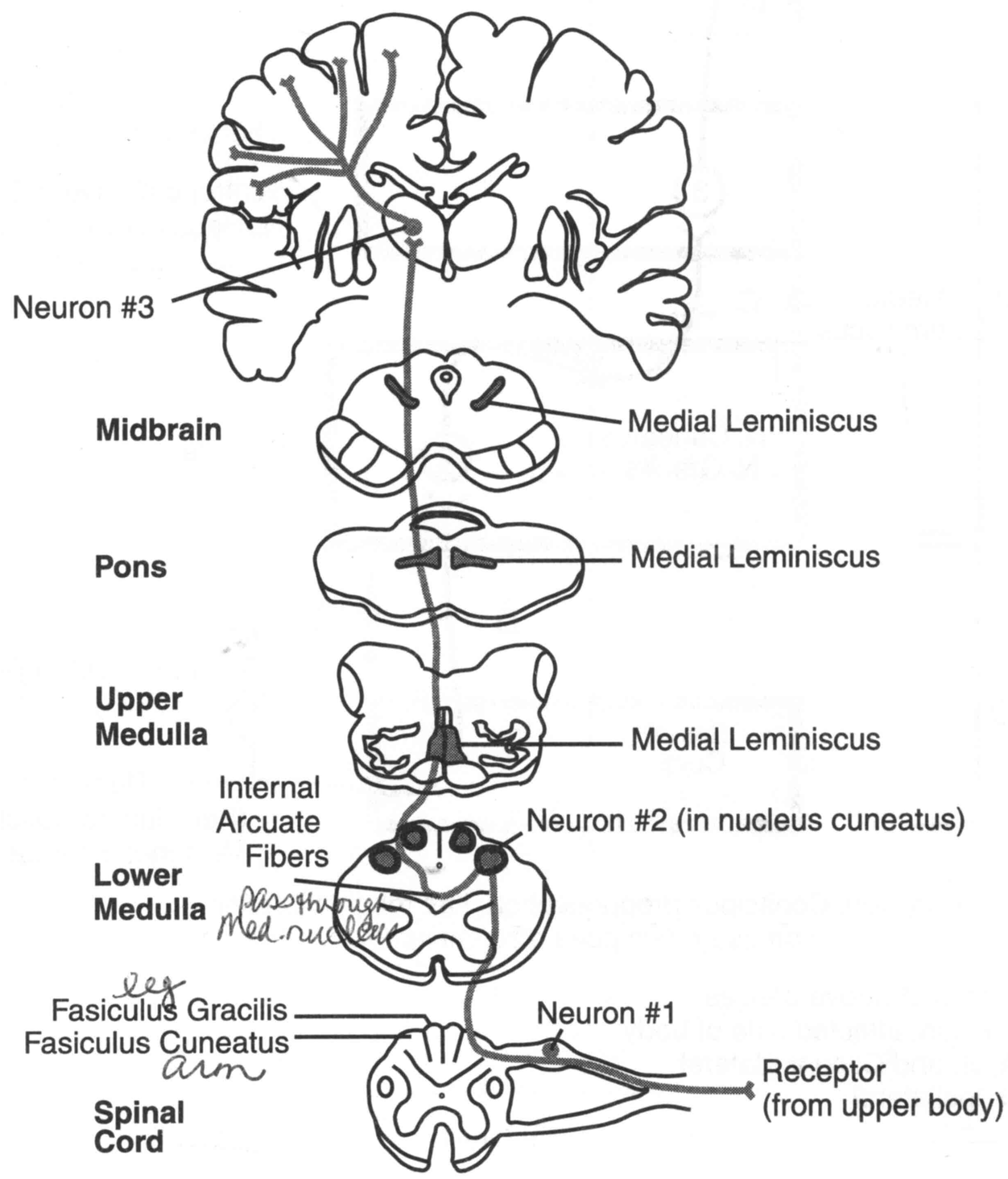

Figure IV-4-8. Dorsal Column Pathway—Medial Lemniscal Pathway

Anterolateral (Spinothalamic Tract) System

The anterolateral system carries pain, temperature, and crude touch sensations from the extremities and trunk.

Pain and temperature fibers have cell bodies in the dorsal root ganglia and enter the spinal cord via A-delta and C or class III and class IV dorsal root fibers (Fig IV-4-9). Their fibers ascend or descend a couple of segments in the dorsolateral tract of Lissauer before entering and synapsing in the dorsal horn. The second neuron cell bodies are located in the dorsal horn gray matter. Axons from these cells cross in the ventral white commissure just below the central canal of the spinal cord and coalesce to form the spinothalamic tract in the ventral part of the lateral funiculus. The spinothalamic tract courses through the entire length of the spinal cord and the brain stem to terminate in the VPL nucleus of the thalamus. Cells in the VPL nucleus send pain and temperature information to the primary somatosensory cortex in the postcentral gyrus.

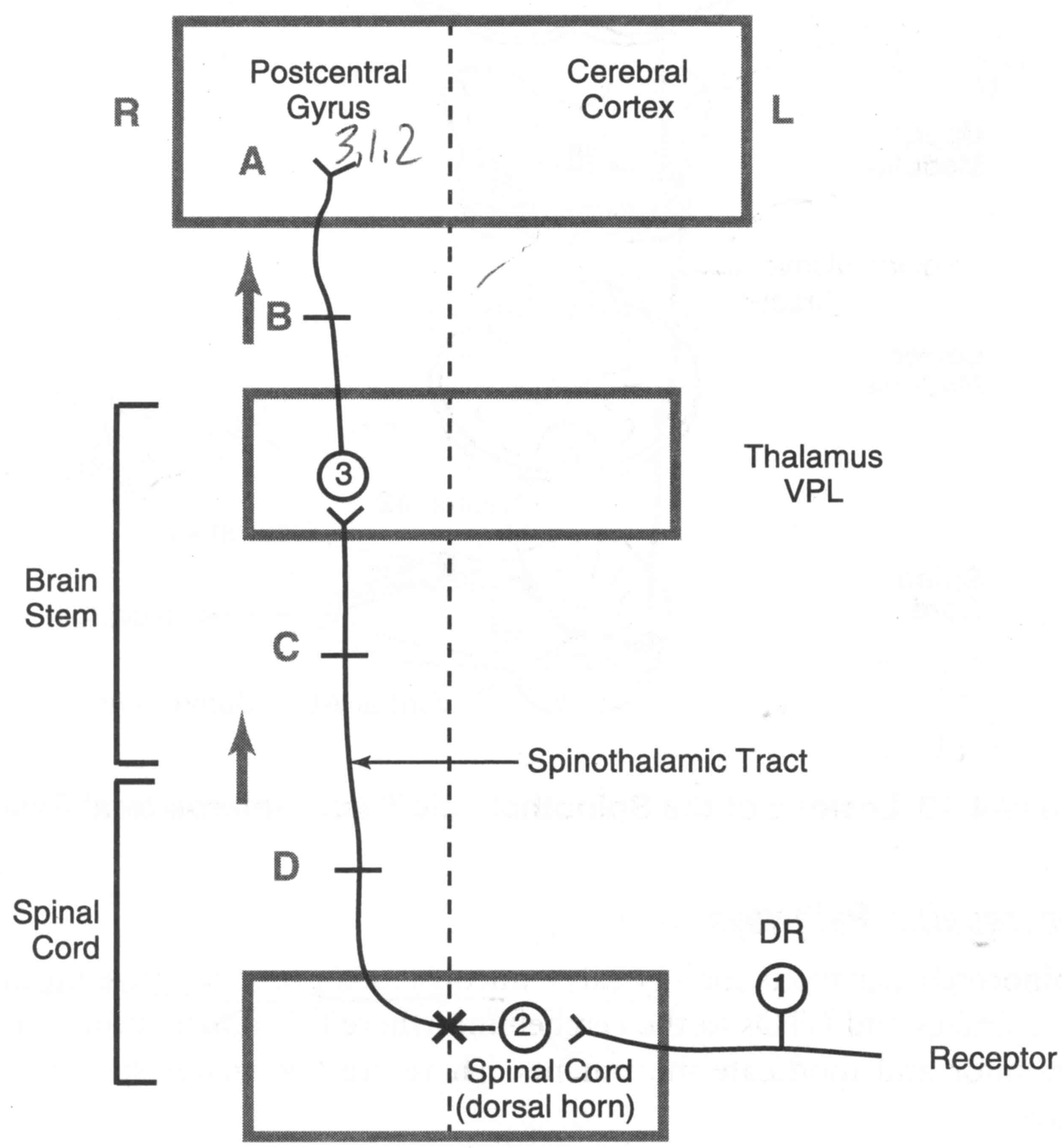

Function: pain and temperature.

Lesion: anesthesia (loss of pain and temperature sensations)
Site of lesion: affected side of body
A, B, C, D: contralateral below the lesion; tract intact rostral to the lesion

Figure IV-4-9. Spinothalamic Tract (Anterolateral System)

↳ already a crossed tract
contralat. deficit w/ lesion in spinal cord

Clinical Correlate

Because the pain and temperature information crosses almost as soon as it enters the spinal cord, any unilateral **lesion of the spinothalamic tract** in the spinal cord or brain stem will result in a contralateral loss of pain and temperature. This is an extremely useful clinical sign because it means that if a patient presents with analgesia on one side of the trunk or limbs, the location of the lesion must be on the contralateral side of the spinal cord or brain stem. The analgesia begins 1 to 2 segments below the lesion and includes everything below that level (Fig IV-4-10).

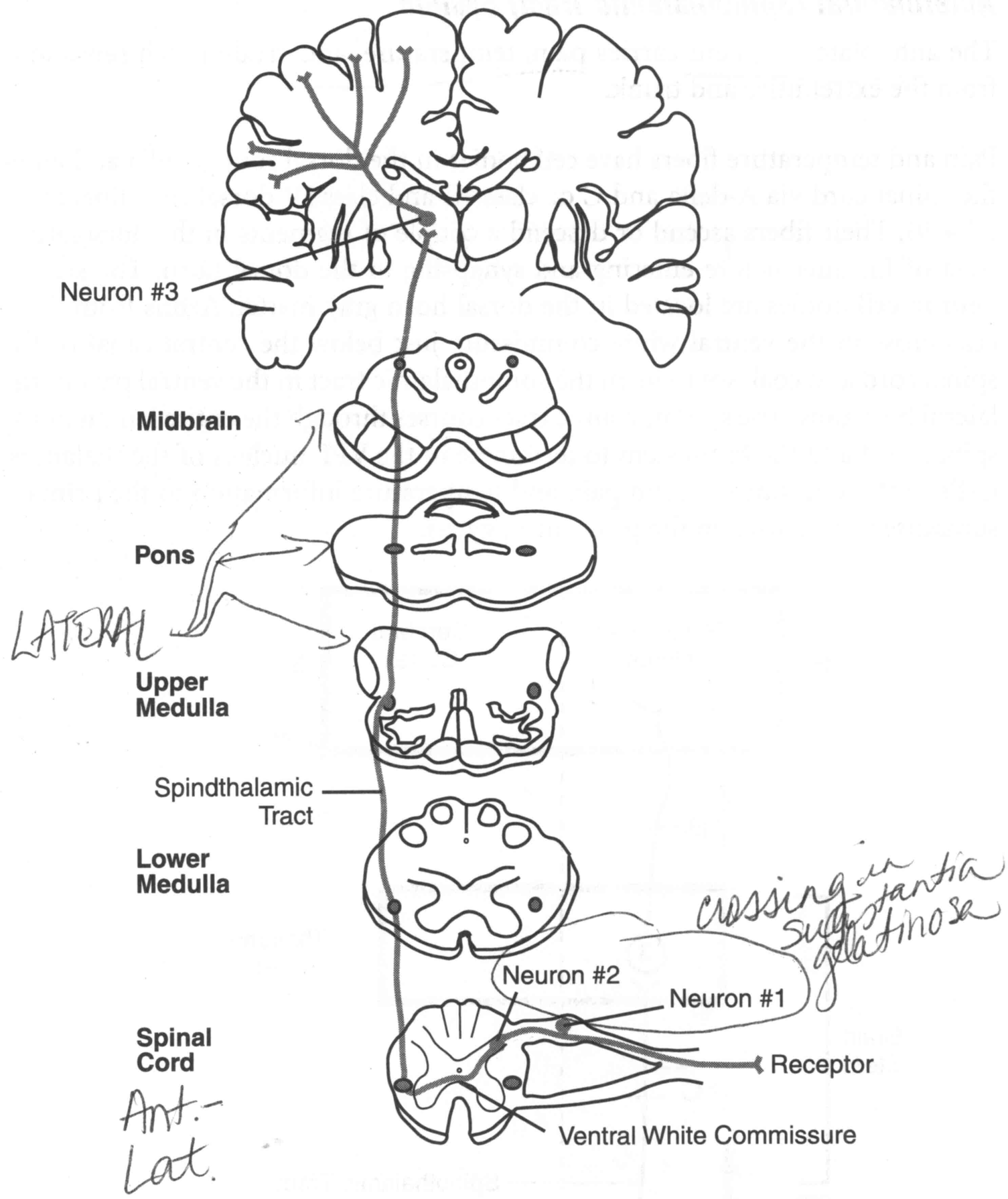

Figure IV-4-10. Lesions of the Spinothalamic Tract (Anterolateral System)

Spinocerebellar Pathways

The spinocerebellar tracts mainly carry unconscious proprioceptive input from muscle spindles and GTOs to the cerebellum, where this information is used to help monitor and modulate movements. There are two major spinocerebellar pathways:

- Dorsal spinocerebellar tract—carries input from the lower extremities and lower trunk.
- Cuneocerebellar tract—carries proprioceptive input to the cerebellum from the upper extremities and upper trunk.

The cell bodies of the dorsal spinocerebellar tract are found in Clarke's nucleus, which is situated in the spinal cord from T1 to L2. The cell bodies of the cuneocerebellar tract are found in the medulla in the external cuneate nucleus (Fig IV-4-11).

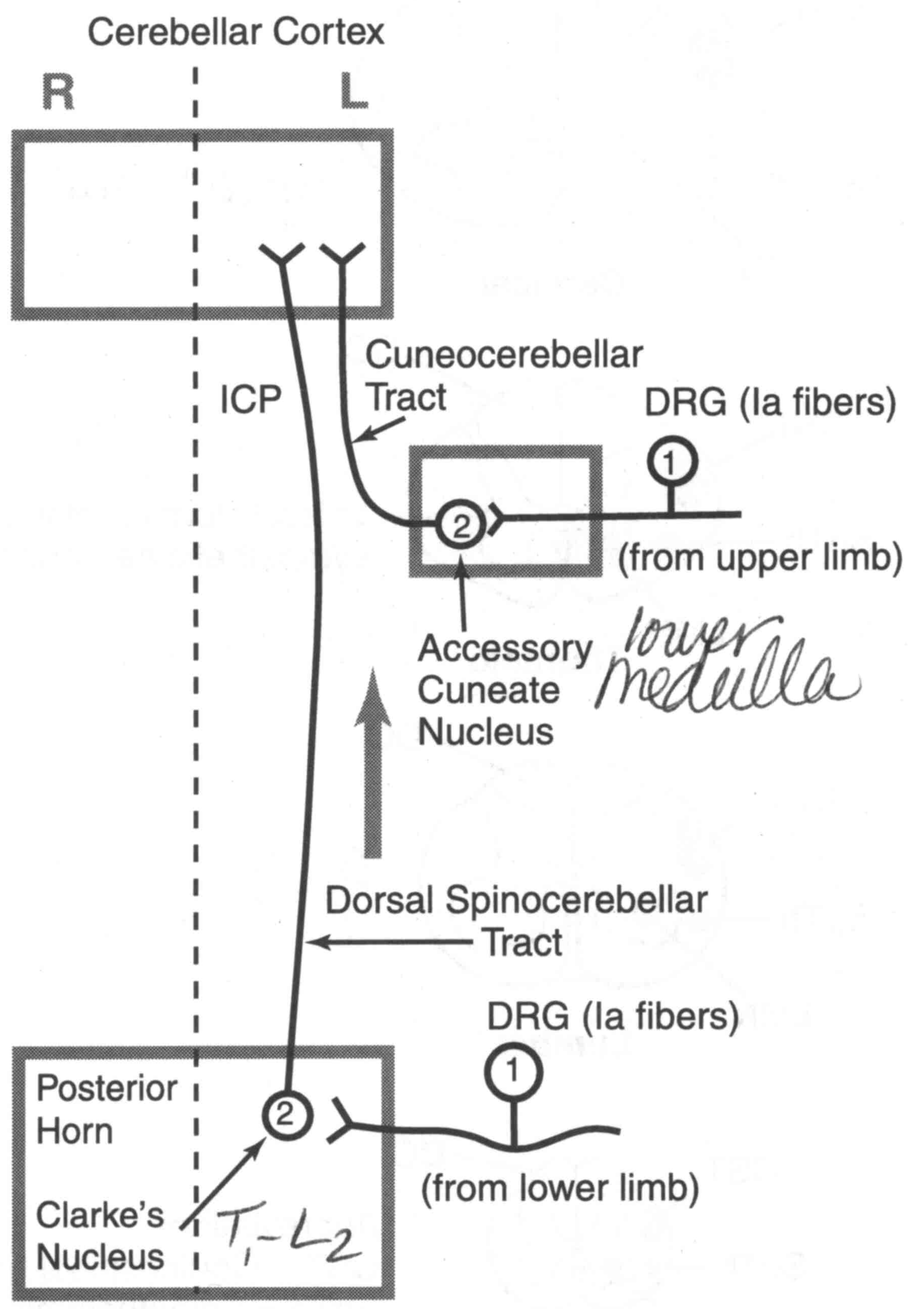

ICP = Inferior Cerebellar Peduncle
SCP = Superior Cerebellar Peduncle

Figure IV-4-11. Spinocerebellar Tracts: Unconscious Proprioception

Clinical Correlate

Lesions that affect only the spinocerebellar tracts are uncommon, but there are a group of hereditary diseases in which degeneration of spinocerebellar pathways is a prominent feature. The most common of these is Friedreich's ataxia, which is usually inherited as an autosomal recessive trait. The spinocerebellar tracts, dorsal columns, corticospinal tracts, and cerebellum may be involved. Ataxia of gait is the most common initial symptom of this disease.

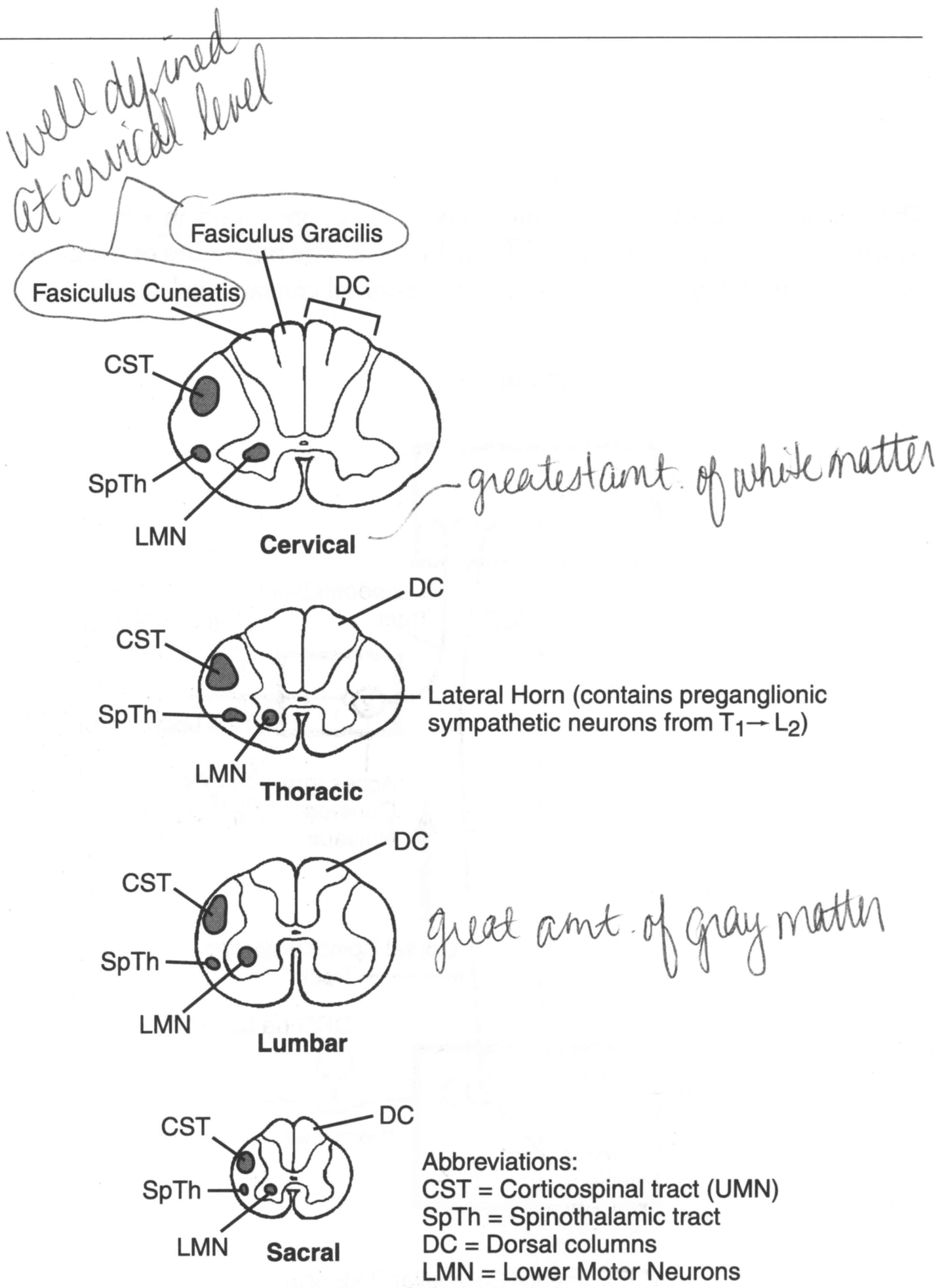

Figure IV-4-12. Spinal Cord: Levels

Spinal Cord Lesions

Figure IV-4-13 provides an overview of the spinal cord tracts, and Figures IV-4-14 and IV-4-15 show lesions at different sites, which are discussed below.

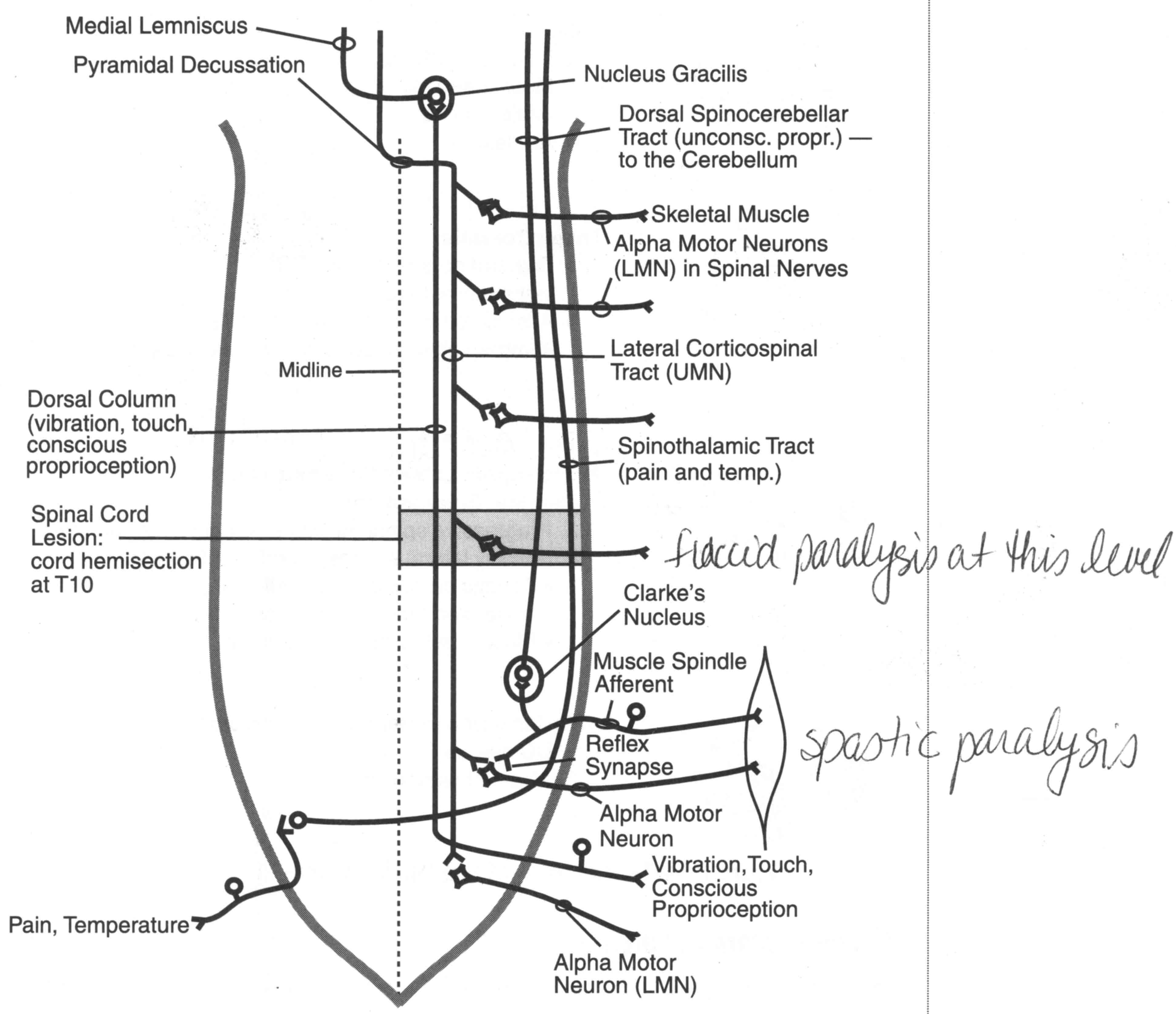

Figure IV-4-13. An Overview of the Spinal Cord Pathways

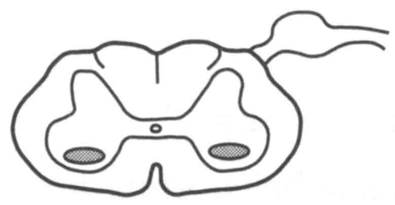

LMN

Polio

a. Flaccid paralysis
b. Muscle atrophy
c. Fasiculations
d. Areflexive

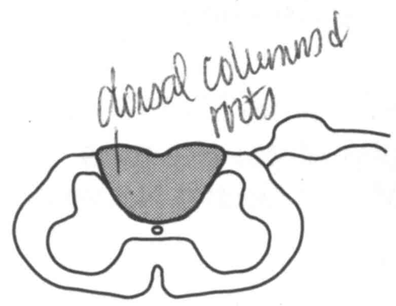

associated w/ late stages of syphilis

Tabes Dorsalis

a. Bilateral dorsal column (DC) signs below lesions
b. Associated with late-stage syphilis
+ Romberg sign: sways with eyes closed

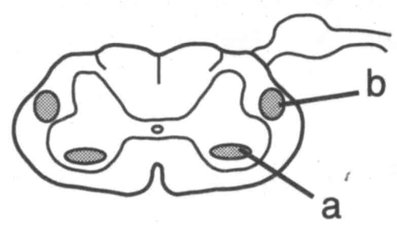

motor disorder LMN, UMN

Amyotrophic Lateral Sclerosis (ALS) at Cervical Enlargement

a. Progressive spinal muscular atrophy (ventral horn)
b. Primary lateral sclerosis (corticospinal tract)
   - Spastic paralysis in lower limbs
   - Increased tone and reflexes
   - Flaccid paralysis in upper limbs

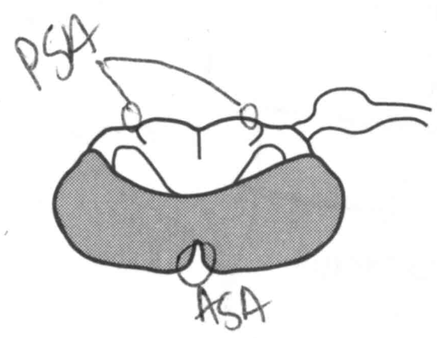

Anterior Spinal Artery (ASA) Occlusion

a. DC spared
b. All else bilateral signs

Figure IV-4-14. Lesions of the Spinal Cord—1

Brown-Séquard Syndrome

Brown-Séquard syndrome results from a hemisection of the cord along the transverse plane. Hemisection of the cord results in a lesion of each of the three main neural systems: the principal upper motoneuron pathway of the corticospinal tract, one or both dorsal columns, and the spinothalamic tract. The hallmark of a lesion to these three long tracts is that the patient presents with two ipsilateral signs and one contralateral sign. Lesion of the corticospinal tract results in an ipsilateral spastic paresis below the level of the injury. Lesion to the fasciculus gracilis or cuneatus results in an ipsilateral loss of joint position sense, tactile discrimination, and vibratory sensations below the lesion. Lesion of the spinothalamic tract results in a contralateral loss of pain and temperature sensation starting one or two segments below the level of the lesion. At the level of the lesion, there will be an ipsilateral loss of all sensation, including touch modalities as well and pain and temperature, and an ipsilateral flaccid paralysis in muscles supplied by the injured spinal cord segments (Fig IV-4-15).

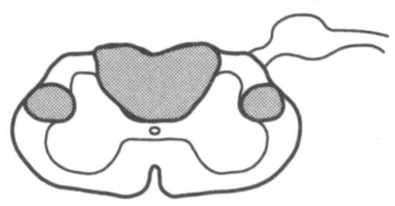

Subacute Combined Degeneration

a. Vitamin B_{12}, pernicious anemia; (AIDS)
b. Demyelination of the
- Dorsal columns ataxia
- Spinocerebellar tracts
- Corticospinal tracts (CST) spastic paralysis

Spinothalamic tract

Syringomyelia

a. Cavitation of the cord; usually cervical
b. Bilateral loss of pain and temperature at the level of the lesion

Spinal Cord

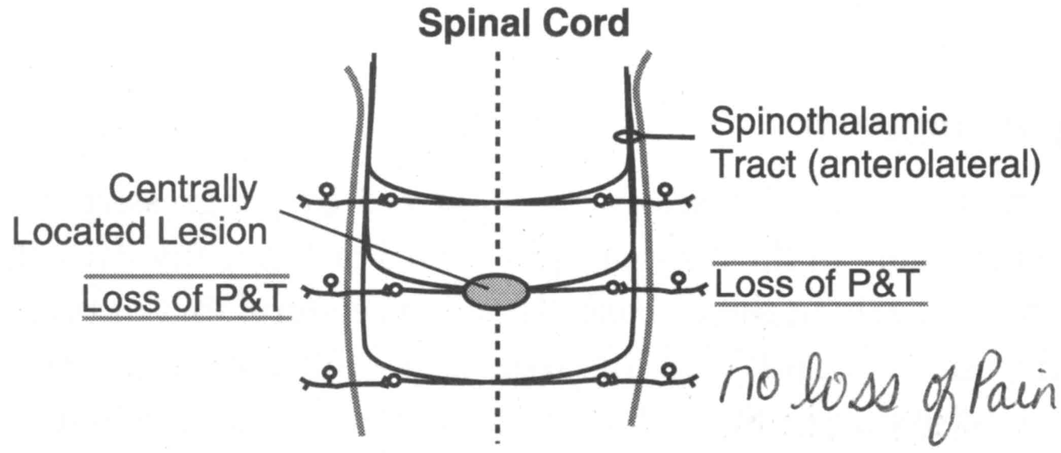

no loss of Pain & temp. below the lesion

c. As the disease progresses, there is muscle weakness: eventually flaccid paralysis and atrophy of the upper limb muscles, due to destruction of ventral horn cells

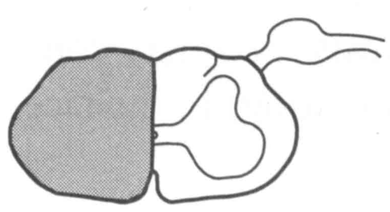

Hemisection: Brown-Séquard Syndrome

a. DC: ipsilateral loss of position and vibratory senses at and below level of the lesion
b. Spinothalamic tract: contralateral loss of P&T below lesion and bilateral loss at the level of the lesion
c. CST: ipsilateral paresis below the level of the lesion
d. LMN: Flaccid paralysis at the level of the lesion
e. Descending hypothalamics: ipsilateral Horner s Syndrome (if cord lesion above T2)
- Facial hemianhydrosis
- Ptosis (slight)
- Miosis

Figure IV-4-15. Lesions of the Spinal Cord—2

Poliomyelitis

Poliomyelitis results from a relatively selective destruction of lower motoneurons in the ventral horn by the poliovirus. The disease causes a flaccid paralysis of muscles with the accompanying hyporeflexia and hypotonicity. Some patients may recover most function, whereas others progress to muscle atrophy and permanent disability (Fig IV-4-14).

Amyotrophic Lateral Sclerosis

Amyotrophic lateral sclerosis (ALS, Lou Gehrig's disease) is a relatively pure motor system disease that affects both upper and lower motoneurons. The disease typically begins at cervical levels of the cord and progresses either up or down the cord. Patients present with bilateral flaccid weakness of the upper limbs

and bilateral spastic weakness of the lower limbs. Lower motoneurons in the brain stem nuclei may be involved later (Fig IV-4-14).

Occlusion of the Anterior Spinal Artery

This artery lies in the anterior median sulcus of the spinal cord. Occlusion of the anterior spinal artery interrupts blood supply to the ventrolateral parts of the cord, including the corticospinal tracts and spinothalamic tracts. Below the level of the lesion, the patient exhibits a bilateral spastic paresis and a bilateral loss of pain and temperature (Fig IV-4-14).

Clinical Correlate

Syringomyelia may present with hydrocephalus and Arnold Chiari (I) malformation.

Syringomyelia

Syringomyelia is a disease characterized by progressive cavitation of the central canal, usually in the cervical spinal cord but may involve other cord regions or the medulla. Early in the disease, there is a bilateral loss of pain and temperature sensation in the hands and forearms as a result of the destruction of spinothalamic fibers crossing in the anterior white commissure. When the cavitation expands, lower motoneurons in the ventral horns are compressed, resulting in bilateral flaccid paralysis of upper limb muscles. A late manifestation of cavitation is **Horner's syndrome**, which occurs as a result of involvement of descending hypothalamic fibers innervating preganglionic sympathetic neurons in the T1 through T4 cord segments. Horner's syndrome consists of miosis (pupillary constriction), ptosis (drooping eyelids), and anhidrosis (lack of sweating) in the face (Fig IV-4-15).

Clinical Correlate

Tabes patients present with paresthesias (pins and needles sensations), pain, polyuria, Romberg sign.

Tabes Dorsalis

Tabes dorsalis is one possible manifestation of neurosyphilis. It is caused by bilateral degeneration of the dorsal roots and secondary degeneration of the dorsal columns. There may be impaired vibration and position sense, astereognosis, paroxysmal pains, and ataxia, as well as diminished stretch reflexes or incontinence. Owing to the loss of proprioceptive pathways, individuals with tabes dorsalis are unsure of where the ground is and walk with a characteristic and almost diagnostic "high step stride" (Fig IV-4-14). Tabetic patients may also present with abnormal pupillary responses (Argyll Robertson pupils).

Clinical Correlate

Subacute combined degeneration patients present paresthesias bilateral spastic weakness, Babinski signs, and antibodies to instrinsic factor.

Subacute Combined Degeneration

Subacute combined degeneration is seen most commonly in cases of vitamin B_{12} deficiency, sometimes related to pernicious anemia. The disease is characterized by patchy losses of myelin in the dorsal columns and lateral corticospinal tracts, resulting in a bilateral spastic paresis and a bilateral alteration of touch, vibration, and pressure sensations below the lesion sites (Fig IV-4-15). Myelin in both CNS and PNS is affected.

Multiple Sclerosis

Multiple sclerosis is a demyelinating disease of the CNS in which certain myelinated pathways, such as the optic nerve, dorsal columns, corticospinal tract, and medial longitudinal fasciculus (MLF) are affected. The illness is characterized by episodes of focal neurologic deficits that are separated in place and in time. The disease course is characterized by exacerbations and remissions. Patients may develop the following symptoms:

- Weakness or spastic paresis occurring from damage to the corticospinal tract.
- Monocular blindness or scotoma resulting from optic nerve damage.
- Paresthesias occurring from damage to the dorsal columns.
- Ataxia resulting from damage to cerebellar connections in the brain stem, dorsal columns, or spinocerebellar tracts.
- Diplopia most often occurring after damage to the MLF, a brain stem pathway connecting the cranial nerve nuclei that control extraocular movement with each other and with the cerebellum, vestibular nuclei, and cervical proprioceptive input.

The Brain Stem

5

The brain stem is divisible into three continuous parts, the midbrain, the pons, and the medulla. The midbrain is most rostral and begins just below the diencephalon. The pons is in the middle and is overlain by the cerebellum.

The medulla is caudal to the pons and is continuous with the spinal cord.

The brain stem is the home of the origins or sites of termination of fibers in 9 of the 12 cranial nerves (CN).

CRANIAL NERVES

Two cranial nerves, the oculomotor and trochlear (CN III and IV), arise from the midbrain (Fig IV-5-1).

Four cranial nerves, the trigeminal, abducens, facial, and vestibulocochlear nerves (CN V, VI, VII, and VIII), enter or exit from the pons.

Three cranial nerves, the glossopharyngeal, vagus, and hypoglossal nerves (CN IX, X, and XII), enter or exit from the medulla. Fibers of the accessory nerve arise from the cervical spinal cord.

Cranial n. III, VI, XII – all medial

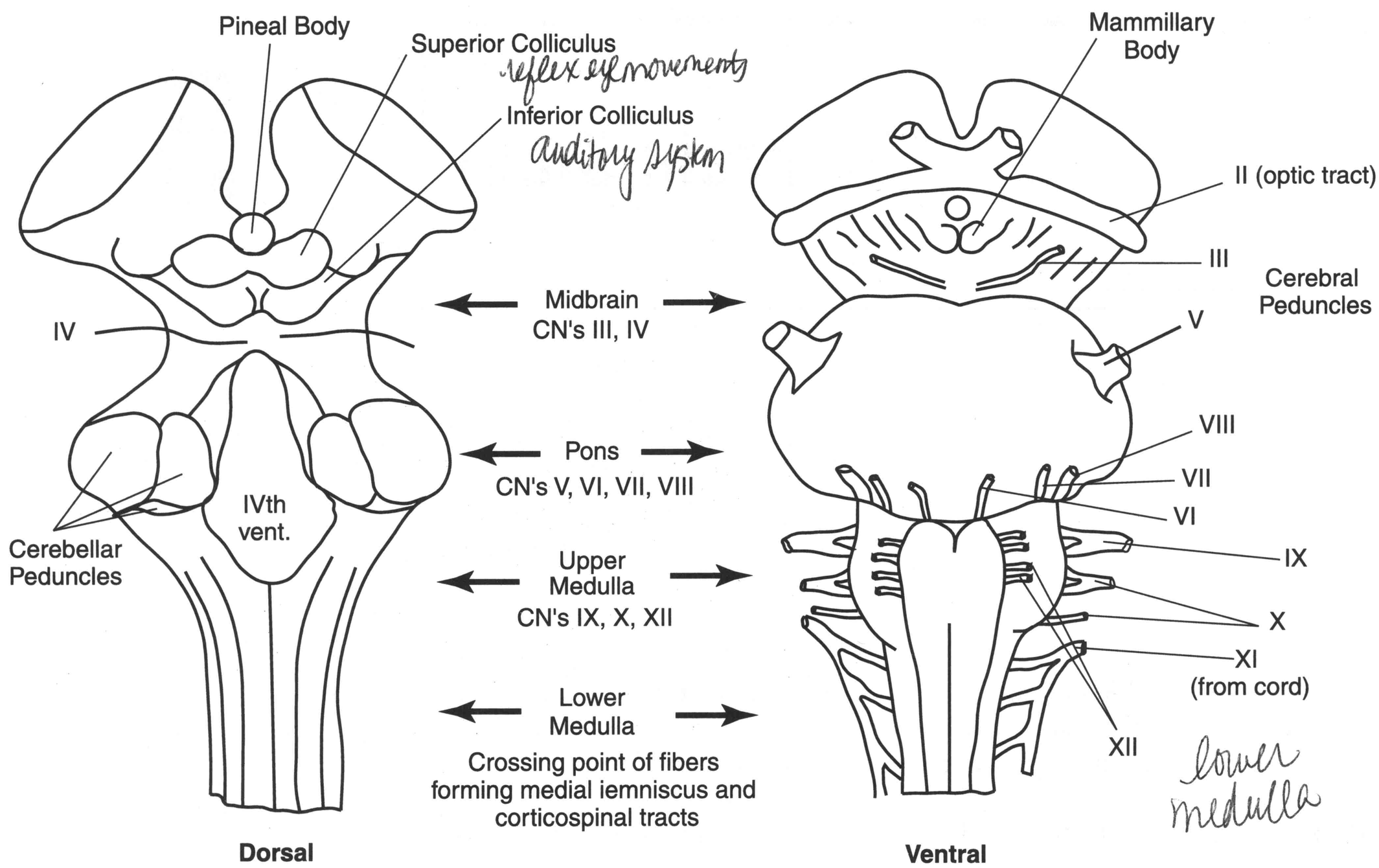

Figure IV-5-1. Brainstem and Cranial Nerve–Surface Anatomy

Clinical Correlate

Pineal tumors result in Parinaud's syndrome: paralysis of upward gaze and noncommunicating hydrocephalus.

Clinical Correlate

Schwannomas typically affect VIII nerve fibers seen in neurofibromatosis type 2.

Afferent fibers of cranial nerves enter the CNS and terminate in relation to aggregates of neurons in sensory nuclei. Motor or efferent components of cranial nerves arise from motor nuclei. All motor and sensory nuclei that contribute fibers to cranial nerves are organized in a series of discontinuous columns according to the functional component that they contain. Motor nuclei are situated medially, closest to the midline, and sensory nuclei are situated lateral to the motor nuclei. A cranial nerve nucleus or nerve will be found at virtually every transverse sectional level of the brain stem (Fig IV-5-2).

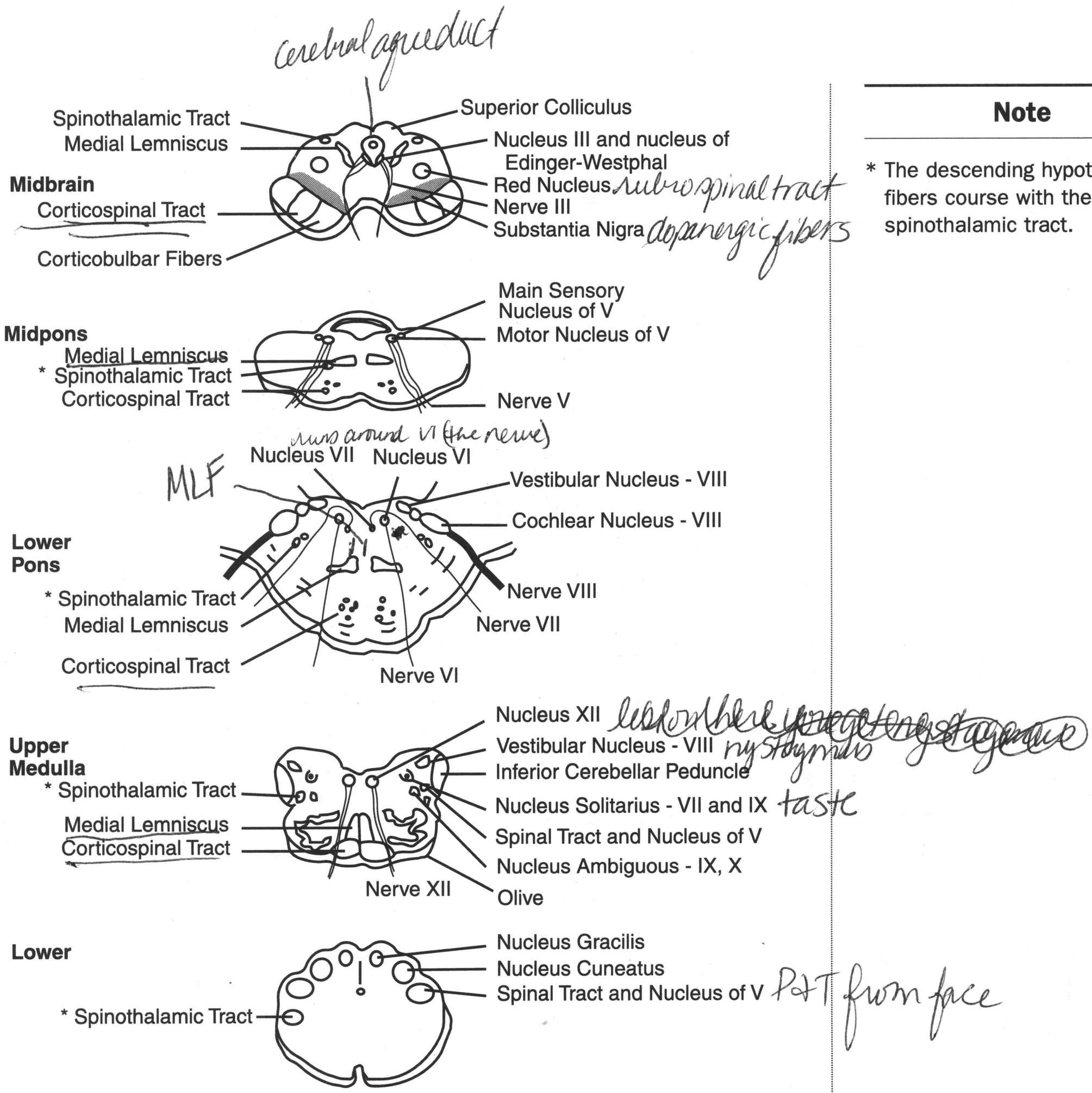

Figure IV-5-2. Brainstem: Cranial Nerves and Identification of Sections

Note

* The descending hypothalamic fibers course with the spinothalamic tract.

Table IV-5-1. Cranial Nerves: Functional Features

CN	Name	Type	Function	Lesions Result in	Exits/Enters Cranium	Region Innervated
I	Olfactory	Sensory	Smells	Anosmia	Cribriform plate	Nasal cavity
II	Optic	Sensory	Sees (optic nerve is really a tract of CNS with meninges)	Visual field deficits (anopsia) Loss of light reflex with III Only nerve to be affected by MS (swinging flashlight test)	Optic canal	Orbit
VIII	Vestibulocochlear	Sensory	Hears Linear acceleration (gravity) Angular acceleration (head turning)	Sensorineural hearing loss Loss of balance, nystagmus	Internal auditory meatus	Inner ear
III	Oculomotor	Motor	Moves eyeball in all directions Adduction (medial rectus) most important action Constricts pupil (sphincter pupillae) Accommodates (ciliary muscle) Raises eyelid (levator palpebrae superioris)	Diplopia—external strabismus Loss of parallel gaze Dilated pupil, loss of light reflex with II Loss of near response Ptosis	Superior orbital fissure	Orbit
IV	Trochlear	Motor	Superior oblique—depresses and abducts eyeball (makes eyeball look down and out) Intorts	Weakness looking down and in Trouble going down stairs Head tilts away from lesioned side	Superior orbital fissure	Orbit
VI	Abducens	Motor	Lateral rectus—abducts eyeball	Diplopia—internal strabismus Loss of parallel gaze, "pseudoptosis"	Superior orbital fissure	Orbit
XI	Accessory	Motor	Turns head to opposite side (sternocleidomastoid) Elevates and rotates scapula (trapezius)	Weakness turning head to opposite side Shoulder droop	Jugular foramen	Neck
XII	Hypoglossal	Motor	Moves tongue (styloglossus, hyoglossus, genioglossus, and intrinsics—palatoglossus is by X)	Tongue pointing toward same (affected) side on protrusion	Hypoglossal canal	Tongue
V	Trigeminal Ophthalmic (V1)	Mixed	General sensation (touch, pain, temperature) of forehead/scalp/ cornea	V1—loss of general sensation in skin of forehead/scalp Loss of blink reflex with VII	V1—superior orbital fissure (ophthalmic division)	Orbit and scalp
	Maxillary (V2)		General sensation of palate, nasal cavity, maxillary face, maxillary teeth	V2—loss of general sensation in skin over maxilla, maxillary teeth	V2—foramen rotundum (maxillary division)	Pterygopalatine fossa (leave by openings to face, oral and nasal cavity)
	Mandibular (V3)		General sensation of anterior two thirds of tongue, mandibular face, mandibular teeth Motor to muscles of mastication (temporalis, masseter, medial and lateral pterygoids) and anterior belly of digastric, mylohyoid, tensor tympani, tensor palati	V3—loss of general sensation in skin over mandible, mandibular teeth, tongue, weakness in chewing Jaw deviation toward weak side Trigeminal neuralgia—intractable pain in V2 or V3 territory	V3—foramen ovale (mandibular division)	Infratemporal Fossa

(continued)

Table IV-5-1. Cranial Nerves: Functional Features *(continued)*

CN	Name	Type	Function	Lesions Result in	Exits/Enters Cranium	Region Innervated
VII	Facial	Mixed	To muscles of facial expression, posterior belly of digastric, stylohyoid, stapedius Tastes anterior two thirds of tongue/palate Salivates (submandibular, sublingual glands) Tears (lacrimal gland) Makes mucus (nasal and palatine glands)	Corner of mouth droops, can't close eye, can't wrinkle forehead, loss of blink reflex, hyperacusis Alteration or loss of taste (ageusia) Eye dry and red Bell's palsy–lesion of nerve in facial canal	Internal auditory meatu	Face, nasal, and oral cavity (branches leave skull in stylomastoid foramen, petrotympanic fissure, or hiatus of facial canal)
IX	Glossopharyngeal	Mixed	Senses pharynx, carotid sinus/ body Salivates (parotid gland) Tastes and senses posterior one third of tongue Motor to one muscle—stylopharyngeus	Loss of gag reflex with X	Jugular foramen	Neck Pharynx/tongue
X	Vagus	Mixed	To muscles of palate and pharynx for swallowing except tensor palati (V) and stylopharyngeus (IX) To all muscles of larynx (phonates) Senses larynx and laryngopharynx Senses larynx and GI tract To GI tract smooth muscle and glands in foregut and midgut	Nasal speech, nasal regurgitation Dysphagia, palate droop Uvula pointing away from affected side Hoarseness/fixed vocal cord Loss of gag reflex with IX Loss of cough reflex	Jugular forame	Neck Pharynx/larynx Thorax, abdomen
	Sympathetics to head	Motor	Raises eyelid (superior tarsal muscle) Dilates pupil Innervates sweat glands of face and scalp Constricts blood vessels in head	Horner's syndrome: eyelid droop (ptosis), constricted pupil (miosis), loss of sweating (anhydrosis), flushed face	Carotid canal on internal carotid artery	Orbit, face, scalp

NEURAL SYSTEMS

Each of the following five ascending or descending neural tracts, fibers, or fasciculi course through the brain stem and will be found at every transverse sectional level.

Medial Lemniscus

The medial lemniscus (ML) contains the axons from cell bodies found in the dorsal column nuclei (gracilis and cuneatus) in the caudal medulla and represents the second neuron in the pathway to the thalamus and cortex for discriminative touch, vibration, pressure, and conscious proprioception. The axons in the ML cross the midline of the medulla immediately after emerging from the dorsal column nuclei. Lesions in the ML, in any part of the brain stem, result in a loss of discriminative touch, vibration, pressure, and conscious proprioception from the **contralateral** side of the body.

Spinothalamic Tract (part of anterolateral system)

The spinothalamic tract has its cells of origin in the spinal cord and represents the crossed axons of the second neuron in the pathway conveying pain and temperature to the thalamus and cortex. Lesions of the spinothalamic tract, in any part of the brain stem, results in a loss of pain and temperature sensations from the **contralateral** side of the body.

Corticospinal Tract

The corticospinal tract controls the activity of lower motoneurons, and interneuron pools for lower motoneurons course through the brain stem on their way to the spinal cord. Lesions of this tract produce a spastic paresis in skeletal muscles of the body **contralateral** to the lesion site in the brain stem.

Descending Hypothalamic Fibers

lesion same side

The descending hypothalamic fibers arise in the hypothalamus and course without crossing through the brain stem to terminate on preganglionic sympathetic neurons in the spinal cord. Lesions of this pathway produce an ipsilateral **Horner's syndrome.** Horner's syndrome consists of miosis (pupillary constriction), ptosis (drooping eyelid), and anhidrosis (lack of sweating) in the face ipsilateral to the side of the lesion.

Descending hypothalamic fibers course with the spinothalamic fibers in the lateral part of the brain stem. Therefore, brain stem lesions producing Horner's syndrome may also result in a contralateral loss of pain and temperature sensations from the limbs and body.

Medial Longitudinal Fasciculus

The medial longitudinal fasciculus is a fiber bundle interconnecting centers for horizontal gaze, the vestibular nuclei, and the nerve nuclei of CN III, IV, and VI, which innervate skeletal muscles that move the eyeball. This fiber bundle courses close to the dorsal midline of the brain stem and also contains vestibulospinal fibers, which course through the medulla to the spinal cord. Lesions of the fasciculus produce internuclear ophthalmoplegia and disrupt the vestibulo-ocular reflex.

MEDULLA

In the caudal medulla, two of the neural systems, the corticospinal and dorsal column–medial lemniscal pathways, send axons across the midline. The nucleus gracilis and nucleus cuneatus give rise to axons that decussate in the caudal medulla (the crossing axons are the internal arcuate fibers), which then form and ascend in the medial lemniscus.

The corticospinal (pyramidal) tracts, which are contained in the pyramids, course ventromedially through the medulla. Most of these fibers decussate in the caudal medulla just below the crossing of axons from the dorsal column nuclei, and then travel down the spinal cord as the (lateral) corticospinal tract.

The olives are located lateral to the pyramids in the rostral two thirds of the medulla. The olives contain the convoluted inferior olivary nuclei. The olivary nuclei send climbing (olivocerebellar) fibers into the cerebellum through the inferior cerebellar peduncle. The olives are a key distinguishing feature of the medulla.

The spinothalamic tract and the descending hypothalamic fibers course together in the lateral part of the medulla below the inferior cerebellar peduncle and near the spinal nucleus and tract of CN V.

Cranial Nerve Nuclei

Spinal Nucleus of V

The spinal nucleus of the trigeminal nerve (CN V) is located in a position analogous to the dorsal horn of the spinal cord. The spinal tract of the trigeminal nerve lies just lateral to this nucleus and extends from the upper cervical cord (C2) to the point of entry of the fifth cranial nerve in the pons. Central processes from cells in the trigeminal ganglion conveying pain and temperature sensations from the face enter the brain stem in the rostral pons but descend in the spinal tract of CN V and synapse on cells in the spinal nucleus (Fig IV-5-3).

Solitary Nucleus

The solitary nucleus receives the axons of all general and special visceral afferent fibers carried into the CNS by CN VII, IX, and X. These include both taste and visceral sensations carried by these cranial nerves. Taste and visceral sensory neurons all have their cell bodies in ganglia associated with CN VII, IX, and X outside the CNS.

Nucleus Ambiguus lat. part of medulla

The nucleus ambiguus is a column of large motoneurons situated dorsal to the inferior olive. Axons arising from cells in this nucleus course in the ninth and tenth cranial nerves. The component to the ninth nerve is insignificant. In the tenth nerve, these fibers supply muscles of the soft palate, larynx, pharynx, and upper esophagus. A unilateral lesion will produce ipsilateral paralysis of the soft palate causing the uvula to deviate away from the lesioned nerve and nasal regurgitation of liquids, weakness of laryngeal muscles causing hoarseness, and pharyngeal weakness resulting in difficulty in swallowing.

Dorsal Motor Nucleus of CN X

These visceral motoneurons of CN X are located lateral to the hypoglossal nucleus in the floor of the fourth ventricle. This is a major parasympathetic nucleus of the brain stem, and it supplies preganglionic fibers innervating terminal ganglia in the thorax and the foregut and midgut parts of the gastrointestinal tract.

Hypoglossal Nucleus

The hypoglossal nucleus is situated near the midline just beneath the central canal and fourth ventricle. This nucleus sends axons into the hypoglossal nerve to innervate all of the tongue muscles except the palatoglossus.

The Accessory Nucleus

The accessory nucleus is found in the cervical spinal cord. The axons of the spinal accessory nerve arise from the accessory nucleus, pass through the foramen magnum to enter the cranial cavity, and join the fibers of the vagus to exit the cranial cavity through the jugular foramen. As a result, intramedullary lesions do not affect fibers of the spinal accessory nerve. The spinal accessory nerve supplies the sternocleidomastoid and trapezius muscles.

The rootlets of the glossopharyngeal (CN IX) and vagus (CN X) nerves exit between the olive and the fibers of the inferior cerebellar peduncle. The hypoglossal nerve (CN XII) exits more medially between the olive and the medullary pyramid.

PONS

The pons is located between the medulla (caudally) and the midbrain (rostrally). The cerebellum overlies the pons. It is connected to the brain stem by three pairs of cerebellar peduncles. The fourth ventricle is found between the dorsal surface of the pons and the cerebellum. The ventral surface of the pons is dominated by fibers, which form a large ventral enlargement that carries fibers from pontine nuclei to the cerebellum in the middle cerebellar peduncle. This ventral enlargement is the key distinguishing feature of the pons.

The corticospinal tracts are more diffuse in the pons than in the medulla and are embedded in the transversely coursing fibers that enter the cerebellum in the middle cerebellar peduncle.

The medial lemniscus is still situated near the midline but is now separated from the corticospinal tracts by the fibers forming the middle cerebellar peduncle. The medial lemniscus has changed from a dorsoventral orientation in the medulla to a more horizontal orientation in the pons.

The spinothalamic tract and the descending hypothalamic fibers continue to course together in the lateral pons.

The lateral lemniscus, an ascending auditory pathway, is lateral and just dorsal to the medial lemniscus. The lateral lemniscus carries the bulk of ascending auditory fibers from both cochlear nuclei to the inferior colliculus of the midbrain.

The medial longitudinal fasciculus (MLF) is located near the midline just beneath the fourth ventricle.

Cranial Nerve Nuclei

Abducens Nucleus

The abducens nucleus is found near the midline in the floor of the fourth ventricle just lateral to the MLF.

Facial Motor Nucleus

The facial motor nucleus is located ventrolateral to the abducens nucleus. Fibers from the facial nucleus curve around the posterior side of the abducens nucleus (the curve forms the internal genu of the facial nerve), then pass ventrolaterally to exit the brain stem at the pontomedullary junction.

Superior Olivary Nucleus

The superior olivary nucleus lies immediately ventral to the nucleus of CN VII and receives auditory impulses from both ears by way of the cochlear nuclei. The

Clinical Correlate

The abducens nucleus is coexistent with the PPRF, the center for ipsilateral horizontal gaze. Lesions have resulted in an inability to look to the lesion side, and may include a complete ipsilateral facial paralysis of the VIIth nerve fibers.

cochlear nuclei are found at the pontomedullary junction just lateral to the inferior cerebellar peduncle.

Vestibular Nuclei

The vestibular nuclei are located near the posterior surface of the pons lateral to the abducens nucleus, and extend into the medulla.

Cochlear Nuclei

The dorsal and ventral cochlear nuclei are found at the ponto medullary junction. All of the fibers of the cochlear part of the VIIIth nerve terminate here.

Trigeminal Nuclei

Motor Nucleus

The motor nucleus of CN V is located in the pons just medial to the main sensory nucleus of the trigeminal and adjacent to the point of exit or entry of the trigeminal nerve fibers. These motor fibers supply the muscles of mastication (masseter, temporalis, and medial and lateral pterygoid; Fig IV-5-3).

Sensory Nucleus

The main sensory nucleus is located just lateral to the motor nucleus.

The main sensory nucleus receives tactile and pressure sensations from the face, scalp, oral cavity, nasal cavity, and dura.

Spinal Trigeminal Nucleus

The spinal trigeminal nucleus is a caudal continuation of the main sensory nucleus, extending from the mid pons through the medulla to the cervical cord. Central processes from cells in the trigeminal ganglion conveying pain and temperature sensations from the face descend in the spinal tract of V and synapse on cells in the spinal nucleus.

Mesencephalic Nucleus

The mesencephalic nucleus of CN V is located at the point of entry of the fifth nerve and extends into the midbrain. It receives proprioceptive input from joints, muscles of mastication, extraocular muscles, teeth, and the periodontium. Some of these fibers synapse monosynaptically on the motoneurons, forming the sensory limb of the jaw jerk reflex.

VPL - all projections from nucleus body

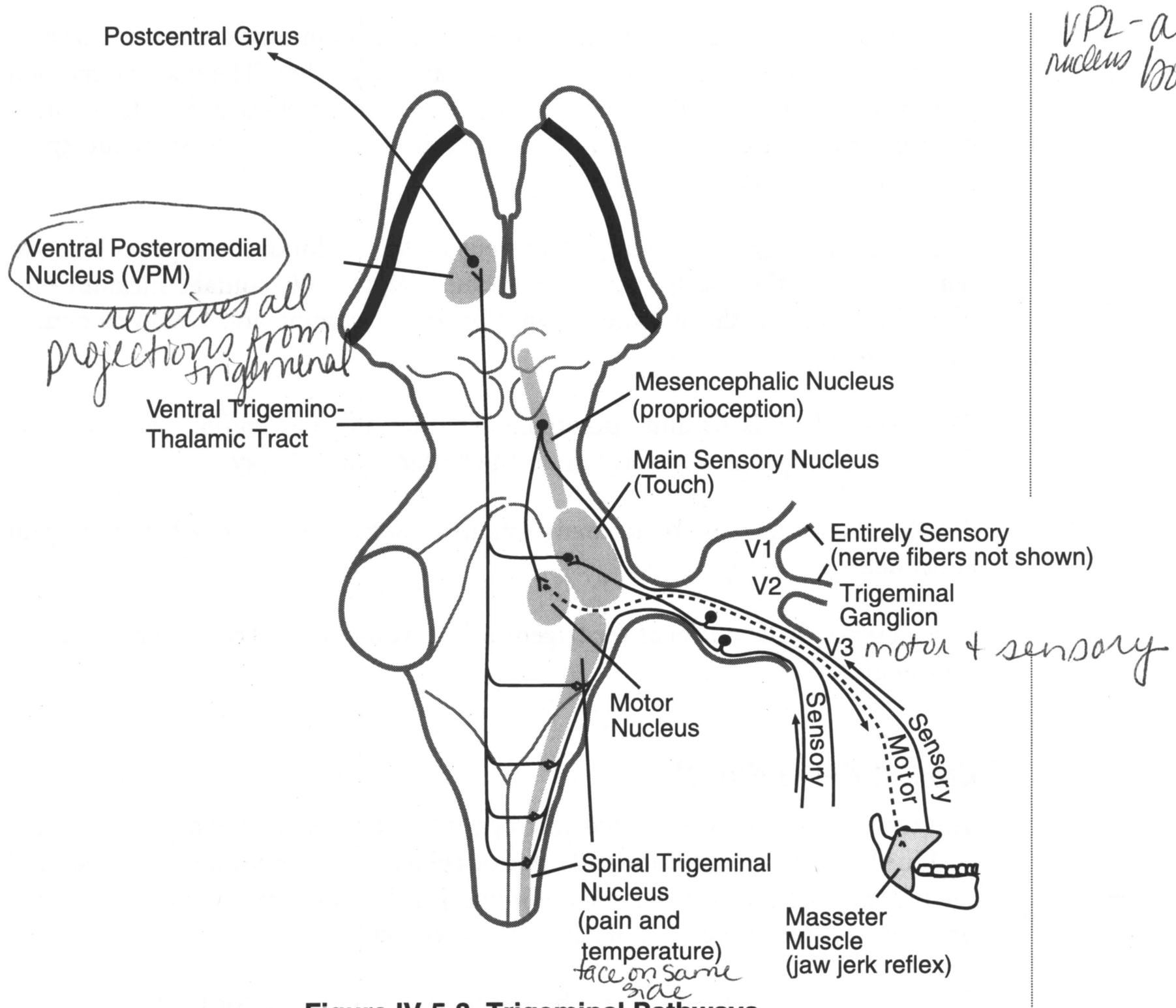

Figure IV-5-3. Trigeminal Pathways

Cranial Nerves V, VI, VII, and VIII

Four cranial nerves emerge from the pons. Cranial nerves VI, VII, and VIII emerge from the pontomedullary junction. The facial nerve is located medial to the vestibulocochlear nerve. The abducens nerve (CN VI) emerges near the midline medial to the corticospinal tract. The trigeminal nerve (CN V) emerges from the middle of the pons.

MIDBRAIN

The midbrain (mesencephalon) is located between the pons and diencephalon. The cerebral aqueduct, a narrow channel that connects the third and fourth ventricles, passes through the midbrain. The inferior colliculi and superior colliculi are found on the dorsal aspect of the midbrain above the cerebral aqueduct. The inferior colliculus processes auditory information received bilaterally from the cochlear nuclei by axon fibers of the lateral lemniscus. The superior colliculi help direct movements of both eyes in gaze. The pretectal region is located just

beneath the superior colliculi and in front of the oculomotor complex. This area contains interneurons involved in the pupillary light reflex. The massive cerebral peduncles extend ventrally from the midbrain. The cerebral peduncles contain corticospinal and corticobulbar fibers. The interpeduncular fossa is the space between the cerebral peduncles.

The substantia nigra is the largest nucleus of the midbrain. It appears black to dark brown in the freshly cut brain because nigral cells contain melanin pigments. Neurons in the substantia nigra utilize Dopamine and GABA as neurotransmitters.

The medial lemniscus and spinothalamic tract and descending hypothalamic fibers course together ventrolateral to the periaqueductal gray.

The MLF continues to be located near the midline, just beneath the cerebral aqueduct.

The mesencephalic nuclei of the trigeminal nerve are located on either side of the central gray.

Cranial Nerve Nuclei

The trochlear nucleus is located just beneath the periaqueductal gray near the midline between the superior and inferior colliculi. The oculomotor nucleus and the nucleus of Edinger-Westphal are found just beneath the periaqueductal gray near the midline at the level of the superior colliculi.

Two cranial nerves emerge from the midbrain: the oculomotor (CN III) and the trochlear (CN IV) nerves.

The **oculomotor nerve** arises from the oculomotor nucleus and exits ventrally from the midbrain in the interpeduncular fossa. CN III also contains preganglionic parasympathetic axons that arise from the nucleus of Edinger-Westphal, which lies adjacent to the oculomotor nucleus.

Axons of the **trochlear nerve** decussate in the superior medullary velum and exit the brain stem near the posterior midline just inferior to the inferior colliculi.

Corticobulbar Innervation of Cranial Nerve Nuclei

Corticobulbar fibers serve as the source of upper motoneuron innervation of lower motoneurons in cranial nerve nuclei (Fig IV-5-4). Corticobulbar fibers arise in the motor cortex and influence lower motoneurons in all brain stem nuclei that innervate skeletal muscles. This includes:

- Muscles of mastication (CN V)
- Muscles of facial expression (CN VII)
- Palate, pharynx, and larynx (CN X)
- Tongue (CN XII)
- Sternocleidomastoid and trapezius muscles (CN XI)

The corticobulbar innervation of cranial nerve lower motoneurons is predominantly bilateral, in that each lower motoneuron in a cranial nerve nucleus receives input from corticobulbar axons arising from both the right and the left cerebral cortex.

Clinical Correlate

Facial Paralysis

The upper motoneuron innervation of lower motoneurons in the facial motor nucleus is different and clinically significant. Like most cranial nerve lower motoneurons, the corticobulbar innervation of facial motoneurons to muscles of the upper face (which wrinkle the forehead and shut the eyes) is bilateral. The corticobulbar innervation of facial motoneurons to muscles of the mouth, however, is contralateral only. Clinically, this means that one can differentiate between a lesion of the seventh nerve and a lesion of the corticobulbar fibers to the facial motor nucleus. A facial nerve lesion (as in **Bell's Palsy**) will result in a complete ipsilateral paralysis of muscles of facial expression, including an inability to wrinkle the forehead or shut the eyes and a drooping of the corner of the mouth. A corticobulbar lesion will result in only a drooping of the corner of the mouth on the contralateral side of the face and no other facial motor deficits. Generally, no other cranial deficits will be seen with corticobulbar lesions because virtually every other cranial nerve nucleus is bilaterally innervated. In some individuals, the hypoglossal nucleus may receive mainly contralateral corticobulbar innervation. If these corticobulbar fibers are lesioned, the tongue muscles undergo transient weakness without atrophy or fasciculations and may deviate away from the injured corticobulbar fibers. If, for example, the lesion is in corticobulbar fibers on the left, there is transient weakness of the right tongue muscles, causing a deviation of the tongue toward the right side upon protrusion.



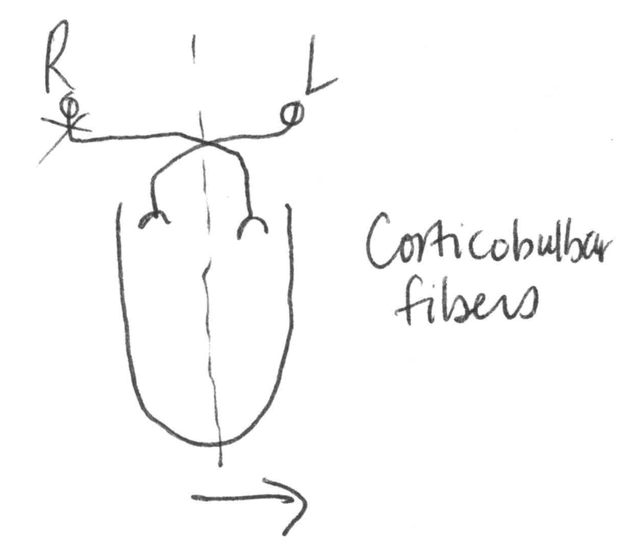

Abbreviations

LF = lower face innervation
UF = upper face innervation
UMN = upper motoneuron

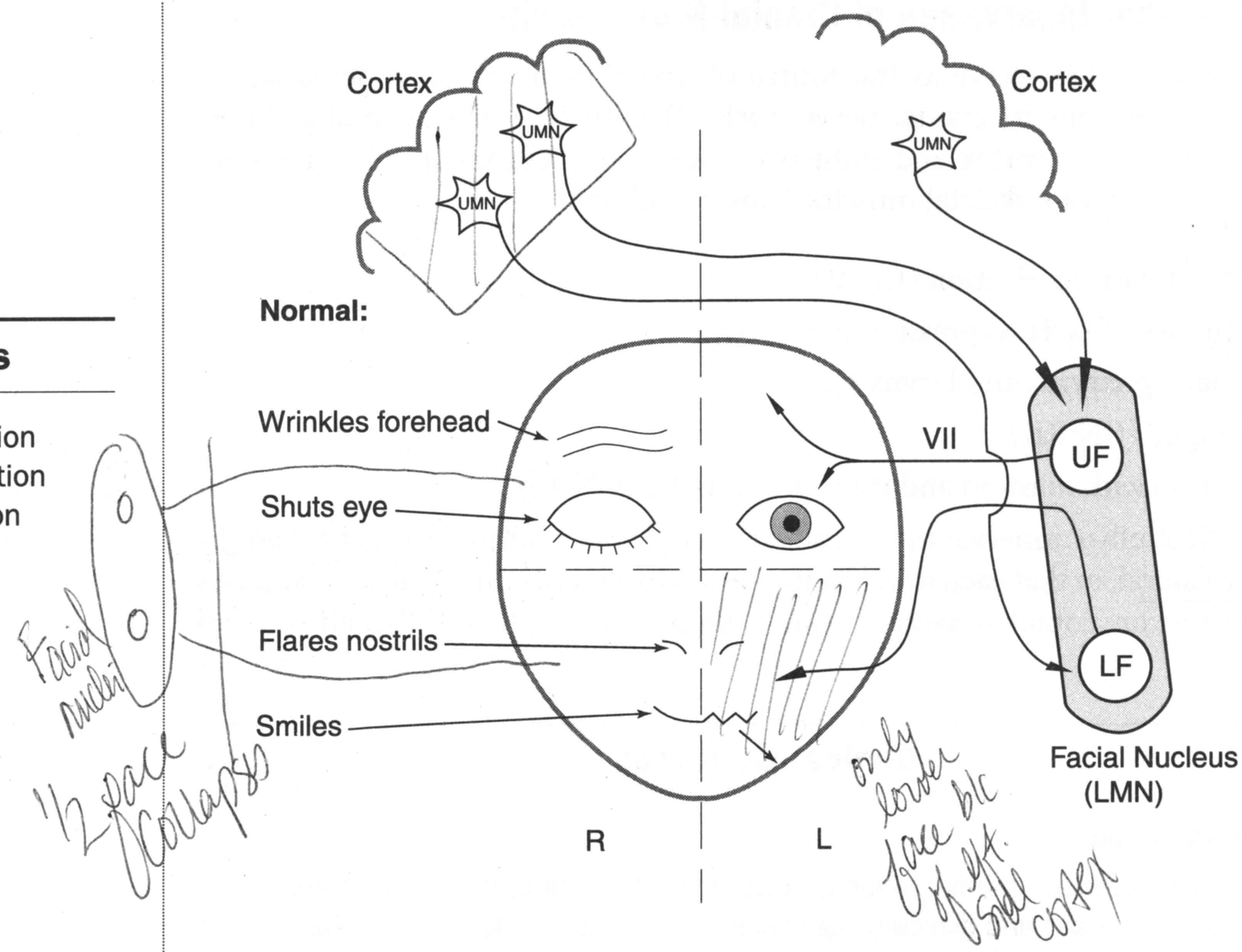

Figure IV-5-4. Corticobulbar Innervation of the Facial Motor Nucleus

COMPONENTS OF THE EAR, AUDITORY, AND VESTIBULAR SYSTEMS

Each ear consists of three components: two air-filled spaces, the external ear and the middle ear, and the fluid-filled spaces of the inner ear (Fig IV-5-5).

The external ear includes the pinna and the external auditory meatus, which extends to the tympanic membrane. Sound waves travel through the external auditory canal and cause the tympanic membrane (eardrum) to vibrate. Movement of the eardrum causes vibrations of the ossicles in the middle ear (i.e., the malleus, incus, and stapes). Vibrations of the ossicles are transferred through the oval window and into the inner ear.

The middle ear lies in the temporal bone, where the chain of three ossicles connect the tympanic membrane to the oval window. These auditory ossicles amplify the vibrations received by the tympanic membrane and transmit them to the fluid of the inner ear with minimal energy loss. The malleus is inserted in the tympanic membrane, and the stapes is inserted into the membrane of the oval window. Two small skeletal muscles, the tensor tympani and the stapedius, contract to prevent damage to the inner ear when the ear is exposed to loud sounds. The middle ear cavity communicates with the nasopharynx via the eustachian

tube, which allows air pressure to be equalized on both sides of the tympanic membrane.

The inner ear consists of a labyrinth of interconnected sacs (utricle and saccule) and channels (semicircular ducts and the cochlear duct) that contain patches of receptor or hair cells that respond to airborne vibrations or movements of the head. Both the cochlear duct and the sacs and channels of the vestibular labyrinth are filled with endolymph, which bathes the hairs of the hair cells. Endolymph is unique because it has the inorganic ionic composition of an intracellular fluid but it lies in an extracellular space. The intracellular ionic composition of endolymph is important for the function of hair cells. Perilymph, ionically like a typical extracellular fluid, lies outside the endolymph-filled labyrinth (Fig IV-5-6).

Clinical Correlate

Middle Ear Diseases

Middle ear diseases (otitis media, otosclerosis) result in a conductive hearing loss because of a reduction in amplification provided by the ossicles.

Lesions of the facial nerve in the brain stem or temporal bone (Bell's palsy) may result in hyperacusis, an increased sensitivity to loud sounds.

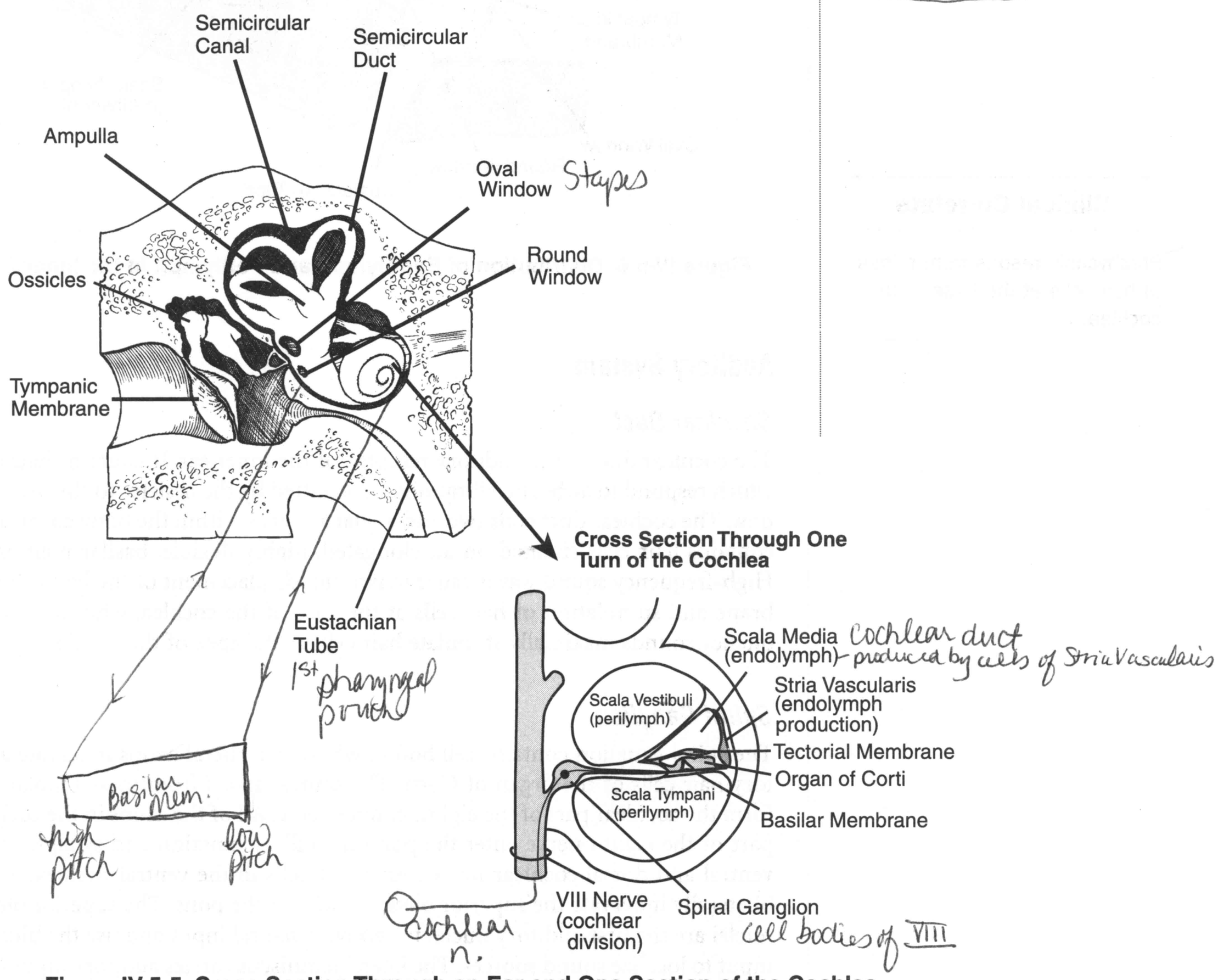

Figure IV-5-5. Cross Section Through an Ear and One Section of the Cochlea

endolymph ↑ K^+
perilymph ↑ Na^+
(similar to CSF)

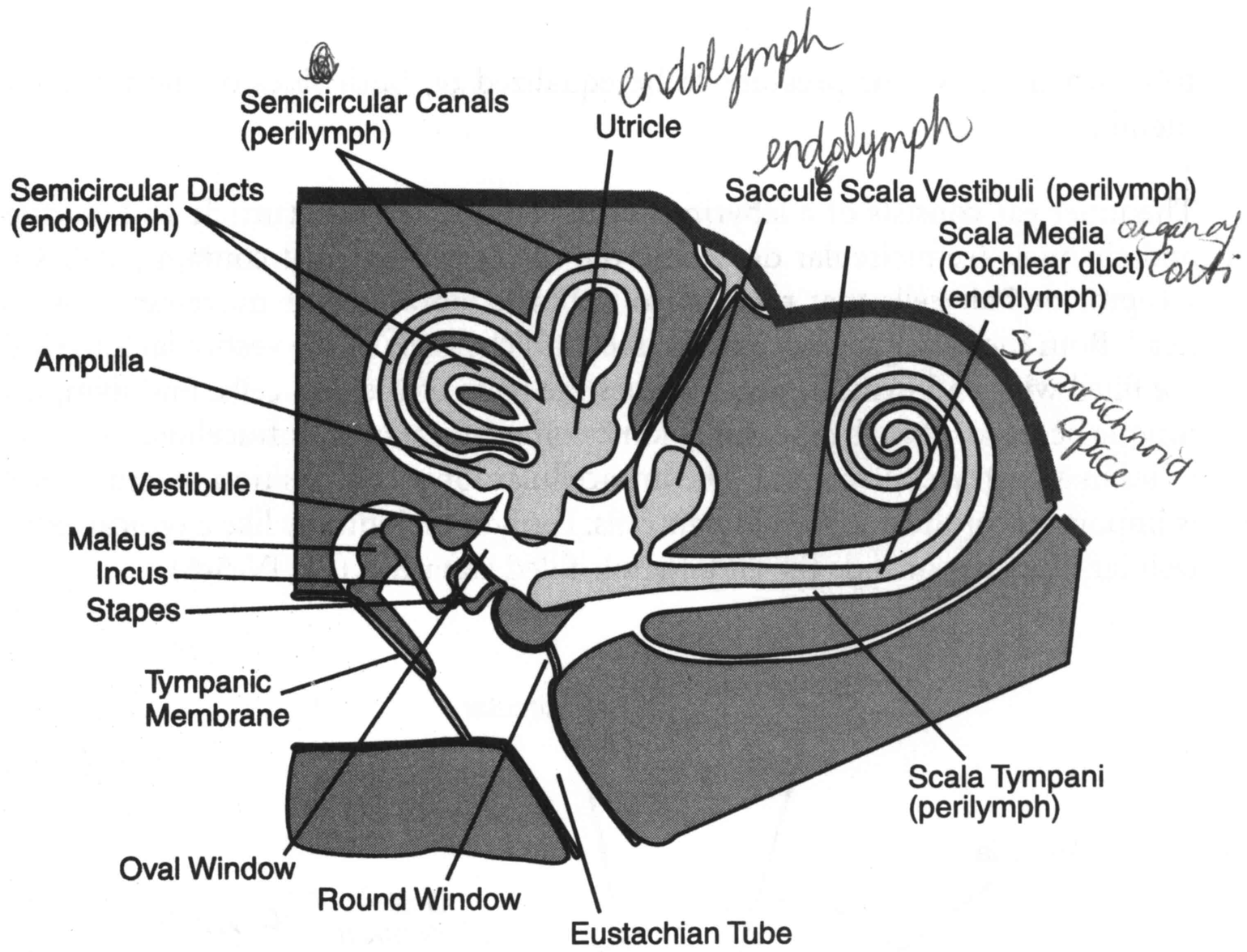

Figure IV-5-6. Distribution of Endolymph and Perilymph in the Inner Ear

Clinical Correlate

Presbycusis results from a loss of hair cells at the base of the cochlea.

Auditory System

Cochlear Duct

The cochlear duct is the auditory receptor of the inner ear. It contains hair cells, which respond to airborne vibrations transmitted by the ossicles to the oval window. The cochlear duct coils two and a quarter turns within the bony cochlea and contains hair cells situated on an elongated, highly flexible, basilar membrane. High-frequency sound waves cause maximum displacement of the basilar membrane and stimulation of hair cells at the base of the cochlea, whereas low-frequency sounds maximally stimulate hair cells at the apex of the cochlea.

Spiral Ganglion

The spiral ganglion contains cell bodies whose peripheral axons innervate auditory hair cells of the organ of Corti. The central axons from these bipolar cells form the cochlear part of the eighth cranial nerve. All of the axons in the cochlear part of the eighth nerve enter the pontomedullary junction and synapse in the ventral and dorsal cochlear nuclei. Axons of cells in the ventral cochlear nuclei bilaterally innervate the superior olivary nuclei in the pons. The superior olivary nuclei are the first auditory nuclei to receive binaural input and use the binaural input to localize sound sources. The lateral lemniscus carries auditory input from

the cochlear nuclei and the superior olivary nuclei to the inferior colliculus in the midbrain. Each lateral lemniscus carries information derived from both ears; however, input from the contralateral ear predominates (Fig IV-5-7).

Inferior Colliculus

The inferior colliculus sends auditory information to the medial geniculate body (MGB) of the thalamus. From the MGB, the auditory radiation projects to the primary auditory cortex located on the posterior portion of the transverse temporal gyrus (Heschl's gyrus; Brodmann areas 41 and 42). The adjacent auditory association area makes connections with other parts of the cortex, including Wernicke's area, the cortical area for the comprehension of language.

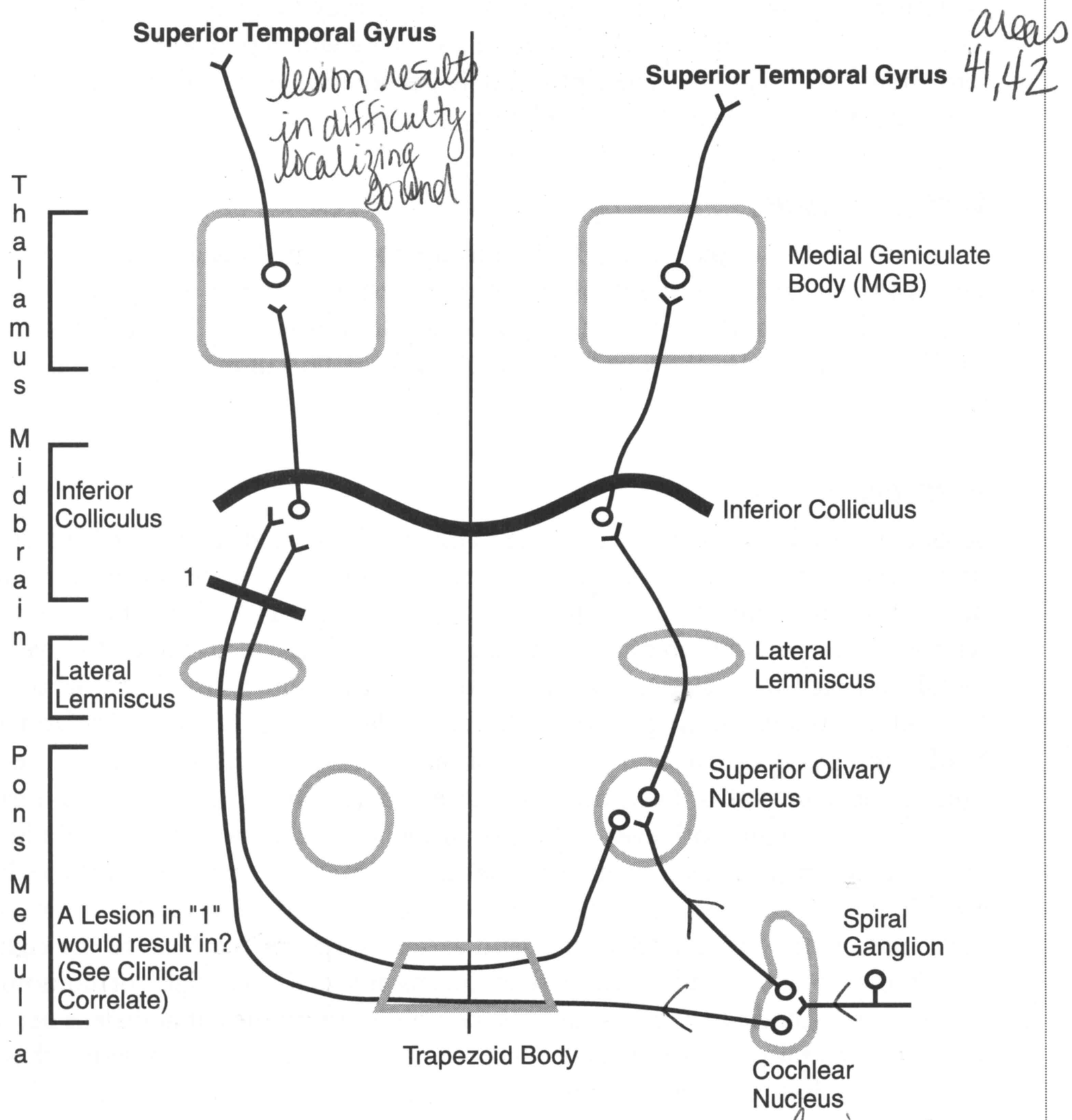

Figure IV-5-7. Auditory System

lesion causes deafness

Clinical Correlate

Lesions Causing Hearing Loss

Lesions of the cochlear part of the eighth nerve or cochlear nuclei inside the brain stem at the pontomedullary junction result in a profound unilateral sensorineural hearing loss. All other lesions to auditory structures in the brain stem, thalamus, or cortex result in a bilateral suppression of hearing and a decreased ability to localize a sound source. If a patient presents with a significant hearing loss in one ear, the lesion is most likely in the middle ear, inner ear, eighth nerve, or cochlear nuclei, and not at higher levels of the auditory system.

Vestibular System

- 2 major receptors < cristae - semicircular ducts in ampulla → angular acceleration; maculae - utricle + saccule → linear acceleration, respond to gravity

Sensory Receptors

The vestibular system contains two kinds of sensory receptors, one kind in the utricle and the saccule and the other in the semicircular ducts.

The utricle and the saccule are two large sacs, each containing a patch of hair cells in a macula. Each macula responds to linear acceleration and detects positional changes in the head relative to gravity. There are three semicircular ducts in the inner ear, each lying in a bony semicircular canal. Each semicircular duct contains an ampullary crest of hair cells that detect changes in angular acceleration resulting from circular movements of the head. The three semicircular ducts, anterior, posterior, and horizontal, are oriented such that they lie in the three planes of space. Circular movements of the head in any plane will depolarize hair cells in a semicircular duct in one labyrinth and hyperpolarize hair cells in the corresponding duct in the opposite labyrinth.

Vestibular Nuclei

There are four vestibular nuclei located in the rostral medulla and caudal pons. The vestibular nuclei receive afferents from the vestibular nerve, which innervates receptors located in the semicircular ducts, utricle, and saccule. Primary vestibular fibers terminate in the vestibular nuclei and the flocculonodular lobe of the cerebellum.

Vestibular Fibers

Secondary vestibular fibers, originating in the vestibular nuclei, join the MLF and supply the motor nuclei of CN III, IV, and VI. These fibers are involved in the production of conjugate eye movements. These compensatory eye movements represent the efferent limb of the vestibulo-ocular reflex, which enables the eye to remain focused on a stationary target during movement of the head or neck. Most of our understanding of the vestibulo-ocular reflex is based on horizontal head turning and a corresponding horizontal movement of the eyes in the direction opposite to that of head turning. For example, when the head turns horizontally to the right, both eyes will move to the left using the following vestibulo-ocular structures. Head turning to the right stimulates hairs cells in the right semicircular ducts. The right eighth nerve increases its firing rate to the right vestibular nuclei. These nuclei then send axons by way of the MLF to the right oculomotor nucleus and to the left abducens nucleus. The right oculomotor nerve to the right medial rectus adducts the right eye, and the left abducens nerve to the left lateral rectus abducts the left eye. The net effect of stimulating these nuclei is that both eyes will look to the left (Figs IV-5-8 and IV-5-9).

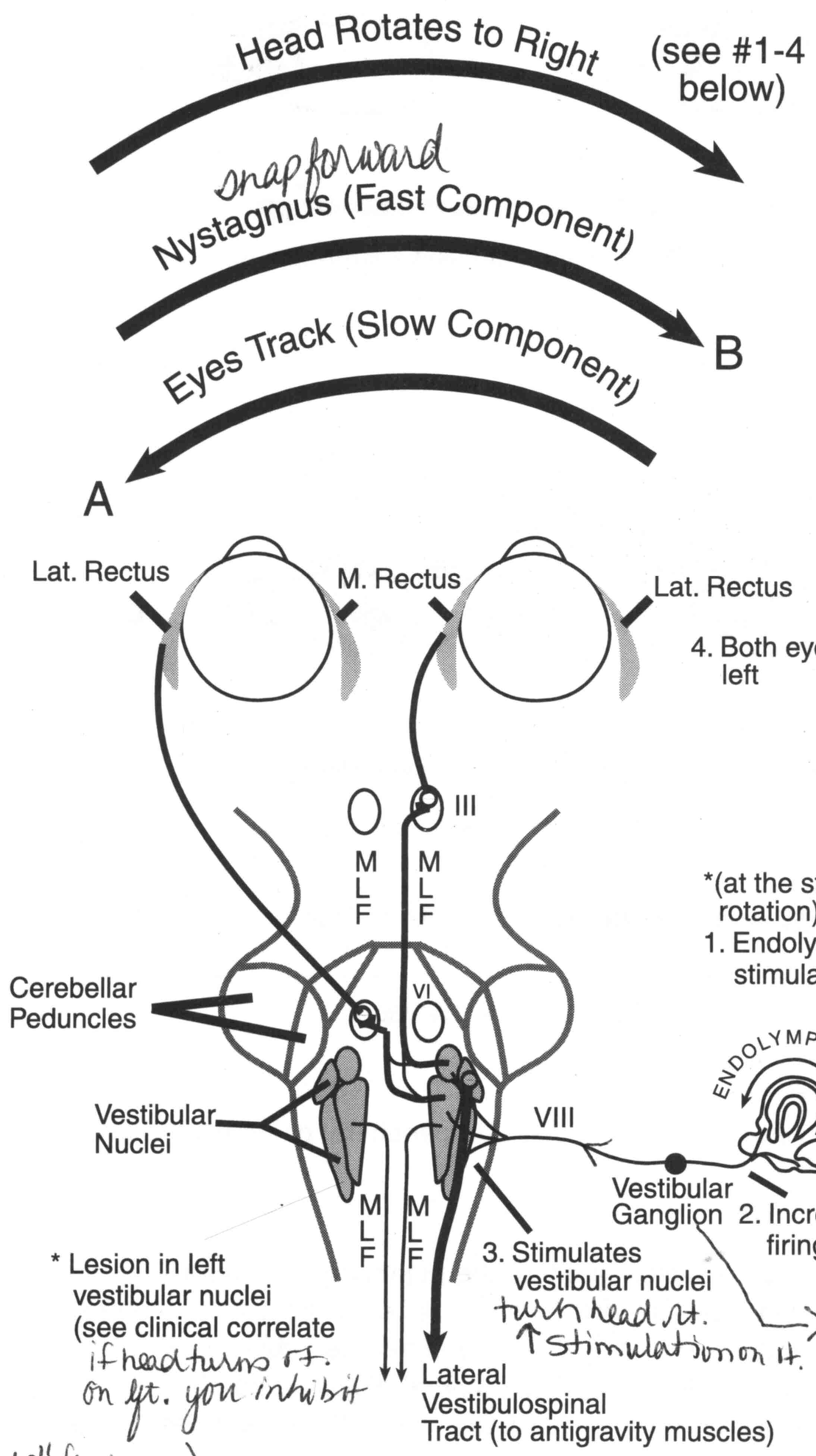

semicircular duct

when turn head rt. goes left. This ↑ firing rate b/c it depolarizes them.

if head turns rt. on lt. you inhibit

turn head rt. ↑ stimulation on it.

(rotate head to rt. eyes move to lft.)

vestibular ocular reflex checks if brainstem is intact

"COWS" (fast comp.)

Figure IV-5-8. The Vestibulo-Ocular Reflex

put cold water in ear on rt. side if eyes go left slowly then nystagmus on rt. therefore same side lesion

put cold water in left ear eyes go rt therefore opposite side lesion

cold-inhibit
warm-stimulate

Comatose person no fast component only slow component

lesion left side the nystagmus is on opposite side of lesion

Clinical Correlate

A lesion of the vestibular nuclei or nerve (in this example on the left) produces a vestibular nystagmus with a slow deviation of the eyes toward the lesion (A) and a fast correction back to the right (B).

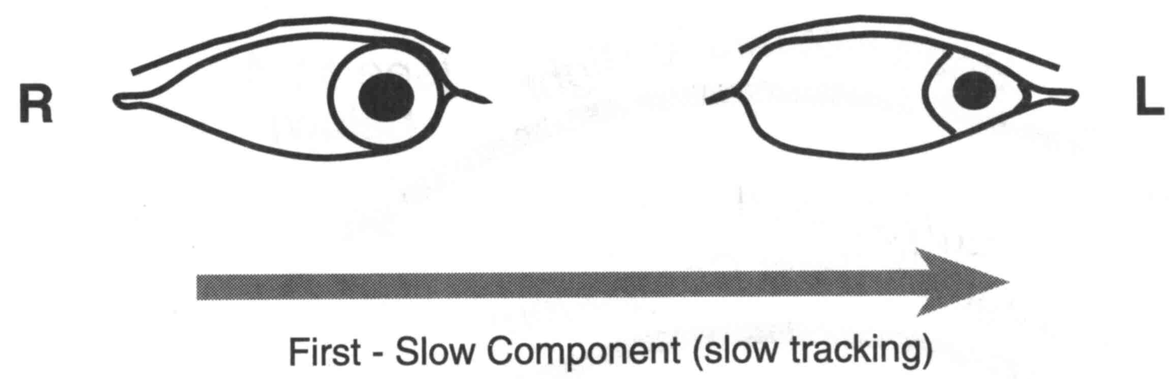

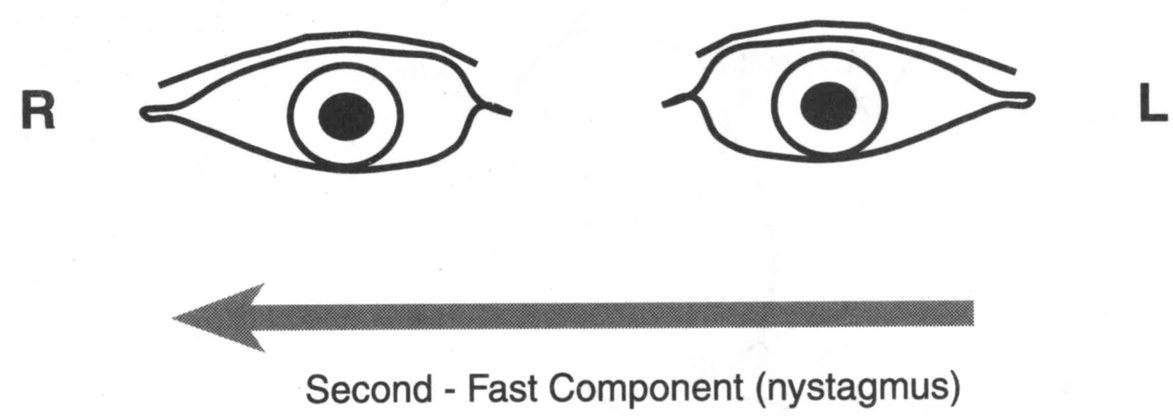

Figure IV-5-9. Vestibular System: Part 2

Clinical Correlate

Vestibular Dysfunction

Vestibular dysfunction may result from either peripheral or central lesions.

Vertigo

Vertigo may result from a lesion of either the peripheral (end organ, nerve) or central (nuclear, brain stem pathways) vestibular structures. Vertigo refers to the perception of rotation, which may involve either the subject or the external space. The vertigo is usually severe in peripheral disease and mild in brain stem disease. Chronic vertigo (i.e., persisting longer than 2–3 weeks) strongly suggests a central lesion.

Vertigo may also be caused by a variety of drugs, including anticonvulsants, aspirin, alcohol, and certain sedatives and antibiotics. Ménière's disease is characterized by abrupt, recurrent attacks of vertigo lasting minutes to hours accompanied by tinnitus or deafness and usually involving only one ear. Nausea and vomiting and a sensation of fullness or pressure in the ear also are common during the acute episode. The attacks often are severe, and the patient may be unable to stand. The disease usually occurs in middle age and results from distention of the fluid spaces in the cochlear and vestibular parts of the labyrinth.

Nystagmus

Nystagmus refers to rhythmic oscillations of the eyes slowly to one side followed by a rapid reflex movement in the opposite direction. Nystagmus is defined by the direction of the rapid reflex movement or the fast phase. It is usually horizontal, although rotatory or vertical nystagmus may also occur.

Unilateral vestibular nerve or vestibular nucleus lesions may result in a vestibular nystagmus. In a pathologic vestibular nystagmus, the initial slow phase is the response to the pathology, and the fast phase is the correction attempt made by the cortex in response to the pathology. Consider this example: if the left vestibular nerve or nuclei are lesioned, because of the loss of balance between the two sides, the right vestibular nuclei are unopposed and act as if they have been stimulated, causing both eyes to look slowly to the left. This is the slow phase of a pathologic vestibular nystagmus. Because the head did not move, the cortex responds by moving both eyes quickly back to the right, the direction of the fast phase of the nystagmus.

Tests for Nystagmus

The integrity of the vestibulo-ocular reflex can be an indicator of brain stem integrity in comatose patients. To test this reflex, a vestibular nystagmus is induced by performing a **caloric test** in which an examiner introduces warm or cool water into an external auditory meatus. Warm water introduced into the external ear stimulates the horizontal semicircular duct and causes the eyes to move slowly in the opposite direction. Because the head did not turn, the eyes are moved quickly back by the cortex (if intact) toward the same ear where the warm water was introduced, producing a fast phase of nystagmus to the same side. Introduction of cool water into the external ear mimics a lesion; the horizontal duct activity is inhibited on the cool water side, and the opposite vestibular complex moves the eyes slowly toward the cool water ear. The corrective or fast phase of the nystagmus moves the eyes quickly away from the ear where the cool water was introduced. A mnemonic which summarizes the direction of the fast phase of vestibular nystagmus in a caloric test toward the warm water side and away from the cool water side is COWS; cool, opposite, warm, same.

HORIZONTAL CONJUGATE GAZE

The eyeballs move together in conjugate gaze. The ocular muscles function to move and position both eyes as a unit so that an image falls on a corresponding spot on the retina of each eye. The slightest weakness in the movements of one eye causes diplopia, the presence of a double image, indicating that the image has been shifted to a different position on the retina of the affected side. Although gaze in all planes is possible, the muscles and cranial nerves involved in horizontal conjugate gaze, or abduction and adduction of both eyes together, are the most important eye movements (Fig IV-5-10).

Abduction of each eyeball is performed largely by the lateral rectus muscle, which is innervated by the abducens nerve (CN VI). Adduction of the eyeball is performed by the medial rectus muscle, which is innervated by the oculomotor nerve (CN III). Therefore, for both eyes to look to the right in horizontal gaze, the right abducens nerve and the right lateral rectus muscle must be active to abduct the right eye, and the left oculomotor nerve and the left medial rectus muscle must be active to adduct the left eye. The net effect is that both eyes will look to the right.

In the brain stem, the abducens nucleus (CN VI) and the oculomotor nucleus (CN III) are situated close to the midline just beneath the fourth ventricle or the cerebral aqueduct, in the pons and midbrain. These nuclei are interconnected by the fibers in the MLF. It is the fibers in the MLF that permit conjugate gaze, either when the target moves or when the head moves, through their interconnections to gaze centers and the vestibular system.

Control of Horizontal Gaze

Horizontal gaze is controlled by two interconnected gaze centers. One control center is in the frontal lobe, the frontal eye field (Brodmann area 8). This area acts as a center for **contralateral** horizontal gaze. In the pons is a second gaze center, known as the pontine gaze center or the PPRF, the paramedial pontine reticular formation. This is a center for **ipsilateral** horizontal gaze. When activated by neurons in the frontal eye field, the pontine gaze center neurons send axons to synapse with cell bodies in the abducens nucleus, which is actually contained within the pontine gaze center. The pontine gaze center also sends axons that cross immediately and course in the contralateral MLF to reach the contralateral oculomotor nucleus. The net effect of stimulation of the left frontal eye field, therefore, is activation of the pontine gaze center on the right and a saccadic horizontal eye movement of both eyes to the right. Horizontal gaze to the right results from activation of the right abducens nucleus and the left oculomotor nucleus by fibers in the MLF. Lesions in the MLF result in an internuclear ophthalmoplegia in which there is an ability to adduct one eye on attempted gaze to the opposite side. For example, a lesion in the right MLF results in an inability to adduct the right eye on an attempted gaze to the left. The left eye abducts normally but exhibits a nystagmus. If the MLF is lesioned bilaterally (as might be the case in multiple sclerosis), neither eye adducts on attempted gaze (Figs IV-5-11 and IV-5-12), and the abducting eye exhibits a nystagmus.

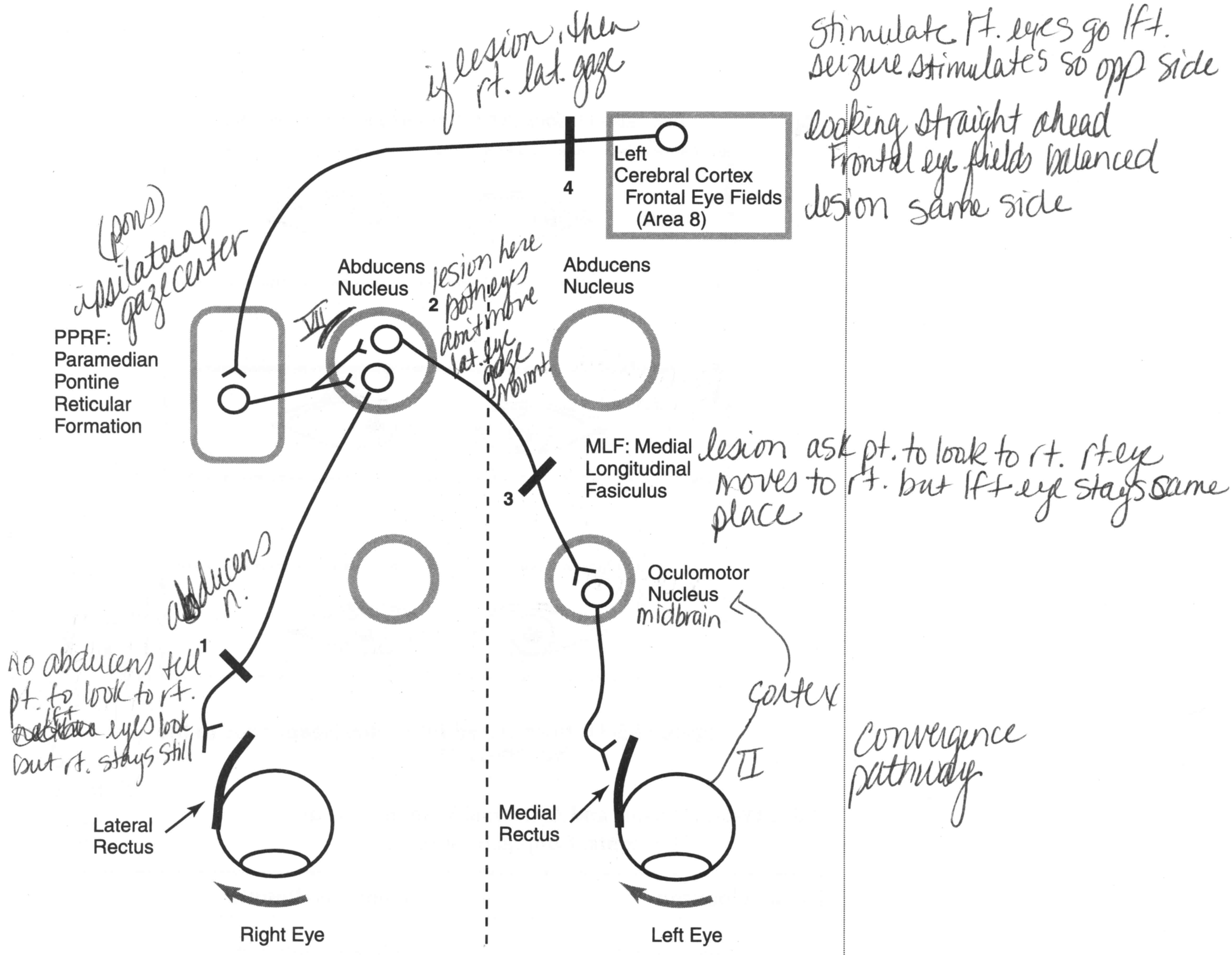

(Lesion sites are indicated by 1-4.)

Figure IV-5-10. Voluntary Horizontal Conjugate Gaze

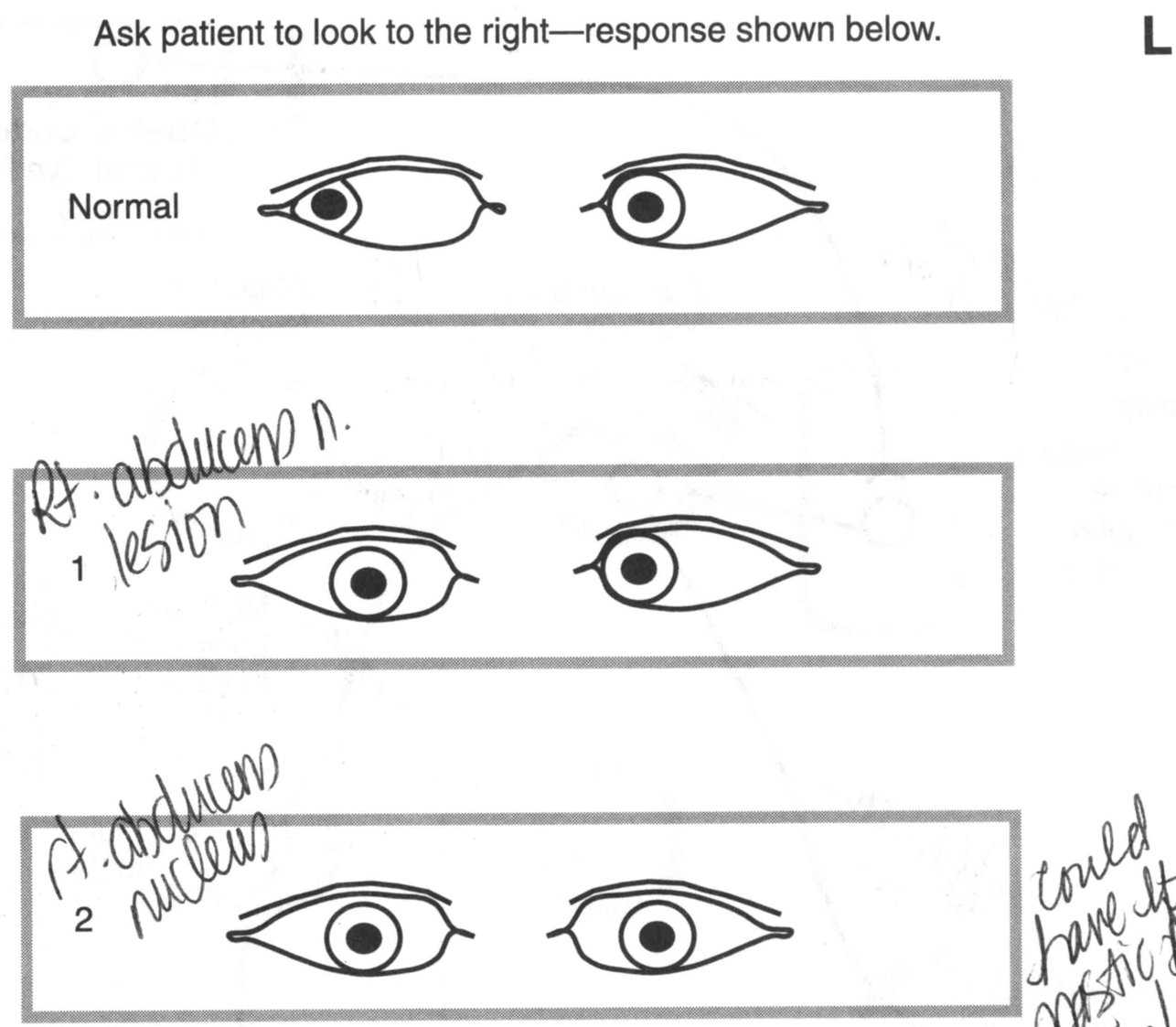

could have left spastic paralysis if limb b/c corticospinal tract also affected

Figure IV-5-11. Normal and Abnormal Responses to the Horizontal Gaze

Table IV-5-2. Normal and Abnormal Responses to the Horizontal Conjugate Gaze: Part 1

Lesion location	Symptoms (Results)
Right Abducens nerve, #1	Right eye cannot look right (abduct)
Right Abducens nucleus, #2	Neither eye can look right (lateral gaze paralysis)—may be slow drift left and right facial paralysis

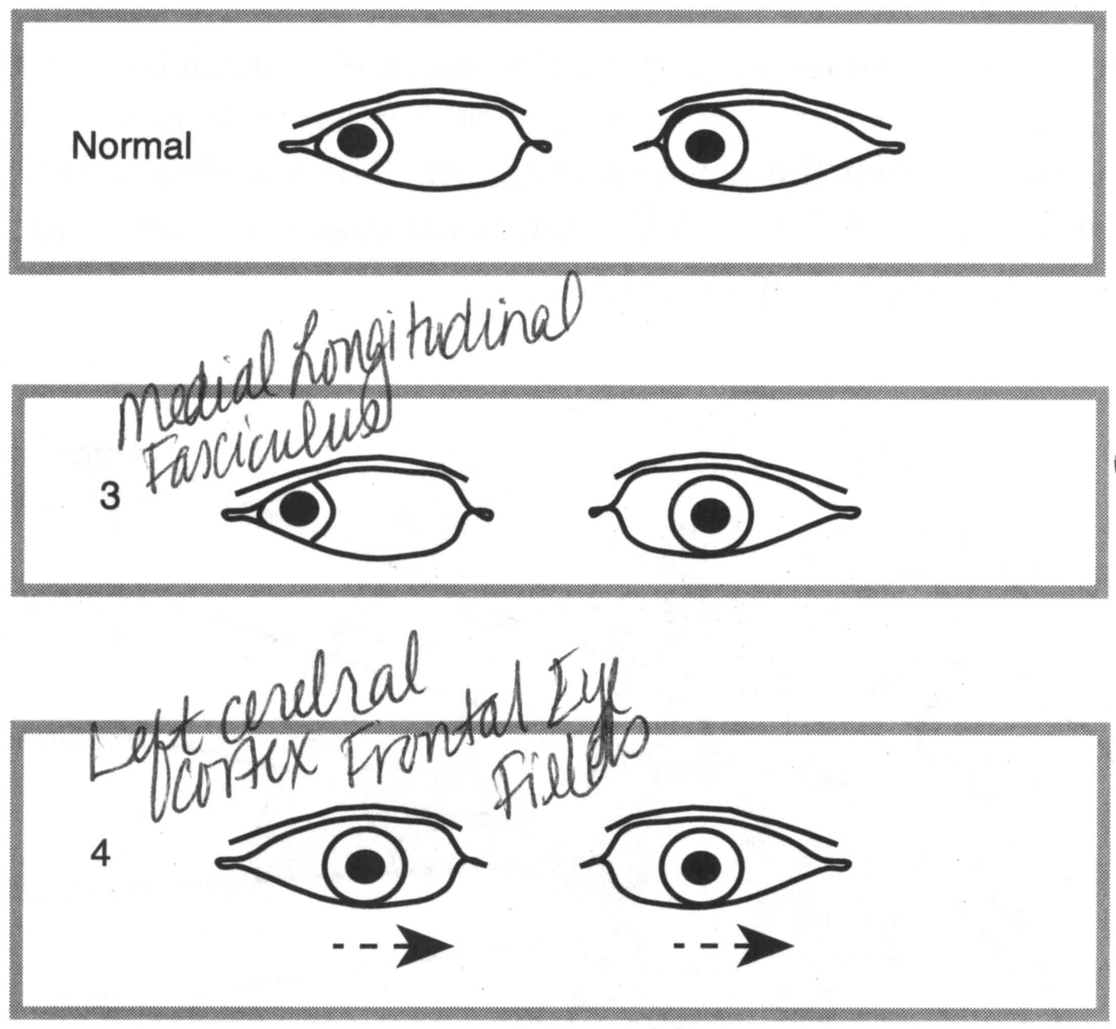

Figure IV-5-12. Normal and Abnormal Responses to the Horizontal Conjugate Gaze Test: Part 2

internuclear opthalmoplegia (always named on side of lesion) L, R
↳ usually associated w/ MS

rt. upper limb paralysis

w/ cortical lesion look at opp. side w/ lesion
w/ pontine lesion look at side w/ lesion

Table IV-5-3. Normal and Abnormal Responses to the Horizontal Gaze: Part 2

Location	Symptoms
Left MLF, #3	Left eye cannot look right; convergence intact; right eye exhibits nystagmus
Left cerebral cortex, #4	Neither eye can look right: but slow drift to left

BLOOD SUPPLY TO THE BRAIN STEM

Vertebral Artery

This artery is a branch of the subclavian that ascends through the foramina of the transverse processes of the upper six cervical vertebrae. It enters the posterior fossa by passing through the foramen magnum. The vertebral arteries continue up the ventral surface of the medulla and, at the caudal border of the pons, join to form the basilar artery (Fig IV-5-13).

Abbreviations

AICA = anterior inferior cerebellar artery

PICA = posterior inferior cerebellar artery

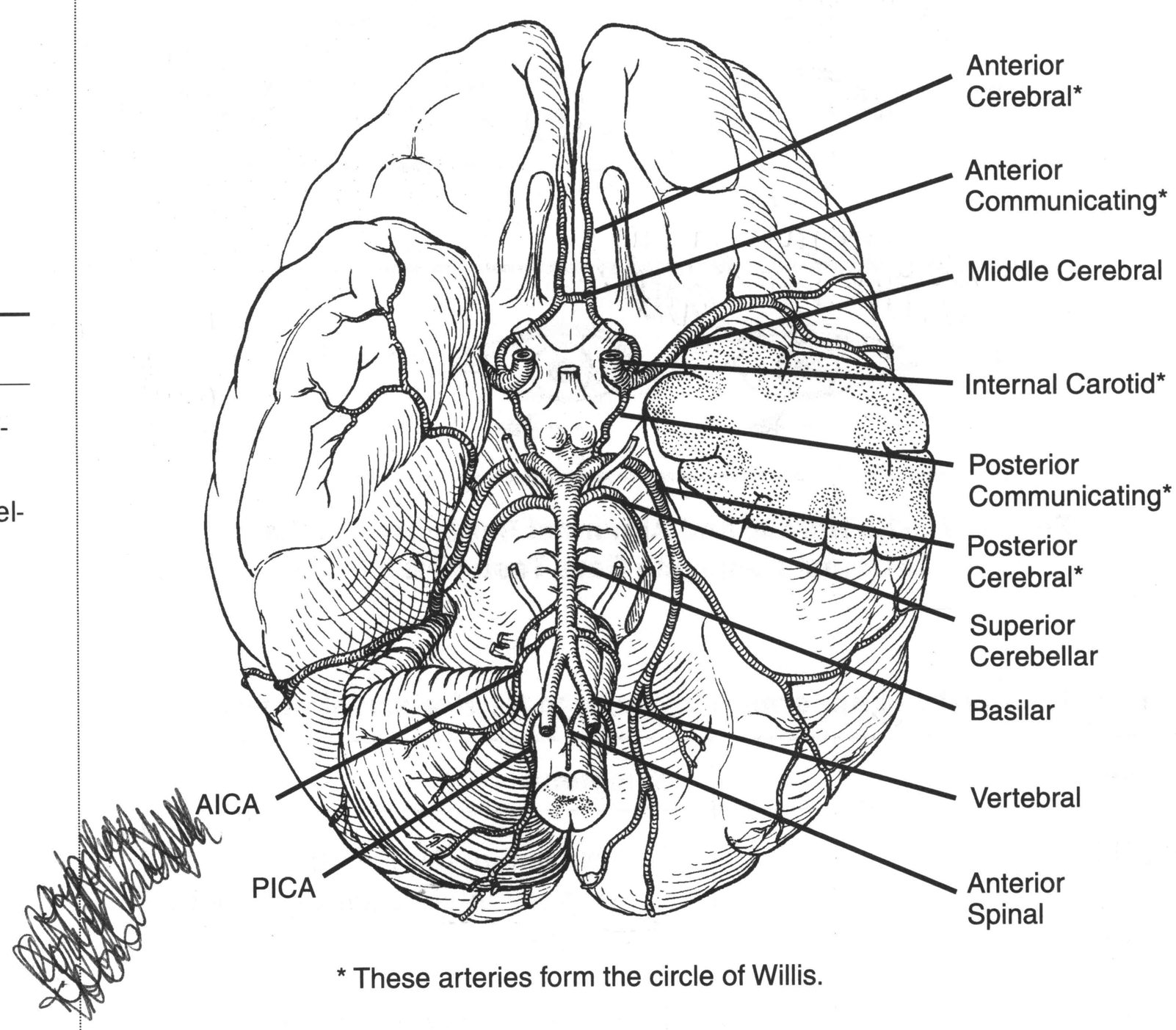

Figure IV-5-13. Arterial Supply of the Brain

Branches of the vertebral artery include: the anterior spinal artery, which supplies the ventrolateral two thirds of the cervical spinal cord and the ventrolateral part of the medulla; the posterior inferior cerebellar artery (PICA), which supplies the cerebellum and the dorsolateral part of the medulla.

Basilar Artery

The basilar artery is formed by the joining of the two vertebral arteries at the pontomedullary junction. It ascends along the ventral midline of the pons and terminates near the rostral border of the pons by dividing into the two posterior cerebral arteries.

Branches of the basilar artery include: The labyrinthine artery, which follows the course of the eighth cranial nerve and supplies the inner ear; the anterior inferior cerebellar artery, which supplies part of the pons and the anterior and inferior regions of the cerebellum; the superior cerebellar artery, which supplies part of the rostral pons and the superior region of the cerebellum; pontine branches, which supply much of the pons via paramedian and circumferential vessels.

At the rostral end of the midbrain, the basilar artery divides into a pair of posterior cerebral arteries. Paramedian and circumferential branches of the posterior cerebral artery supply the midbrain.

BRAIN STEM LESIONS

There are two keys to localizing brain stem lesions. First, it is uncommon to injure parts of the brain stem without involving one or more cranial nerves. The cranial nerve signs will localize the lesion to the midbrain (CN III or IV), upper pons (CN V), lower pons (CN VI, VII, or VIII), or upper medulla (CN IX, X, or XII). Second, if the lesion is in the brain stem, the cranial nerve deficits will be seen with a lesion to one or more of the descending or ascending long tracts (corticospinal, medial lemniscus, spinothalamic, descending hypothalamic fibers). Lesions in the brain stem to any of the long tracts except for the descending hypothalamic fibers will result in a contralateral deficit. A unilateral lesion to the descending hypothalamic fibers that results in Horner's syndrome is always seen ipsilateral to the side of the lesion.

Medial Medullary Syndrome

Medial medullary syndrome is most frequently the result of occlusion of the vertebral artery or the anterior spinal artery (Fig IV-5-14). Medial medullary syndrome presents with a lesion of the hypoglossal nerve as the cranial nerve sign and lesions to both the medial lemniscus and the corticospinal tract. Corticospinal tract lesions produce contralateral spastic hemiparesis of both limbs.

Medial lemniscus lesions produce a contralateral deficit of proprioception and touch, pressure, and vibratory sensations in the limbs and body.

Lesions of the hypoglossal nerve in the medulla produce an ipsilateral paralysis of half the tongue with atrophy. The tongue deviates toward the side of the lesion upon protrusion.

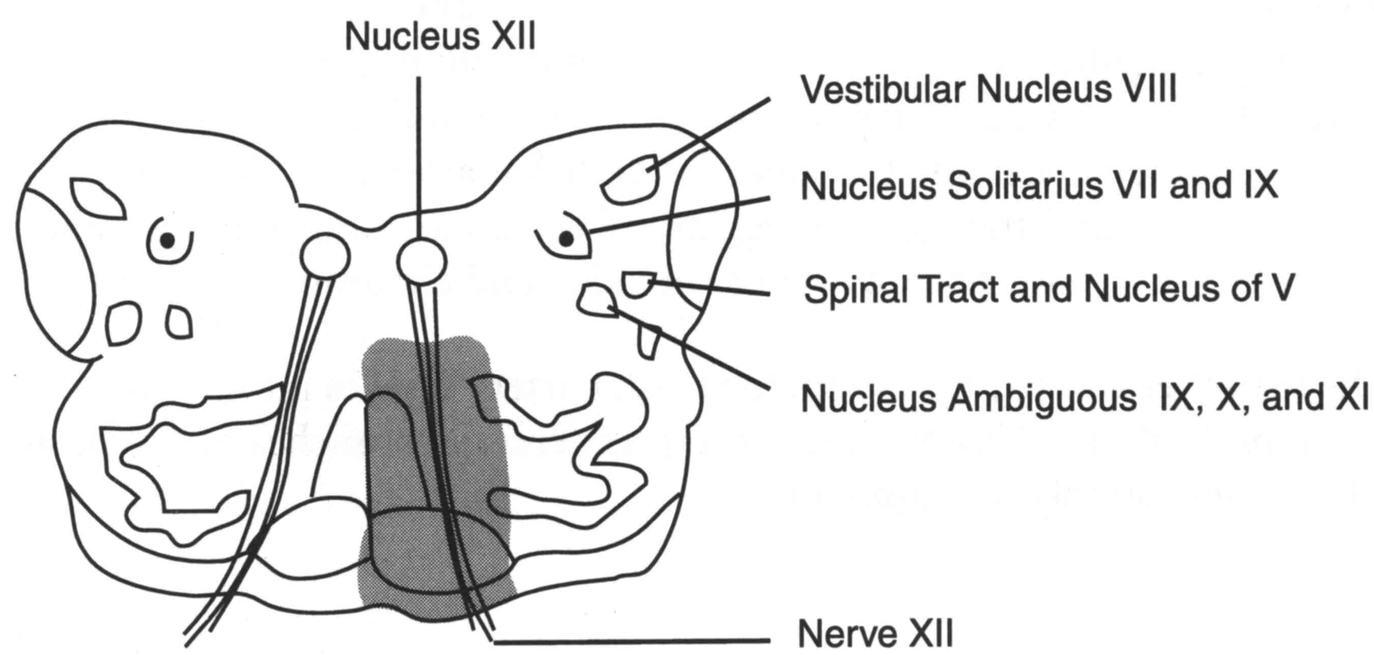

Figure IV-5-14. Medial Medullary Syndrome

Table IV-5-4. Medial Medullary Syndrome

Structure	Sign
Pyramid	Contralateral spastic hemiparesis of body
Medial lemniscus	Contralateral loss of position and vibration sense on the body
Fibers of XII	Tongue deviates to lesion side

Lateral Medullary (Wallenberg's) Syndrome (PICA syn.)

Lateral medullary syndrome results from occlusion of the PICA (Fig IV-5-15).

The cranial nerves or nuclei involved in the lesion are the vestibular or the cochlear parts of CN VIII, the glossopharyngeal and the vagus nerves, and the spinal nucleus or tract of V. The long tracts involved are the spinothalamic tract and the descending hypothalamic fibers.

Spinothalamic tract lesions produce a pain and temperature sensation deficit in the contralateral limbs and body.

Lesions of descending hypothalamic fibers produce an ipsilateral Horner's syndrome (i.e., miosis, ptosis, and anhidrosis).

Lesions of the vestibular nuclei and pathways may produce nystagmus, vertigo, nausea, and vomiting. If there is a vestibular nystagmus, the fast component will be away from the side of the lesion.

Lesions of the cochlear nucleus or auditory nerve produce an ipsilateral sensorineural hearing loss.

Lesions of the vagus nerves exiting the medulla may produce dysphagia (difficulty in swallowing) or hoarseness. The palate will droop on the affected side, and the uvula will deviate away from the side of the lesion.

Lesions of the glossopharyngeal nerve result in a diminished or absent gag reflex.

Lesions of the spinal tract and nucleus of the trigeminal nerve produce a loss of just pain and temperature sensations on the ipsilateral side of half the face. Touch sensations from the face and the corneal blink reflex will be intact. In lateral medullary syndrome, the pain and temperature losses are alternating; these sensations are lost from the face and scalp ipsilateral to the lesion but are lost from the contralateral limbs and trunk.

Taste sensations may be altered if the solitary nucleus is involved.

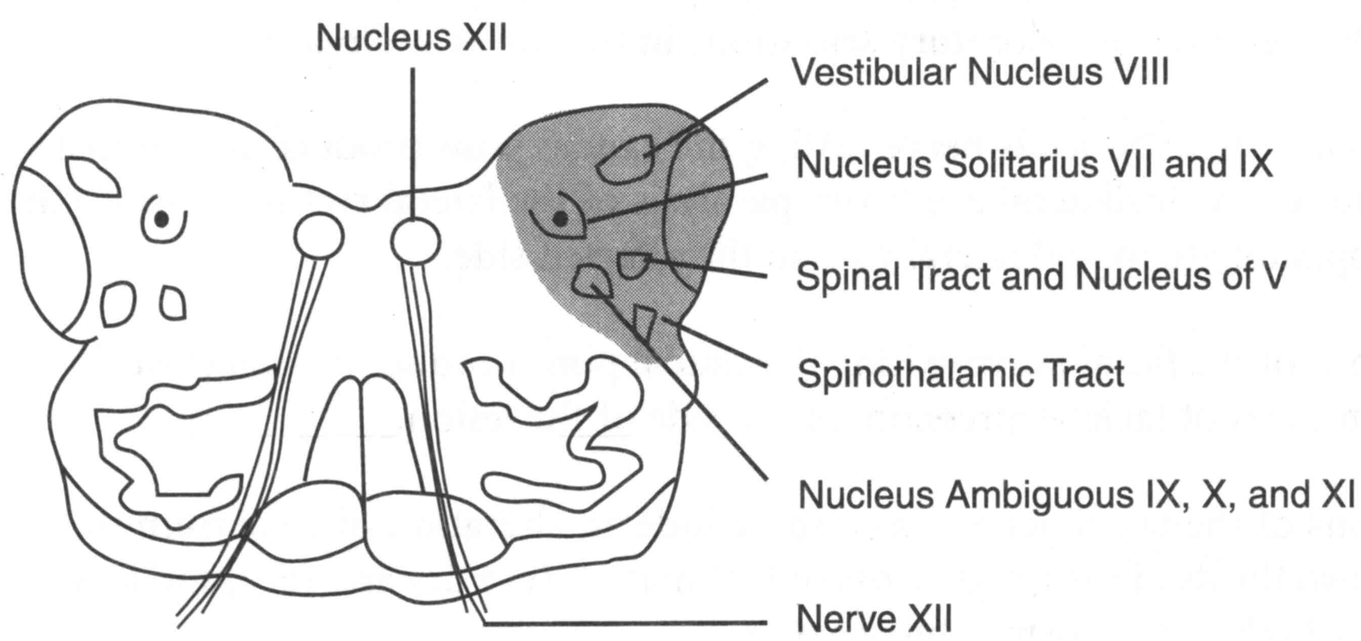

Figure IV-5-15. Lateral Medullary Syndrome (Wallenberg's Syndrome)

Table IV-5-5. Lateral Medullary Syndrome (Wallenberg's Syndrome)

Structure	Sign
Inferior cerebellar peduncle (ICP)	Ipsilateral limb ataxia
Spinal V	Ipsilateral pain and temperature loss—face
Spinothalamic tract	Contralateral pain and temperature loss—body
Vestibular nuclei	Vomiting, vertigo, nystagmus—away from lesion side
Descending hypothalamics	Horner's syndrome (always ipsilateral)
Nucleus ambiguus (fibers of IX, X)	Ipsilateral paralysis of the vocal cord, dysphagia, palate droop

occulomotor nerve damage- pupil dilate (unequal size) + ptosis

Medial Pontine Syndrome

Medial pontine syndrome results from occlusion of paramedian branches of the basilar artery (Fig IV-5-16).

At a minimum, this lesion affects the exiting fibers of the abducens nerve and the corticospinal tract. The medial lemniscus may be affected if the lesion is deeper into the pons, and the facial nerve may be affected if the lesion extends laterally.

The long tract signs will be the same as in medial medullary syndrome, involving the corticospinal and medial lemniscus, but the abducens nerve and the facial nerve lesions localize the lesion to the caudal pons.

Corticospinal tract lesions produce contralateral spastic hemiparesis of both limbs.

Medial lemniscus lesions produce a contralateral deficit of proprioception and touch, pressure, and vibratory sensations in the limbs and body.

Lesions of the abducens nerve exiting the caudal pons produce an internal strabismus of the ipsilateral eye (from paralysis of the lateral rectus). This results in diplopia on attempted lateral gaze to the affected side.

Lesions of the facial nerve exiting the caudal pons produce complete weakness of the muscles of facial expression on the side of the lesion.

Lesions of the facial nerve may also include an alteration of taste from the anterior two thirds of the tongue, loss of lacrimation (eye dry and red), and loss of the motor limb of the corneal blink reflex.

If a lesion extends dorsally to include the abducens nucleus (which includes the horizontal gaze center in the PPRF), there may be a lateral gaze paralysis in which both eyes are forcefully directed to the side contralateral to the lesion.

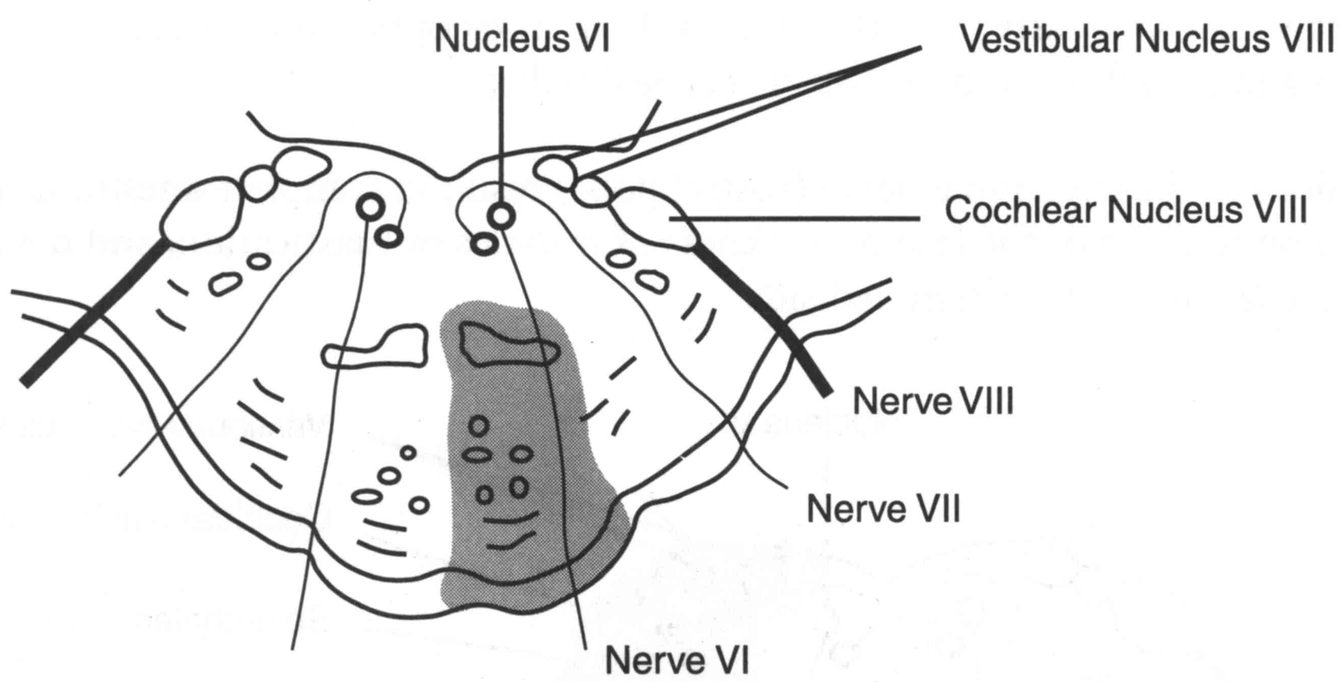

Figure IV-5-16. Medial Pontine Syndrome

Table IV-5-6. Medial Pontine Syndrome

Structure	Sign
CST	Contralateral spastic hemiparesis of the body
Mediallemniscus	Contralateral loss of position and vibration on the body
Fibers of VI	Medial strabismus b/c knock out med. rectus

Lateral Pontine Syndrome

Lesions of the dorsolateral pons usually result from occlusion of the anterior inferior cerebellar artery (caudal pons) or superior cerebellar artery (rostral pons). The long tracts involved will be the same as in lateral medullary syndrome, the spinothalamic tract and the descending hypothalamic fibers. The cranial nerves involved will be the facial and vestibulocochlear in the caudal pons, the trigeminal nerve in the rostral pons, and the spinal nucleus and tract of V in both lesions (Fig IV-5-17).

Spinothalamic tract lesions produce a pain and temperature sensation deficit in the contralateral limbs and body.

Lesions of descending hypothalamic fibers produce an ipsilateral Horner's syndrome (i.e., miosis, ptosis, and anhidrosis).

Lesions of the vestibular nuclei and pathways (caudal pons) produce nystagmus, vertigo, nausea, and vomiting. Again, the fast phase of the nystagmus will be away from the side of the lesion. Lesions of the cochlear nucleus or auditory nerve produce an ipsilateral sensorineural hearing loss.

Lesions of the spinal tract and nucleus of the trigeminal nerve result only in a loss of pain and temperature sensations on the ipsilateral side of half the face.

Lesions of the facial nerve and associated structures produce ipsilateral facial paralysis, loss of taste from the anterior two thirds of the tongue, loss of lacrimation and salivation, and loss of the corneal reflex.

Lesions of the trigeminal nerve (rostral pons) result in complete anesthesia of the face on the side of the lesion, weakness of muscles of mastication, and deviation of the jaw toward the lesioned side.

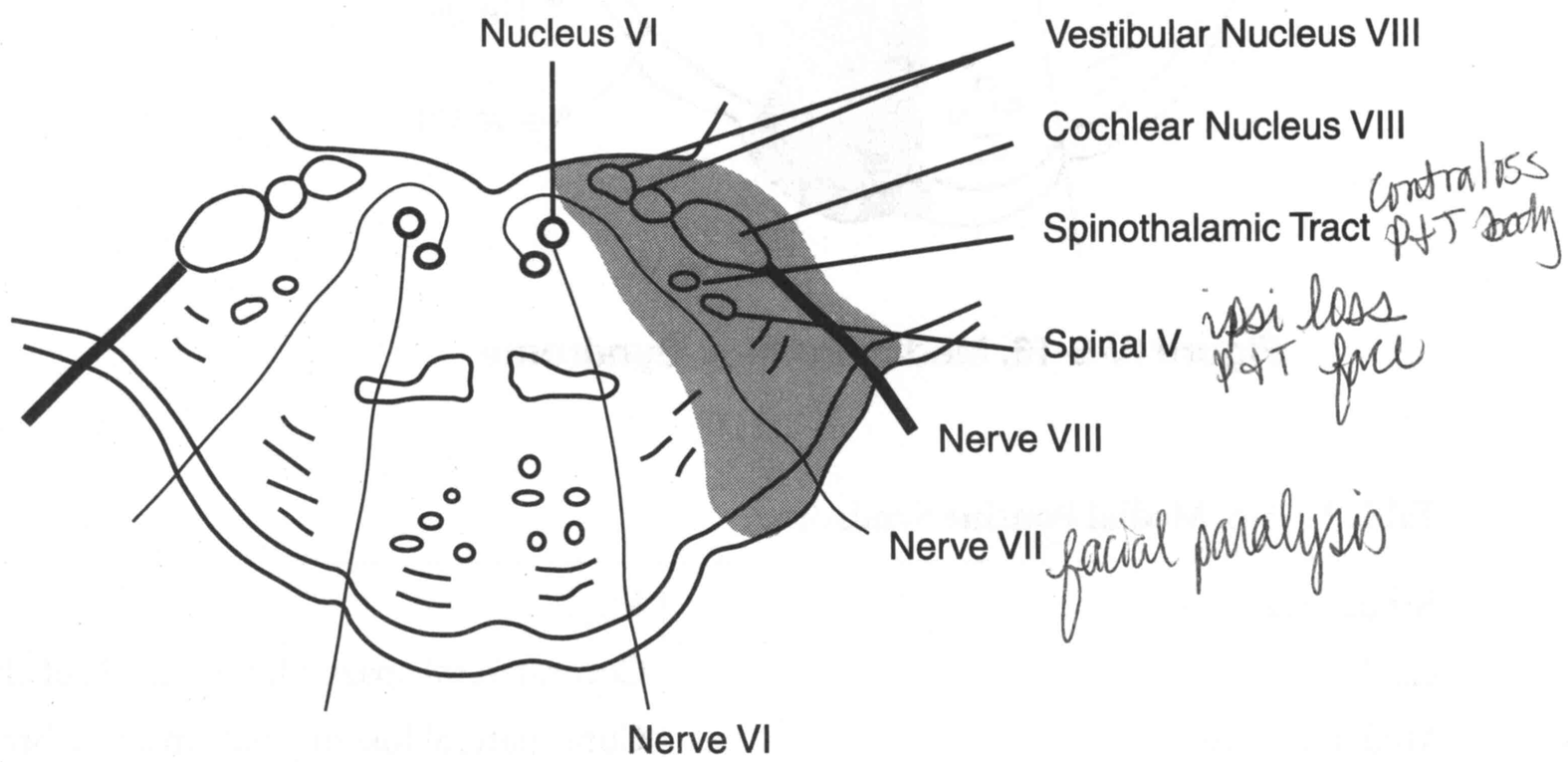

Figure IV-5-17. Lateral Pontine Syndrome

Table IV-5-7. Lateral Pontine Syndrome

Structure	Sign
ICP	Ipsilateral limb ataxia
Spinal V	Ipsilateral pain and temperature loss–face
Spinothalamic	Contralateral pain and temperature loss–body
Vestibular nuclei	Vomiting, vertigo, nystagmus–away from lesion side
Descending hypothalamics	Horner's syndrome (Ipsilateral)
Fibers of VII	Ipsilateral facial paralysis
Fibers of VIII	Hearing loss

Pontocerebellar Angle Syndrome

Pontocerebellar angle syndrome is usually caused by an acoustic neuroma (schwannoma) of CN VIII. This is a slow-growing tumor, which originates from Schwann cells in the vestibular nerve (or less commonly the auditory nerve). As the tumor grows, it exerts pressure on the lateral part of the caudal pons where CN VII emerges and may expand anteriorly to compress the fifth nerve. The cranial nerve deficits seen together localize the lesion to the brain stem, but the absence of long tract signs indicates that the lesion must be outside of the brain stem.

Medial Midbrain (Weber's) Syndrome

ventral midbrain syndrome

Medial midbrain (Weber's) syndrome results from occlusion of branches of the posterior cerebral artery (Figs IV-5-18 and IV-5-19).

In medial midbrain syndrome, exiting fibers of CN III are affected, along with corticobulbar and corticobulbar fibers in the medial aspect of the cerebral peduncle. Third nerve lesions result in a ptosis, mydriasis (dilated pupil), and an external strabismus. As with any brain stem lesion affecting corticospinal fibers, accommodation and convergence will also be affected. Corticospinal tract lesions produce contralateral spastic hemiparesis of both limbs. The involvement of the corticobulbar fibers results in a contralateral lower face weakness seen as a drooping of the corner of the mouth. The patient will be able to shut the eye (blink reflex is intact) and wrinkle the forehead.

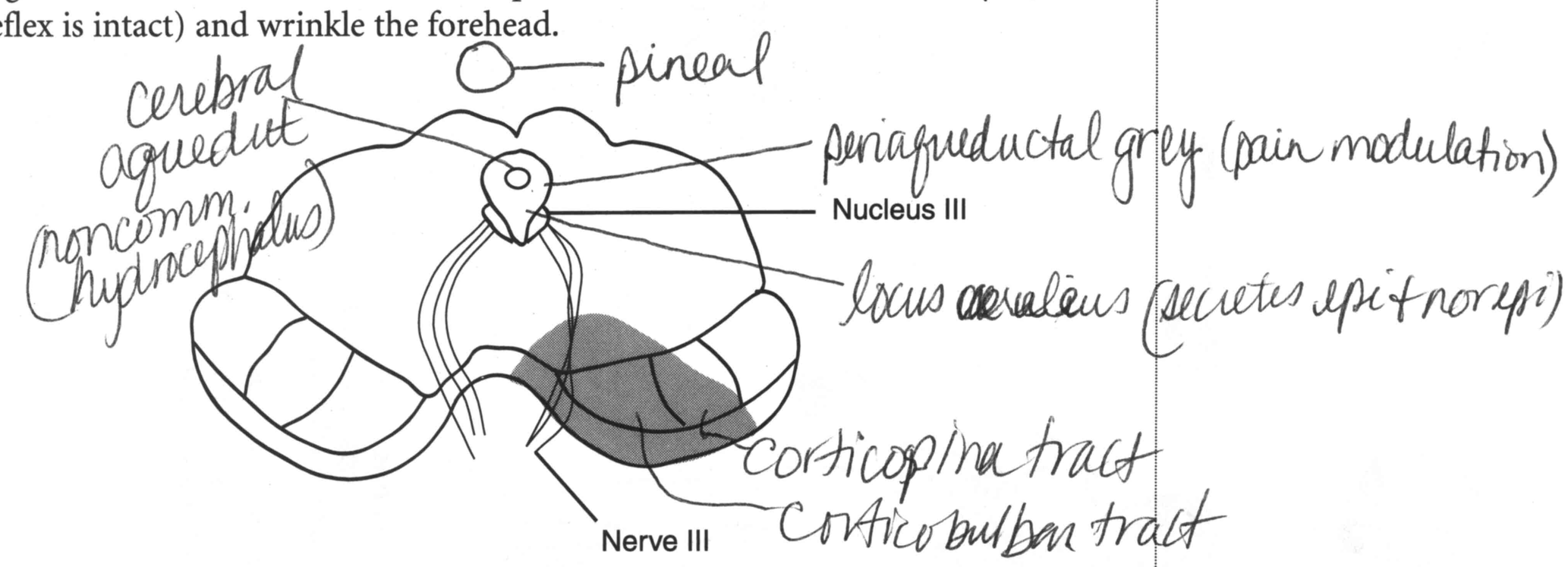

Figure IV-5-18. Ventral Midbrain Syndrome (Weber's Syndrome)

Structure	Sign
CST	Contralateral spastic hemiparesis, mostly upper limb
Corticobulbar tract	Contralateral spastic hemiparesis of lower half of FACE corticobulbar
Fibers of III	Ipsilateral oculomotor palsy 1. Dilated pupil 2. Ptosis 3. Eye pointing down and out (Lateral strabismus)

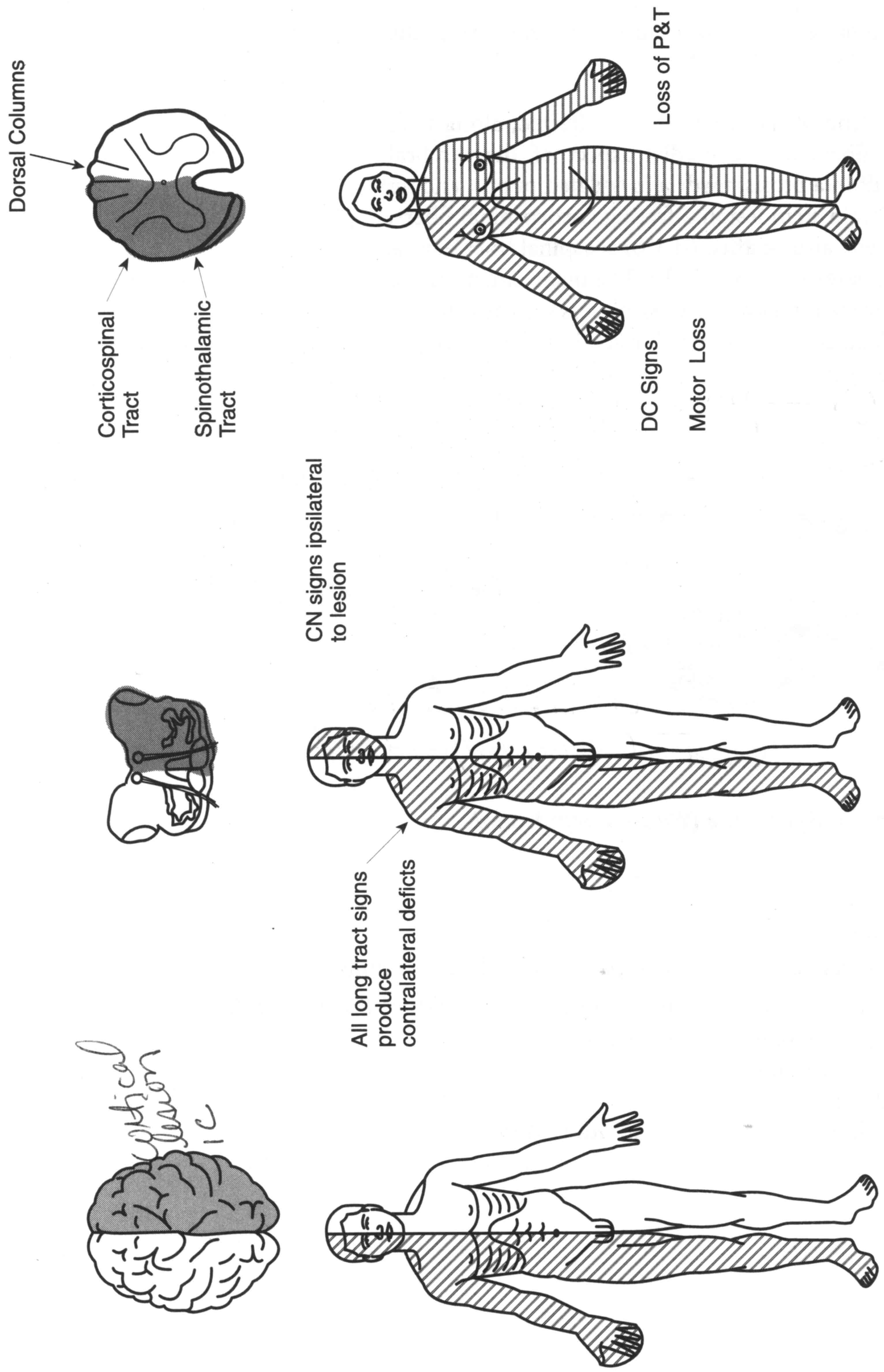

Figure IV-5-19. Strategy for the Study of Lesions

Parinaud's Syndrome

Parinaud's syndrome usually occurs as a result of a pineal tumor compressing the superior colliculi. The most common sign is paralysis of upward or vertical gaze, combined with bilateral pupillary abnormalities (e.g., slightly dilated pupils, which may show an impaired light or accommodation reaction) and signs of elevated intracranial pressure. Compression of the cerebral aqueduct can result in noncommunicating hydrocephalus.

Clinical Correlate

Neurons in both the raphe and locus coeruleus degenerate in Alzheimer's disease.

RETICULAR FORMATION

The reticular formation is located in the brain stem and functions to coordinate and integrate the actions of different parts of the CNS. It plays an important role in the regulation of muscle and reflex activity and control of respiration, cardiovascular responses, behavioral arousal, and sleep.

Reticular Nuclei

Raphe Nuclei

The raphe nuclei are a narrow column of cells in the midline of the brain stem, extending from the medulla to the midbrain. Cells in some of the raphe nuclei (e.g., the dorsal raphe nucleus) synthesize serotonin (5-hydroxytryptamine [5-HT]) from L-tryptophan and project to vast areas of the CNS. They play a role in mood, aggression, and the induction of non–rapid-eye-movement (REM) sleep.

Locus Caeruleus

Cells in the locus caeruleus synthesize norepinephrine and send projections to most brain areas involved in the control of cortical activation (arousal). Decreased levels of norepinephrine are evident in REM (paradoxic) sleep.

Periaqueductal Gray

The periaqueductal (central) gray is a collection of nuclei surrounding the cerebral aqueduct in the midbrain. Opioid receptors are present on many periaqueductal gray cells, the projections from which descend to modulate pain at the level of the dorsal horn of the spinal cord.

The Cerebellum

6

GENERAL FEATURES

The cerebellum is derived from the metencephalon and is located dorsal to the pons and the medulla. The fourth ventricle is found between the cerebellum and the dorsal aspect of the pons. The cerebellum functions in the planning and fine-tuning of skeletal muscle contractions. It performs these tasks by comparing an intended with an actual performance.

The cerebellum consists of a midline vermis and two lateral cerebellar hemispheres. The cerebellar cortex consists of multiple parallel folds that are referred to as folia. The cerebellar cortex contains several maps of the skeletal muscles in the body (Fig IV-6-1).

The topographic arrangement of these maps indicates that the vermis controls the axial and proximal musculature of the limbs, the intermediate part of the hemisphere controls distal musculature, and the lateral part of the hemisphere is involved in motor planning.

The flocculonodular lobe is involved in control of balance and eye movements.

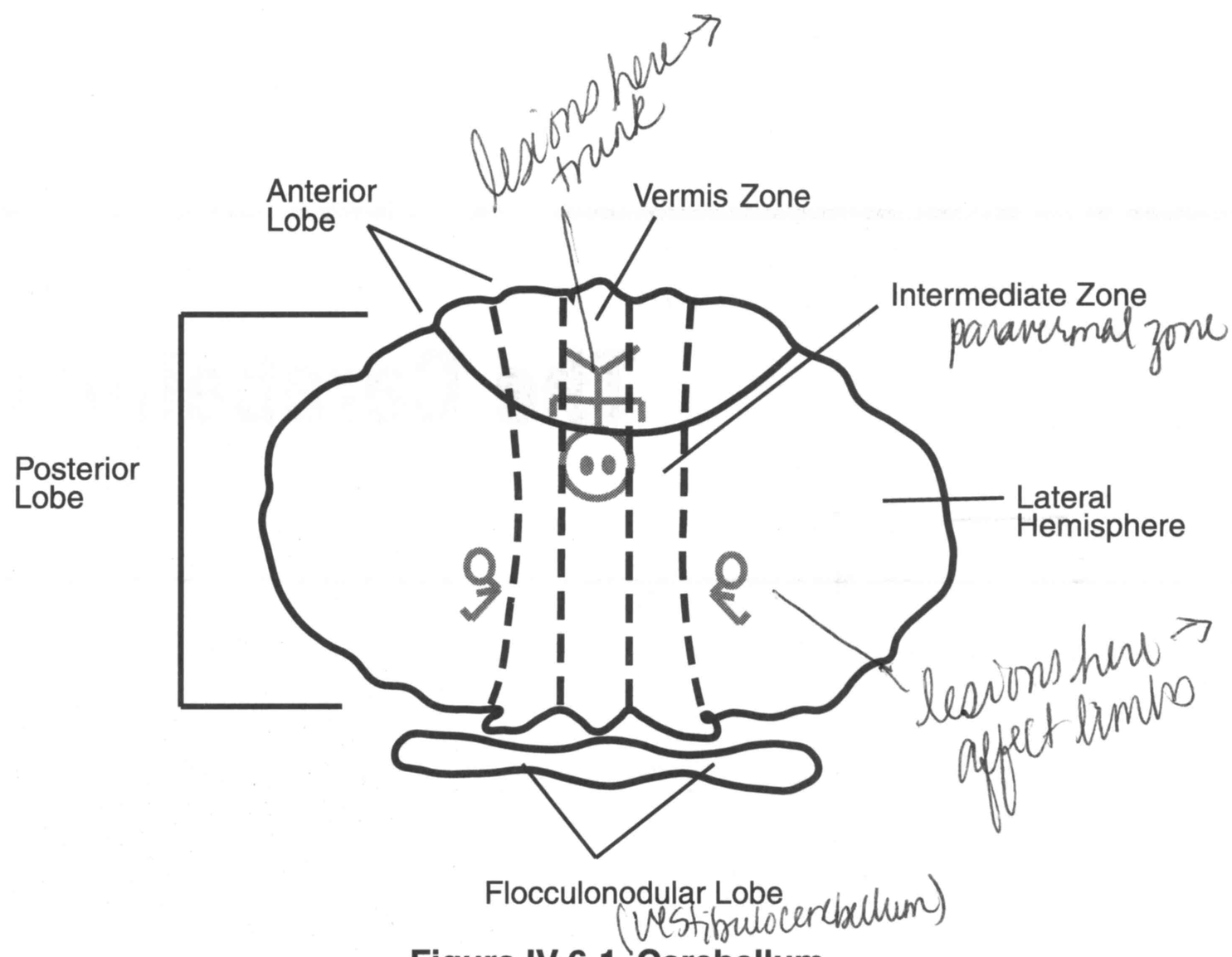

Figure IV-6-1. Cerebellum

Table IV-6-1. Cerebellum

Region	Function	Principle Input
Vermis and intermediate zones	Ongoing motor execution	Spinal cord
Hemisphere	Planning	Cerebral cortex
Flocculonodular lobe	Balance and eye movements	Vestibular nuclei (VIII)

Major input to the cerebellum travels in the inferior cerebellar peduncle (ICP) and middle cerebellar peduncle (MCP). Major outflow from the cerebellum travels in the superior cerebellar peduncle (SCP) (Table IV-6-1).

Table IV-6-2. Major Afferents to the Cerebellum

Name	Tract	Enter Cerebellum Via	Target and Function
Mossy fibers	Vestibulocerebellar Spinocerebellar (Cortico)pontocerebellar	ICP ICP and SCP MCP	Excitatory terminals on granule cells
Climbing fibers inf. olivary nucleus	Olivocerebellar	ICP	Excitatory terminals on Purkinje cells

ICP = inferior cerebellar peduncle; MCP = middle cerebellar peduncle; SCP = superior cerebellar peduncle

CEREBELLAR CYTOARCHITECTURE

All afferent and efferent projections of the cerebellum traverse the ICP, MCP, or SCP. Most afferent input enters the cerebellum in the ICP and MCP; most efferent outflow leaves in the SCP (Fig IV-6-2 and Table IV-6-2).

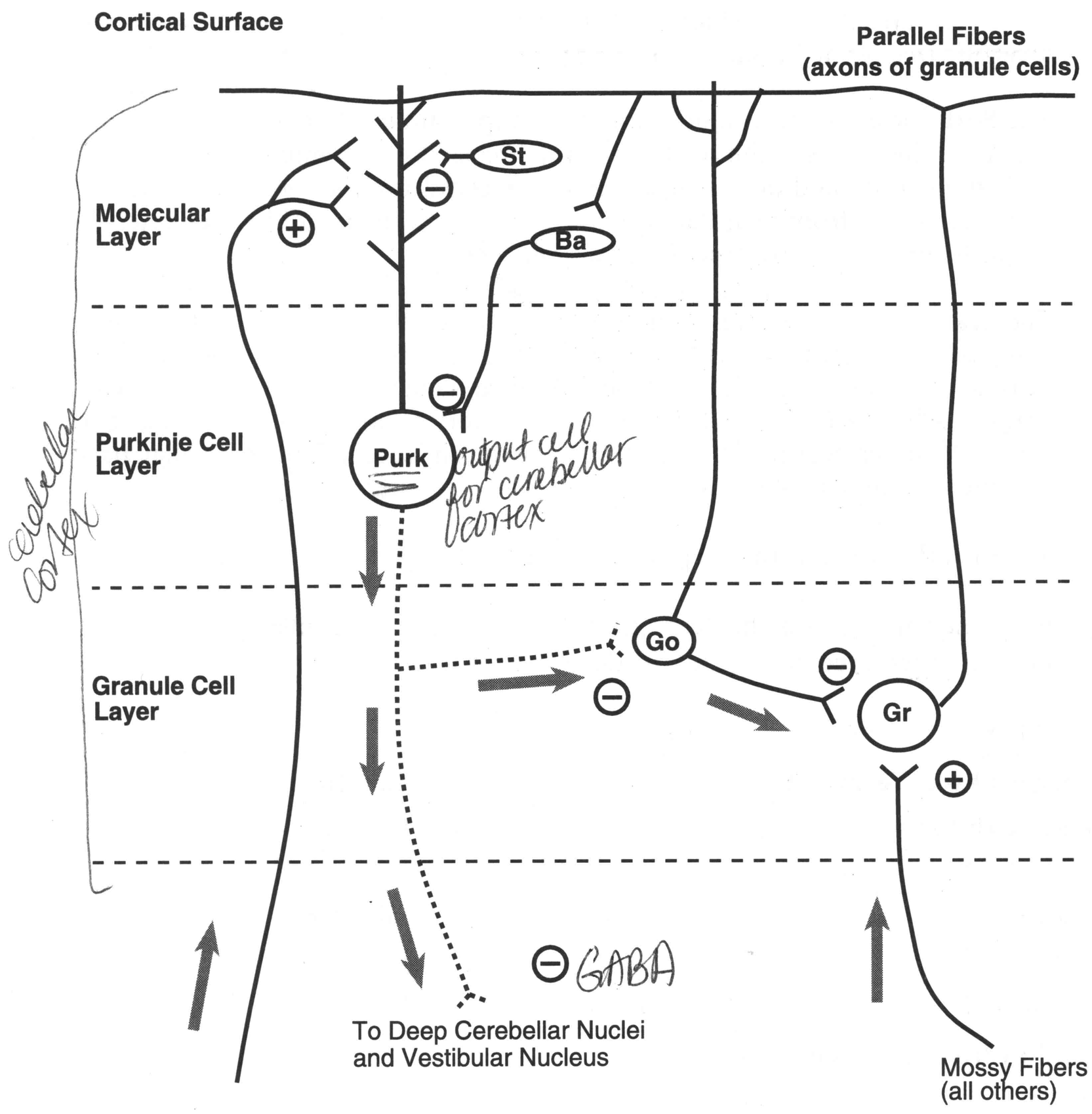

Purk = Purkinje cell
Gr = Granule
Go = Golgi cell
Ba = Basket cell
St = Stellate cell

** Of the neurons in the cerebellar cortex, the granule cells are the only excitatory neuron.

Figure IV-6-2. Cerebellar Cytoarchitecture

Internally, the cerebellum consists of an outer cortex and an inner medulla.

The three cell layers of the cortex are the molecular layer, the Purkinje layer, and the granule cell layer.

The **molecular layer** is the outer layer and is made up of basket and stellate cells as well as parallel fibers, which are the axons of the granule cells. The extensive dendritic tree of the Purkinje cell extends into the molecular layer.

The **Purkinje layer** is the middle and most important layer of the cerebellar cortex. All of the inputs to the cerebellum are directed toward influencing the firing of Purkinje cells, and only axons of Purkinje cells leave the cerebellar cortex. A single axon exits from each Purkinje cell and projects to one of the deep cerebellar nuclei or to vestibular nuclei of the brain stem.

The **granule cell layer** is the innermost layer of cerebellar cortex and contains Golgi cells, granule cells, and glomeruli. Each glomerulus is surrounded by a glial capsule and contains a granule cell and axons of Golgi cells, which synapse with granule cells. The granule cell is the only excitatory neuron within the cerebellar cortex. All other neurons in the cerebellar cortex, including Purkinje, Golgi, basket, and stellate cells, are inhibitory.

The **medulla** contains the deep cerebellar nuclei.

From medial to lateral, the deep cerebellar nuclei in the medulla are the fastigial nucleus, interposed nuclei, and the dentate nucleus.

Table IV-6-3. Cerebellum: Cell Types

Name	Target (Axon Termination)	Transmitter	Function
Purkinje cell	Deep cerebellar nuclei	GABA	Inhibitory **
Granule cell	Purkinje cell	Glutamate	Excitatory
Stellate cell	Purkinje cell	GABA	Inhibitory
Basket cell	Purkinje cell	GABA	Inhibitory
Golgi cell	Granule cell	GABA	Inhibitory

**Purkinje cells are the only outflow from the cerebellar cortex.

Two kinds of excitatory input enter the cerebellum in the form of climbing fibers and mossy fibers. Both types influence the firing of deep cerebellar nuclei by axon collaterals.

Climbing fibers originate exclusively from the inferior olivary complex of nuclei on the contralateral side of the medulla. Climbing fibers provide a direct powerful monosynaptic excitatory input to Purkinje cells.

Mossy fibers represent the axons from all other sources of cerebellar input. Mossy fibers provide an indirect, more diffuse excitatory input to Purkinje cells.

All mossy fibers exert an excitatory effect on **granule cells.** Each granule cell sends its axon into the molecular layer, where it gives off collaterals at a 90-degree angle that run parallel to the cortical surface (i.e., parallel fibers). These granule cell axons stimulate the apical dendrites of the Purkinje cells. Golgi cells receive excitatory input from mossy fibers and from the parallel fibers of the granule cells. The Golgi cell in turn inhibits the granule cell, which activated it in the first place.

The **basket** and **stellate cells**, which also receive excitatory input from parallel fibers of granule cells, inhibit Purkinje cells.

CIRCUITRY

The basic cerebellar circuits begin with Purkinje cells that receive excitatory input directly from climbing fibers and from parallel fibers of granule cells.

Purkinje cell axons project to and inhibit the deep cerebellar nuclei or the vestibular nuclei in an orderly fashion (Fig IV-6-3).

- Purkinje cells in the flocculonodular lobe project to the lateral vestibular nucleus.
- Purkinje cells' in the vermis project to the fastigial nuclei.
- Purkinje cells in the intermediate hemisphere primarily project to the interposed (globose and emboliform) nuclei.
- Purkinje cells in the lateral cerebellar hemisphere project to the dentate nucleus.

t. cerebellar affect A. muscles

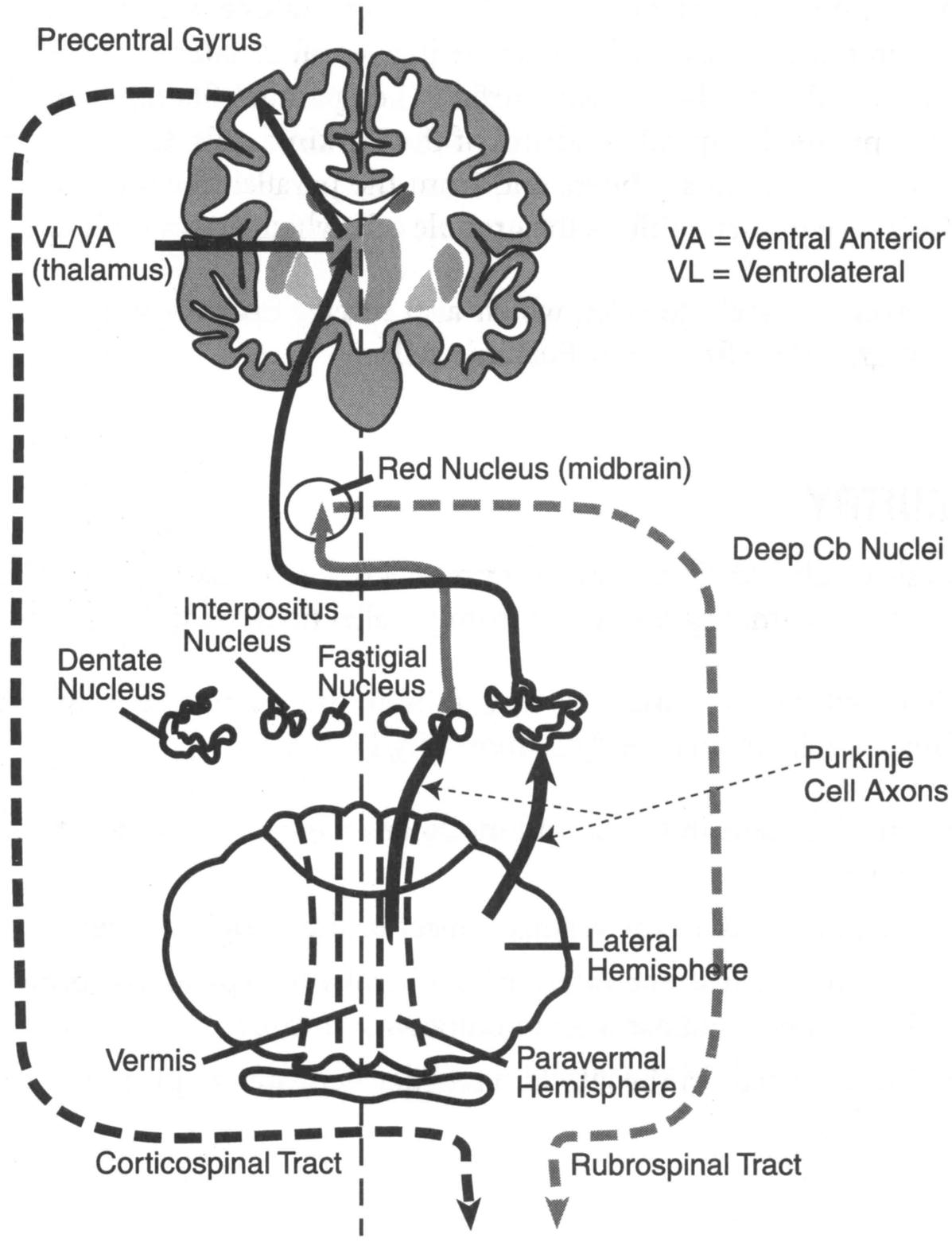

Figure IV-6-3. Cerebellar Efferents

Table IV-6-4. Major Efferents from the Cerebellum

Cerebellar Areas	Deep Cerebellar Nucleus	Efferents to:	Function
Vestibulocerebellum (Flocculo nodular lobe)	Fastigial nucleus	Vestibular nucleus	Elicit positional changes of eyes and trunk in response to movement of the head
Spinocerebellum (Intermediate hemisphere)	Interpositus nucleus	Red nucleus Reticular formation	Influence LMNs via the reticulospinal and rubrospinal tracts to adjust posture and effect movement
Pontocerebellum (Lateral hemispheres)	Dentate nucleus	Thalamus, then Cortex	Influence on LMNs via the corticospinal tract, which effect voluntary movements, especially sequence and precision

Efferents from the deep cerebellar nuclei leave mainly through the SCP and influence all upper motoneurons. In particular, axons from the dentate and interposed nuclei leave through the SCP, cross the midline, and terminate in the ventrolateral (VL) nucleus of the thalamus.

The VL nucleus of the thalamus projects to primary motor cortex and influences the firing of corticospinal and corticobulbar neurons.

Axons from other deep cerebellar nuclei influence upper motoneurons in the red nucleus and in the reticular formation and vestibular nuclei.

Cerebellar Lesions

The hallmark of cerebellar dysfunction is a tremor with intended movement without paralysis or paresis. Symptoms associated with cerebellar lesions are expressed ipsilaterally because the major outflow of the cerebellum projects to the contralateral motor cortex, and then the corticospinal fibers cross on their way to the spinal cord. Thus, unilateral lesions of the cerebellum will result in a patient falling toward the side of the lesion.

Lesions to the Vermal Region usually due to alcohol abuse

Vermal lesions result in difficulty maintaining posture, gait, or balance (an ataxic gait). Patients with vermal damage may be differentiated from those with a lesion of the dorsal columns by the Romberg sign. In cerebellar lesions, patients will sway or lose their balance with their eyes open; in dorsal column lesions, patients sway with their eyes closed.

Lesions that Include the Hemisphere

Lesions that include the hemisphere produce a number of dysfunctions, mostly involving distal musculature.

An intention tremor is seen when voluntary movements are performed. For example, if a patient with a cerebellar lesion is asked to pick up a penny, a slight tremor of the fingers is evident and increases as the penny is approached. The tremor is barely noticeable or is absent at rest.

Dysmetria is the inability to stop a movement at the proper place. The patient has difficulty performing the finger to nose test.

Dysdiadochokinesia (adiadochokinesia) is the reduced ability to perform alternating movements, such as pronation and supination of the forearm, at a moderately quick pace.

Scanning dysarthria is caused by asynergy of the muscles responsible for speech. In scanning dysarthria, patients divide words into syllables, thereby disrupting the melody of speech.

Clinical Correlate

Anterior vermis lesions are usually the result of degeneration from alcohol abuse and are present with gait ataxia. Posterior vermis lesions result from medulloblastomas or ependymomas and present with truncal ataxia. +nystagmus bc you can involve flocconodular lobe

Gaze dysfunction occurs when the eyes try to fix on a point: They may pass it or stop too soon and then oscillate a few times before they settle on the target. A nystagmus may be present, particularly with acute cerebellar damage. The nystagmus is often coarse, with the fast component usually directed toward the involved cerebellar hemisphere.

Hypotonia usually occurs with an acute cerebellar insult that includes the deep cerebellar nuclei. The muscles feel flabby on palpation, and deep tendon reflexes are usually diminished.

Visual Pathways

7

EYEBALL AND OPTIC NERVE

Light must pass through the cornea, aqueous humor, pupil, lens, and vitreous humor before reaching the retina (Fig IV-7-1). It must then pass through the layers of the retina to reach the photoreceptive layer of rods and cones. The outer segments of rods and cones transduce light energy from photons into membrane potentials. Photopigments in rods and cones absorb photons, and this causes a conformational change in the molecular structure of these pigments. This molecular alteration causes sodium channels to close, a hyperpolarization of the membranes of the rods and cones, and a reduction in the amount of neurotransmitter released. Thus, rods and cones release less neurotransmitter in the light and more neurotransmitter in the dark. Rods and cones have synaptic contacts on bipolar cells that project to ganglion cells (Fig IV-7-2). Axons from the ganglion cells converge at the optic disc to form the optic nerve, which enters the cranial cavity through the optic foramen. At the optic disc, these axons acquire a myelin sheath from the oligodendrocytes of the CNS.

Clinical Correlate

Vitamin A, necessary for retinal transduction, cannot be synthesized by humans. A dietary deficiency of vitamin A causes visual impairment resulting in night blindness.

hyperoptic - correct w/ convergent lens
myopic - correct w/ divergent lens

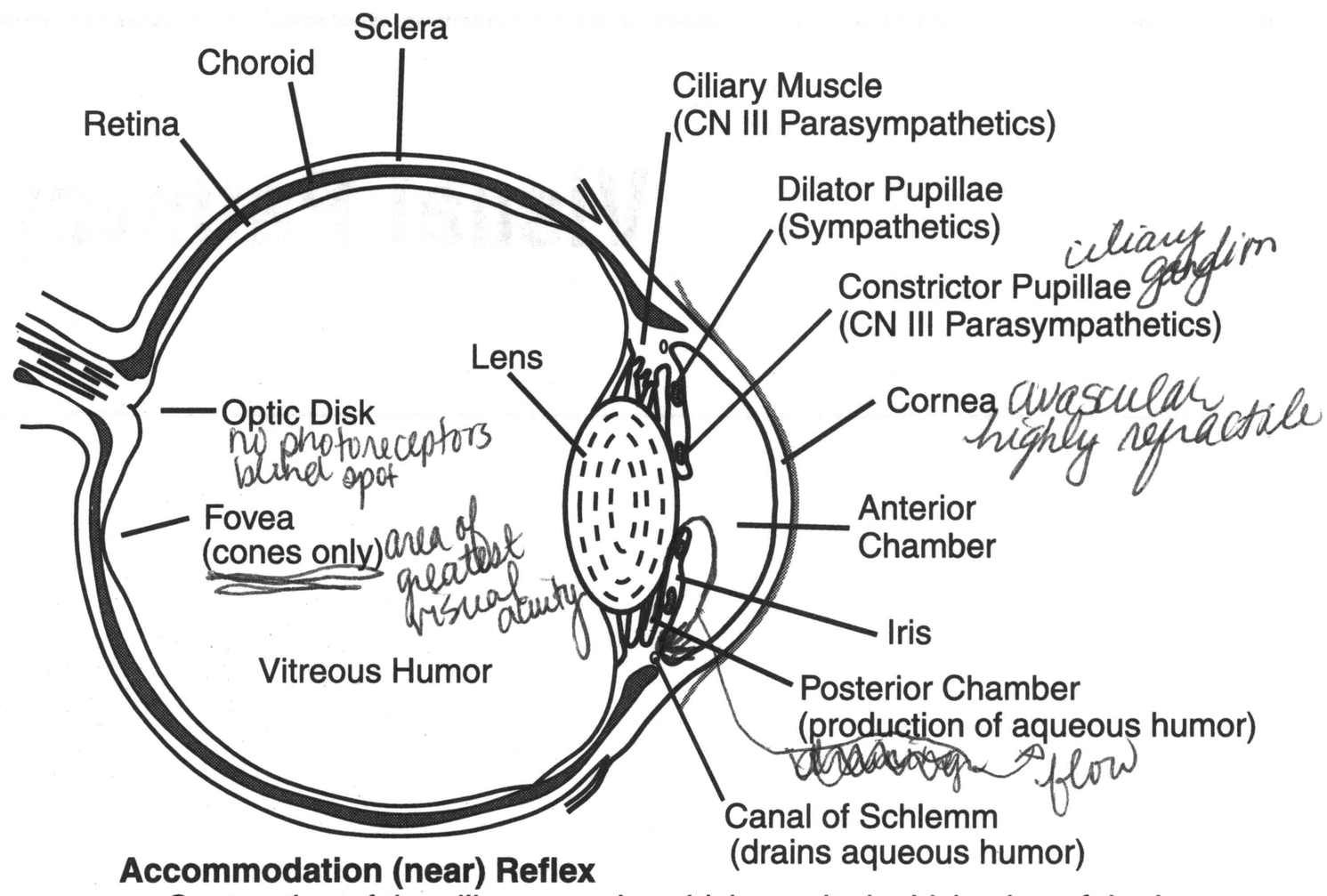

Accommodation (near) Reflex

- Contraction of the ciliary muscle, which results in thickening of the lens
- Contraction of the pupillae muscle
- Convergence

Figure IV-7-1. The Eyeball

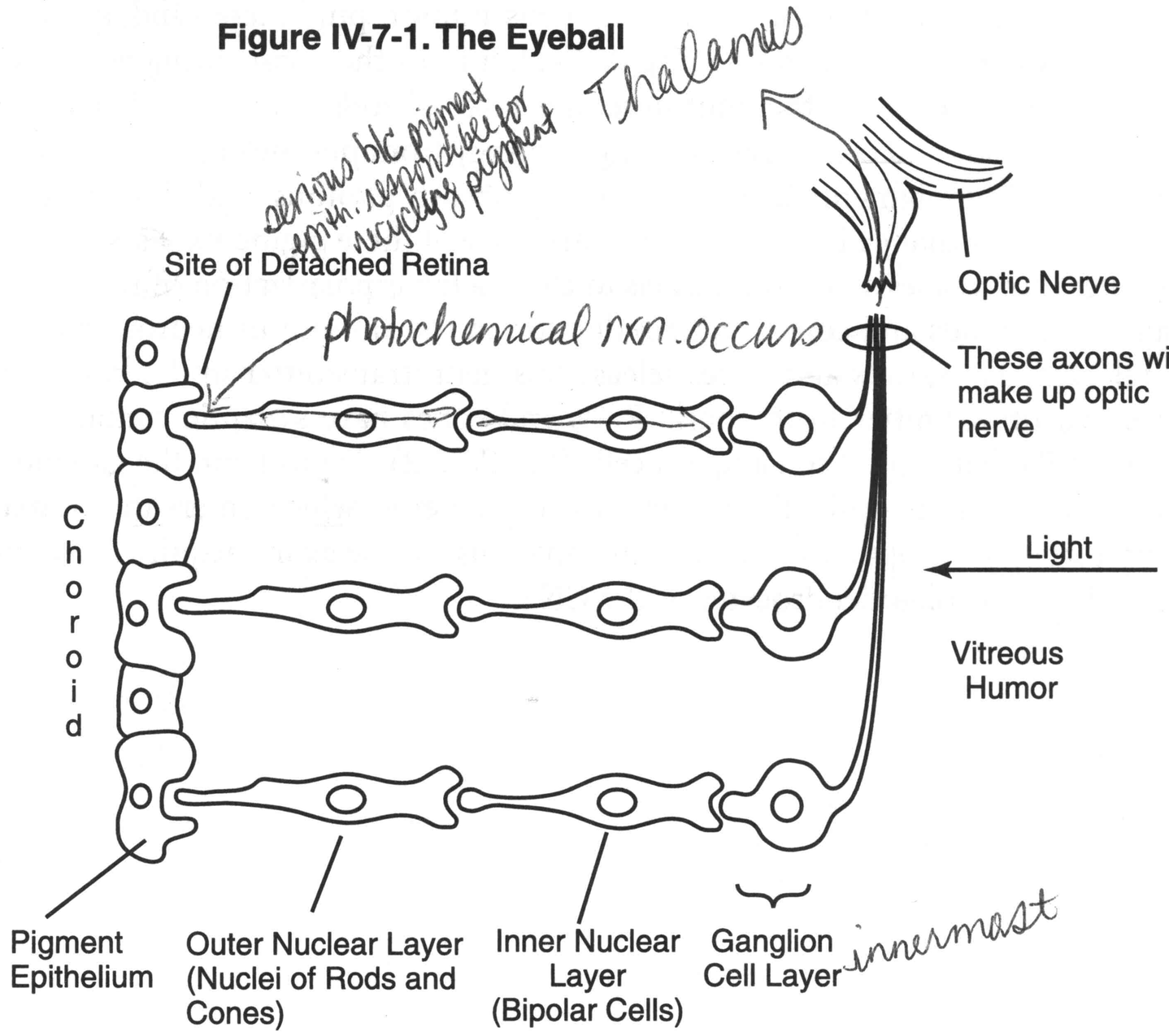

Figure IV-7-2. The Retina

EMBRYO. rods & cones come from inner layer of optic cup

At the optic chiasm, 60% of the optic nerve fibers from the nasal half of each retina cross and project into the contralateral optic tract (Fig IV-7-3). Fibers from the temporal retina do not cross at the chiasm and instead pass into the ipsilateral optic tract. The optic tract contains remixed optic nerve fibers from the temporal part of the ipsilateral retina and fibers from the nasal part of the contralateral retina. Because the eye inverts images like a camera, in reality each nasal retina receives information from a temporal hemifield, and each temporal retina receives information from a nasal hemifield. Most fibers in the optic tract project to the lateral geniculate nucleus. Optic tract fibers also project to the superior colliculi for reflex gaze, to the pretectal area for the light reflex, and to the suprachiasmatic nucleus of the hypothalamus for circadian rhythms.

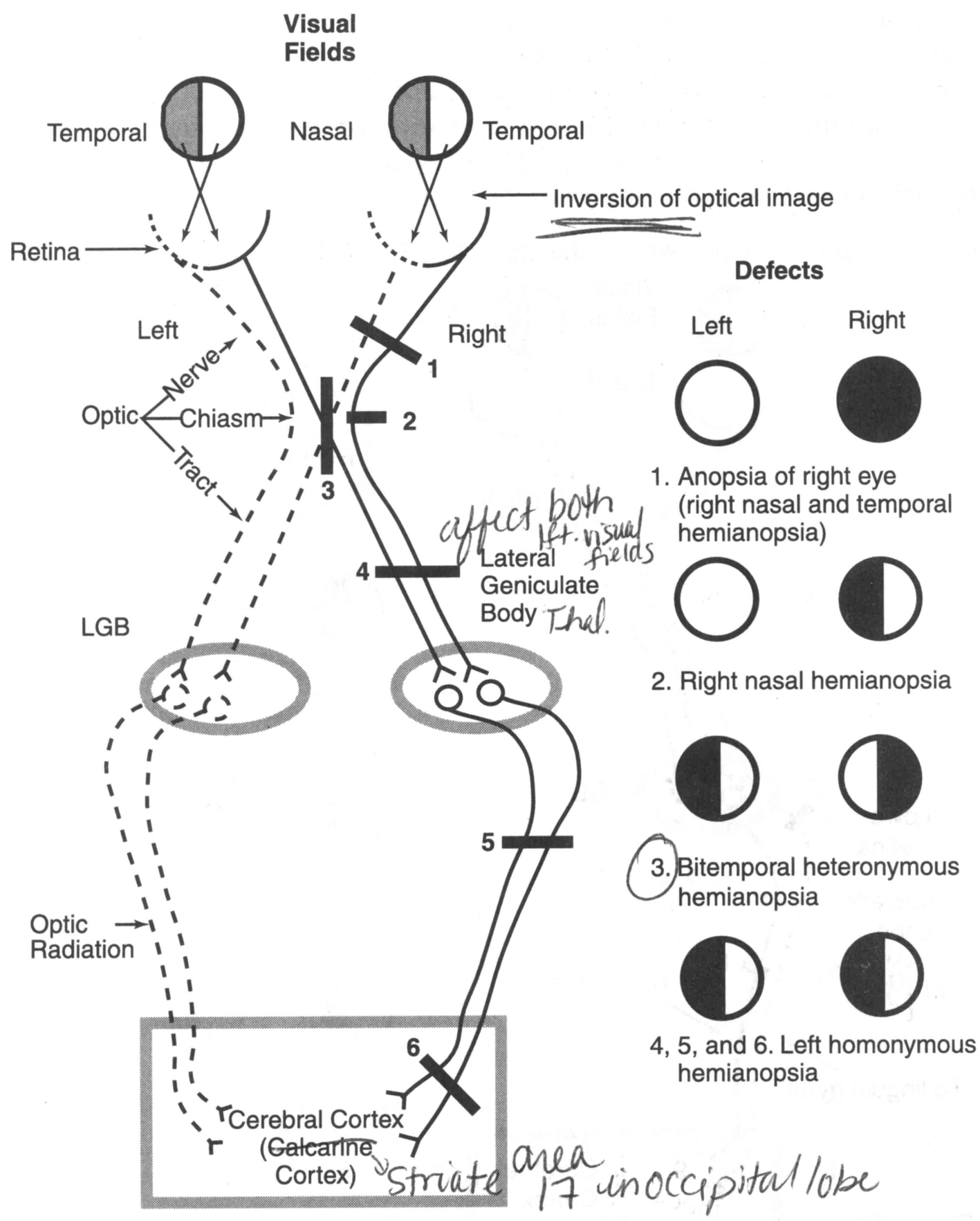

Figure IV-7-3. Visual System I

The lateral geniculate body (LGB) is a laminated structure that receives input from

Clinical Correlate

Some causes of lesions at #1–6:

1. Optic neuritis—in multiple sclerosis, occlusion of central artery of retina
2. Aneurysm of internal carotid artery
3. Craniopharyngioma, pituitary adenoma, aneurysm of anterior communicating artery
4. Vascular; lesion is rarely complete
5, 6. Vascular due to occlusion of branch of posterior cerebral artery

Note

Visual information from **lower** retina courses in **lateral** fibers forming Meyer's **loop**, which projects to the lingual gyrus.

Clinical Correlate

Some causes of lesions at #7–9:

7. Occlusion of branch of middle cerebral artery
8, 9. Occlusion of a branch of posterior cerebral artery. The macula is spared in #9 due to collateral blood supply from the middle cerebral artery.

the optic tract and gives rise to axons that terminate on cells in the primary visual cortex (striate cortex, Brodmann area 17) of the occipital lobe. The LGB laminae maintain a segregation of inputs from the ipsilateral and contralateral retina.

The axons from the LGB that project to the striate cortex are known as optic radiations, visual radiations, or the geniculocalcarine tract. The calcarine sulcus divides the striate cortex (primary visual cortex or Brodmann area 17) into the cuneus and the lingual gyri. The cuneus gyrus, which lies on the superior bank of the calcarine cortex, receives the medial fibers of the visual radiations. The lingual gyrus, which lies on the inferior bank of the calcarine cortex, receives the lateral fibers of the visual radiation. The medial fibers coursing in the visual radiations, which carry input from the upper retina (i.e., the lower contralateral visual field), pass from the LGB directly through the parietal lobe to reach the cuneus gyrus. Significantly, the lateral fibers coursing in the visual radiations, which carry input from the lower retina (i.e., the upper contralateral visual field), take a circuitous route from the LGB through Meyer's loop anteriorly into the temporal lobe. The fibers of Meyer's loop then turn posteriorly and course through the parietal lobe to reach the lingual gyrus in the striate cortex.

This figure shows the pathway for the right visual field only.

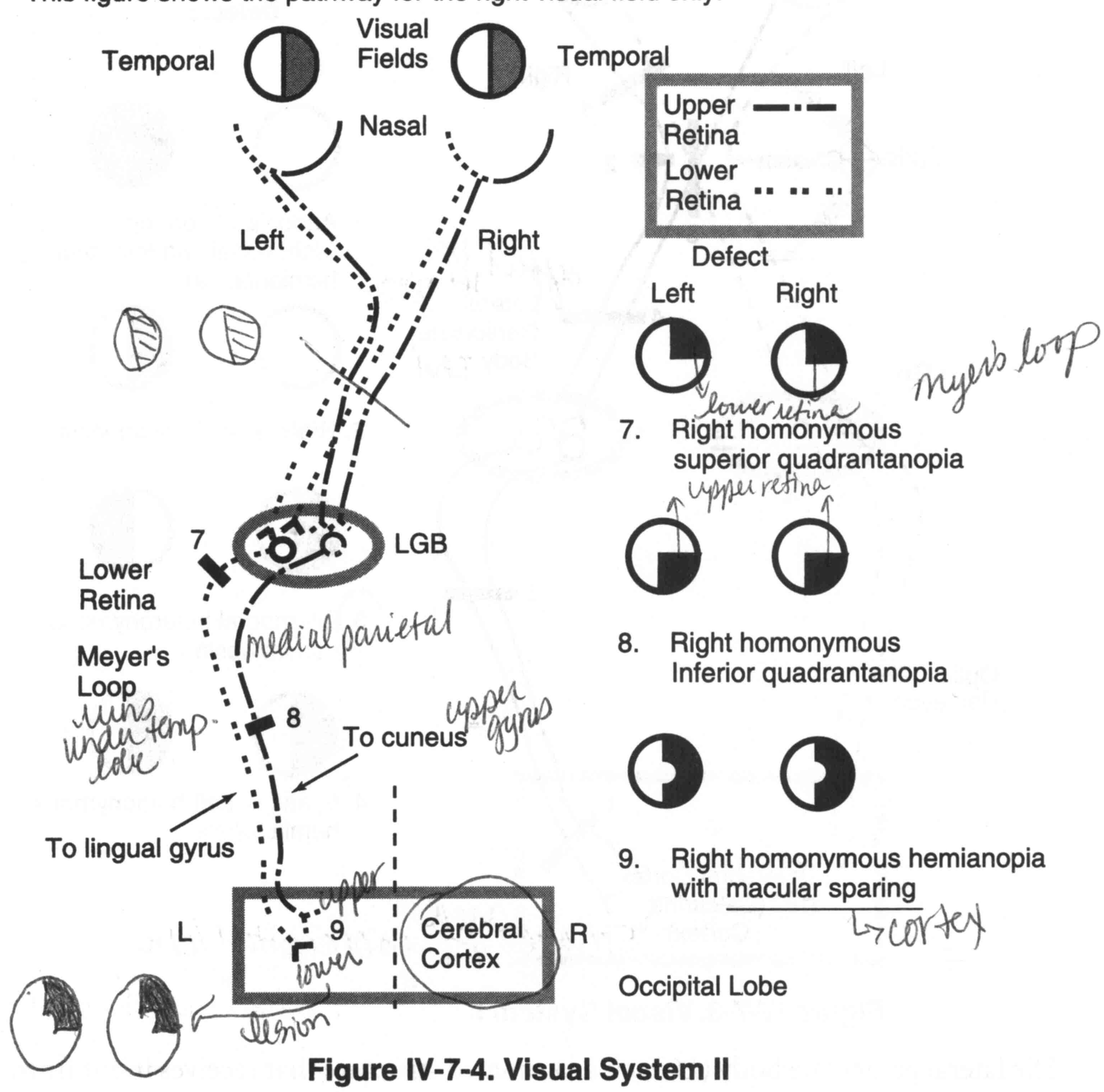

Figure IV-7-4. Visual System II

LESIONS OF THE VISUAL PATHWAYS

Lesions of the retina that include destruction of the macula produce a central scotoma. The macula is quite sensitive to intense light, trauma, aging, and neurotoxins.

Lesions of an optic nerve produce blindness (anopsia) in that eye and a loss of the sensory limb of the light reflex. The pupil of the affected eye constricts when light is shined into the opposite eye (consensual light reflex) but not when light is shined into the blinded eye (absence of direct light reflex).

Compression of the optic chiasm, often the result of a pituitary tumor or meningioma, results in a loss of peripheral vision in both temporal fields because the crossing fibers from each nasal retina are damaged. The resulting visual field defect is called a bitemporal heteronymous hemianopia.

All lesions past the chiasm produce contralateral defects. Lesions of the optic tract result in a loss of visual input from the contralateral visual field. For example, a lesion of the right optic tract results in a loss of input from the left visual field. This is called a homonymous hemianopia; in this example, a left homonymous hemianopia.

Lesions of the visual radiations are more common than lesions to the optic tract or lateral geniculate body and produce visual field defects (a contralateral homonymous hemianopia) similar to those of the optic tract if all fibers are involved.

Lesions restricted to the lateral fibers in Meyer's loop, usually in the temporal lobe, result in a loss of visual input from the contralateral upper quarter of the visual field. For example, a lesion of the temporal fibers in the **right** visual radiation results in loss of visual input from the upper left quarter of the field (a **left** superior quadrantanopia).

Lesions restricted to the medial fibers in the visual radiation in the parietal lobe result in a loss of visual input from the contralateral lower quarter of the field (an inferior quadrantanopia).

Lesions inside the primary visual cortex are equivalent to those of the visual radiations, resulting in a contralateral homonymous hemianopsia, except that macular (central) vision is spared.

Lesions of the cuneus gyrus are equivalent to lesions restricted to the parietal fibers of the visual radiation, with macular sparing.

Lesions of the lingula are similar to lesions of the Meyer's loop fibers except for the presence of macular sparing. The pupillary light reflex is spared in lesions of the radiations or inside visual cortex because fibers of the pupillary light reflex leave the optic tracts to terminate in the pretectal area. The combination of blindness with intact pupillary reflexes is termed cortical blindness.

Clinical Correlate

Unilateral optic nerve lesions are seen in multiple sclerosis where there is an immune-related inflammatory demyelination of the nerve. The lesion typically presents with a central scotoma due to involvement of the deep fibers in the nerve from the macula.

Note

Lesions to the visual radiations are more common than lesions to the optic tract.

VISUAL REFLEXES

Pupillary Light Reflex

When light is directed into an eye, it stimulates retinal photoreceptors and results in impulses carried in the optic nerve to the pretectal area. Cells in the pretectal area send axons to the Edinger-Westphal nuclei on both sides.

The Edinger-Westphal nucleus is the parasympathetic nucleus of the oculomotor nerve and gives rise to preganglionic parasympathetic fibers that pass in the third cranial nerve to the ciliary ganglion. Because cells in the pretectal area supply both Edinger-Westphal nuclei, shining light into one eye results in constriction of both the ipsilateral pupil (direct light reflex) and contralateral pupil (consensual light reflex).

Accommodation-Convergence Reaction

This reaction occurs when an individual attempts to focus on a nearby object after looking at a distant object. The oculomotor nerve carries the efferent fibers from the accommodation-convergence reaction, which consists of three components, accommodation, convergence, and pupillary constriction.

Accommodation refers to the reflex that increases the curvature of the lens needed for near vision. Preganglionic parasympathetic fibers arise in the Edinger-Westphal nucleus and pass via the oculomotor nerve to the ciliary ganglion. Postganglionic parasympathetic fibers from the ciliary ganglion supply the ciliary muscle. Contraction of this muscle relaxes the suspensory ligaments and allows the lens to increase its convexity (become more round). This increases the refractive index of the lens, permitting the image of a nearby object to focus on the retina.

Convergence results from contraction of both medial rectus muscles, which pull the eyes to look toward the nose. This allows the image of the near object to focus on the same part of the retina in each eye.

Pupillary constriction (miosis) results from contraction of the constrictor muscle of the iris. A smaller aperture gives the optic apparatus a greater depth of field. With Argyll Robertson pupils, both direct and consensual light reflexes are lost, but the accommodation-convergence reaction remains intact. This type of pupil is often seen in cases of neurosyphilis; however, it is sometimes seen in patients with multiple sclerosis or pineal tumors. The lesion site is believed to occur near the pretectal nuclei just rostral to the superior colliculi.

Diencephalon

8

The diencephalon can be divided into four parts: the thalamus, the hypothalamus, the epithalamus, and the subthalamus.

THALAMUS

The thalamus serves as the major sensory relay for the ascending tactile, visual, auditory, and gustatory information that ultimately reaches the neocortex. Motor control areas such as the basal ganglia and cerebellum also synapse in thalamic nuclei before they reach their cortical destinations. Other nuclei participate in the regulation of states of consciousness.

Major Thalamic Nuclei and Their Inputs and Outputs

Anterior Nuclear Group (part of the Papez circuit of limbic system)

Input is from the mammillary bodies via the mammillothalamic tract and from the cingulate gyrus; output is to the cingulate gyrus via the anterior limb of the internal capsule.

Medial Nuclear Group (part of limbic system)

Input is from the amygdala, prefrontal cortex, and temporal lobe; output is to the prefrontal cortex and cingulate gyrus. The most important nucleus is the dorsomedial nucleus.

damaged in ind. w/ Korsakoff's

Clinical Correlate

Thiamine deficiency in alcoholics results in degeneration of the dorsomedial nucleus of thalamus and the mammillary bodies, hippocampus, and vermis of the cerebellum (see chapter 10).

Clinical Correlate

Thalamic pain syndrome affects the ventral nuclear group. Patients present with burning, aching pain in contralateral limbs or body. Involvement of the DC/ML part of VPL increases the sensitivity to pain and presents as contralateral loss of vibratory sense and gait ataxia. Thalamic pain syndrome is resistent to analgesic medications.

Ventral Nuclear Group

Motor Nuclei

Ventral anterior nucleus (VA): Input to VA is from the globus pallidus, substantia nigra. Output is to the premotor and primary motor cortex.

Ventral lateral nucleus (VL): Input to VL is mainly from the globus pallidus and the dentate nucleus of the cerebellum. Output is to the primary motor cortex (Brodmann area 4).

Sensory Nuclei

Ventral posterolateral (VPL) nucleus: Input to VPL conveying somatosensory and nociceptive information ascends in the medial lemniscus and spinothalamic tract. Output is to primary somatosensory cortex (Brodmann areas 3, 1, and 2) of the parietal lobe.

Ventral posteromedial (VPM) nucleus: Input to VPM is from the ascending trigeminal pathways. Output is to primary somatosensory cortex (Brodmann areas 3, 1, and 2) of the parietal lobe.

Medial geniculate body (nucleus): Input is from auditory information that ascends from the inferior colliculus. Output is to primary auditory cortex.

Lateral geniculate body (nucleus): Input is from the optic tract. Output is in the form of the geniculocalcarine or visual radiations that project to the primary visual (striate) cortex in the occipital lobe.

Midline and Intralaminar Nuclei

Midline and intralaminar nuclei receive input from the brain stem reticular formation, and from the spinothalamic tract. Intralaminar nuclei send pain information to the cingulate gyrus.

These nuclei appear to be important in mediating desynchronization of the electroencephalogram (EEG) during behavioral arousal.

HYPOTHALAMUS

The hypothalamus is composed of numerous nuclei that have afferent and efferent connections with widespread regions of the nervous system, including the pituitary gland, the autonomic system, and the limbic system (Fig IV-8-1).

Major Hypothalamic Regions or Zones, and Their Nuclei

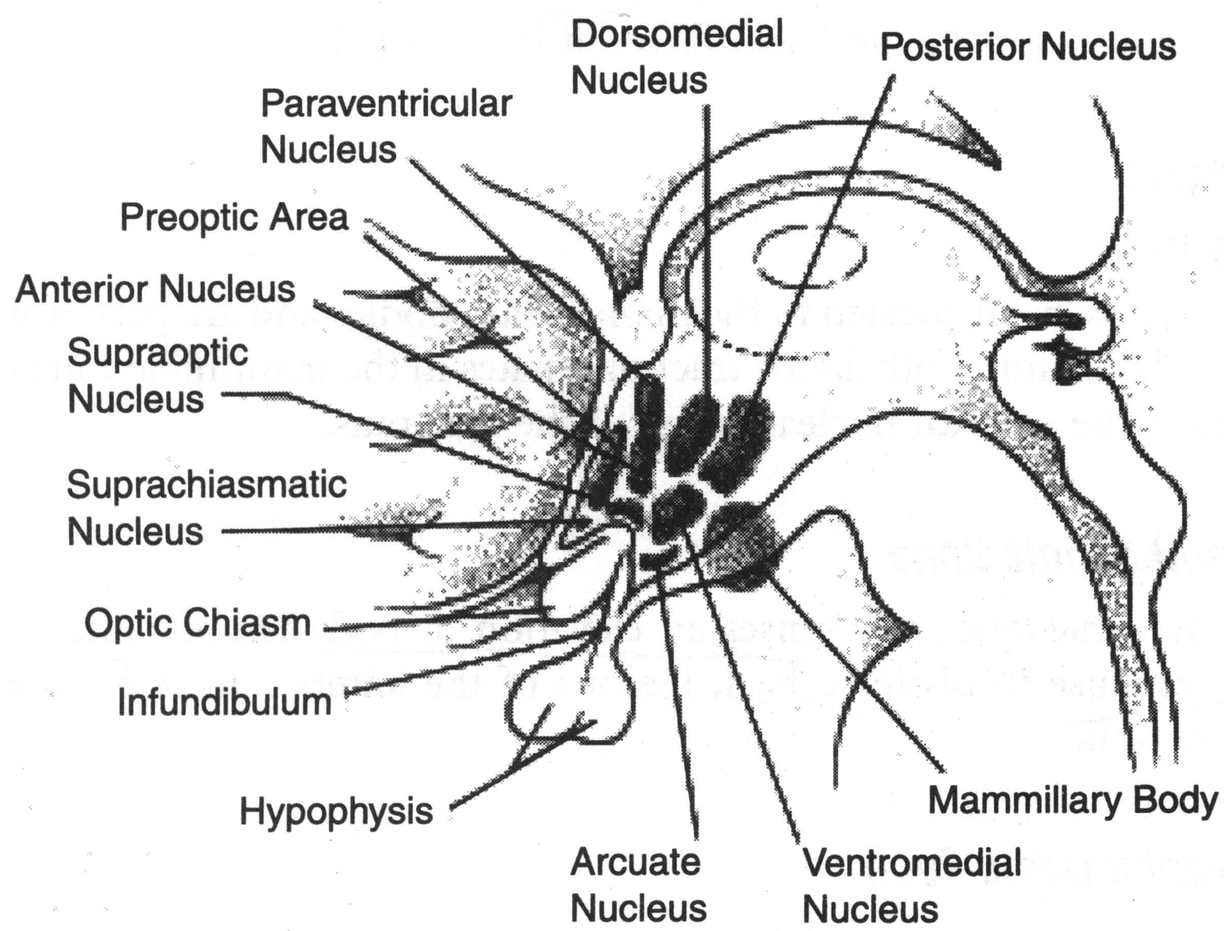

Figure IV-8-1. The Hypothalamic Nuclei

Anterior Region

Paraventricular and Supraoptic Nuclei

These nuclei synthesize the neuropeptides antidiuretic hormone (ADH) and oxytocin. Axons arising from these nuclei leave the hypothalamus and course in the supraopticohypophysial tract, which carries neurosecretory granules to the posterior pituitary gland, where they are released into capillaries. Lesions of the supraoptic nuclei lead to diabetes insipidus, which is characterized by polydipsia (excess water consumption) and polyuria (excess urination).

Suprachiasmatic Nucleus

Visual input from the retina by way of the optic tract terminates in the suprachiasmatic nucleus. This information helps set certain body rhythms to the 24-hour light-dark cycle (circadian rhythms).

Tuberal Region

Arcuate Nucleus

Cells in the arcuate nucleus produce releasing hormones and inhibitory factors, which enter capillaries in the tuberoinfundibular tract and pass through the hypophyseal-portal veins to reach the secondary capillary plexus in the anterior pituitary gland. Releasing hormones and inhibitory factors influence the secretory activity of the acidophils and basophils in the anterior pituitary. (See Histology section.)

Clinical Correlate

Dopaminergic projections from the arcuate nuclei inhibit prolactin secretion from the anterior pituitary. Lesions result in galactorrhea (milk discharge) and amenorrhea.

Ventromedial Nucleus

The ventromedial hypothalamus is a satiety center and regulates food intake. Lesions of the ventromedial hypothalamus result in obesity.

Posterior Region

Mammillary Bodies

The mammillary nuclei are located in the mammillary bodies and are part of the limbic system. The mammillothalamic tract originates in the mammillary nuclei and terminates in the anterior nuclear group of the thalamus.

Clinical Correlate

Korsakoff's Syndrome

Lesions of the mammillary bodies occur in Korsakoff's syndrome and are usually associated with thiamine deficiency associated with chronic alcoholism. Korsakoff's syndrome results in both anterograde and retrograde amnesia with confabulations.

Anterior Hypothalamic Zone

The anterior hypothalamic zone senses an elevation of body temperature and mediates the response to dissipate heat. Lesions of the anterior hypothalamus lead to hyperthermia.

Posterior Hypothalamic Zone

The posterior hypothalamic zone senses a decrease of body temperature and mediates the conservation of heat. Lesions of the posterior hypothalamus lead to poikilothermy (i.e., cold-blooded organisms). An individual with a lesion of the posterior hypothalamus has a body temperature that varies with the environmental temperature.

Lateral Hypothalamic Zone

The lateral hypothalamic zone is a feeding center; lesions of the lateral hypothalamus produce severe aphagia.

Preoptic Area

The preoptic area is sensitive to androgens and estrogens, whereas other areas influence the production of sex hormones through their regulation of the anterior pituitary. Before puberty, hypothalamic lesions here may arrest sexual development.

After puberty, hypothalamic lesions in this area may result in amenorrhea or impotence.

EPITHALAMUS

The epithalamus is the part of the diencephalon located in the region of the posterior commissure that consists of the pineal body and the habenular nuclei.

The pineal body is a small, highly vascularized structure situated above the posterior commissure and attached by a stalk to the roof of the third ventricle.

The pineal body contains pinealocytes and glial cells but no neurons.

- Pinealocytes synthesize melatonin, serotonin, and cholecystokinin.

The pineal gland plays a role in growth, development, and the regulation of circadian rhythms.

Environmental light regulates the activity of the pineal gland through a retinal–suprachiasmatic–pineal pathway.

The subthalamus is reviewed with the basal ganglia.

Clinical Correlate

Precocious Puberty

In young males, pineal lesions may cause precocious puberty.

Pineal Tumors

Pineal tumors may cause obstruction of CSF flow and increased intracranial pressure. Compression of the upper midbrain and pretectal area by a pineal tumor results in Parinaud's syndrome, in which there is impairment of conjugate vertical gaze and pupillary reflex abnormalities.

Basal Ganglia

9

GENERAL FEATURES

Start & Stop moving

The basal ganglia initiate and provide gross control over skeletal muscle movements. The major components of the basal ganglia include:

→ major input area

- Striatum, which consists of the caudate nucleus and the putamen.
- External and internal segments of the globus pallidus.
- Substantia nigra.
- Subthalamic nucleus.

Together with the cerebral cortex and the VL nucleus of the thalamus, these structures are interconnected to form two parallel but antagonistic circuits known as the direct and indirect basal ganglia pathways (Figs IV-9-1 and IV-9-2). Both pathways are driven by extensive inputs from large areas of cerebral cortex, and both project back to the motor cortex after a relay in the VL nucleus of the thalamus. Both pathways use a process known as "disinhibition" to mediate their effects, whereby one population of inhibitory neurons inhibits a second population of inhibitory neurons.

Direct Basal Ganglia Pathway

In the direct pathway, excitatory input from the cerebral cortex projects to striatal neurons in the caudate nucleus and putamen. Through disinhibition, activated inhibitory neurons in the striatum, which use γ-aminobutyric acid (GABA) as their neurotransmitter, project to and inhibit additional GABA neurons in the internal segment of the globus pallidus.

The GABA axons of the internal segment of the globus pallidus project to the thalamus (VL). Because their input to the thalamus is disinhibited, the thalamic input excites the motor cortex. The net effect of the disinhibition in the direct pathway results in an **increased** level of cortical excitation and the promotion of movement.

Indirect Basal Ganglia Pathway

In the indirect pathway, excitatory input from the cerebral cortex also projects to striatal neurons in the caudate nucleus and putamen. These inhibitory neurons in the striatum, which also use GABA as their neurotransmitter, project to and inhibit additional GABA neurons in the external segment of the globus pallidus.

The GABA axons of the external segment of the globus pallidus project to the subthalamic nucleus. Through disinhibition, the subthalamic nucleus excites inhibitory GABA neurons in the internal segment of the globus pallidus, which inhibits the thalamus. This decreases the level of cortical excitation, inhibiting movement. The net effect of the disinhibition in the indirect pathway results in a **decreased** level of cortical excitation.

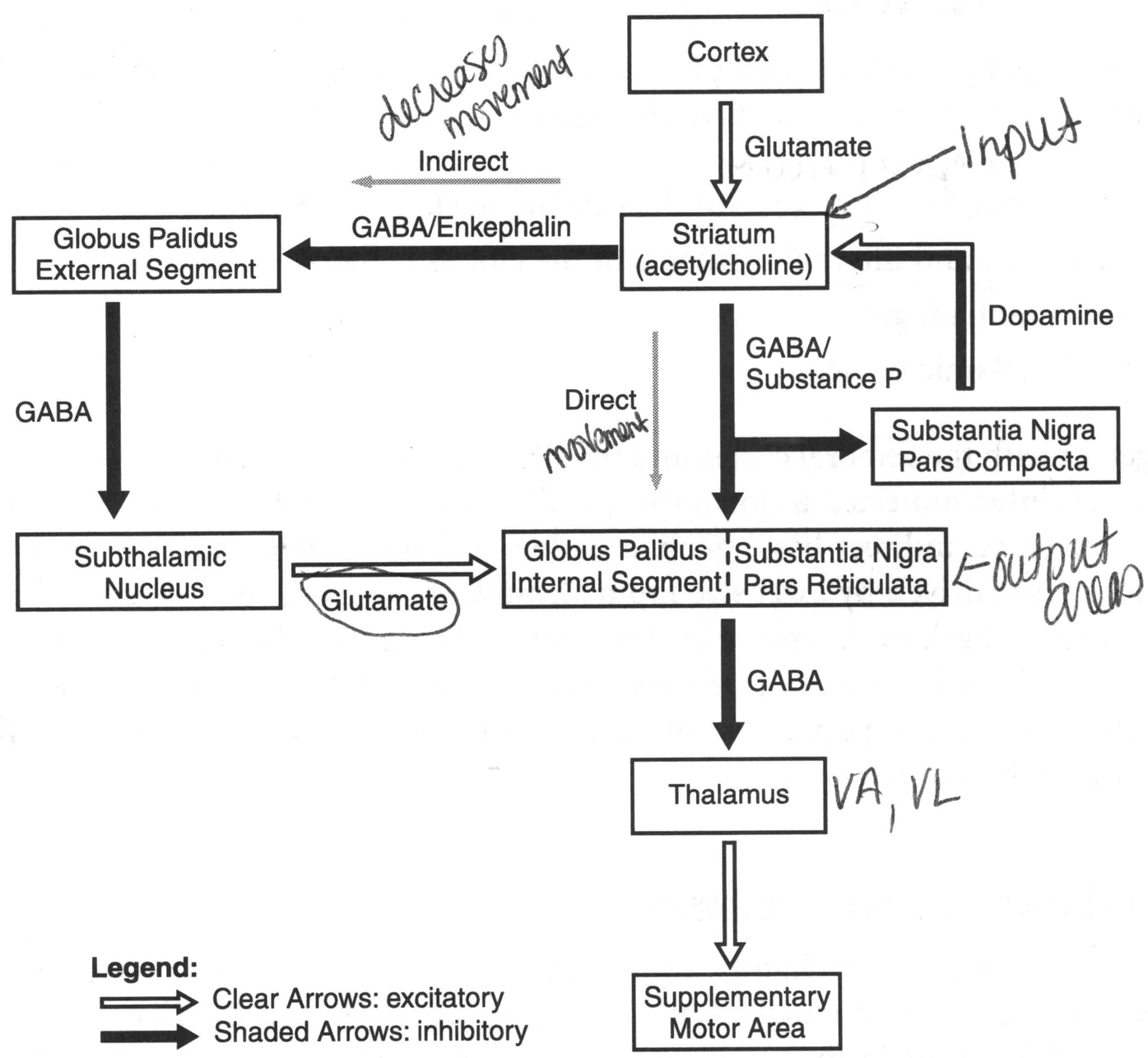

Anatomy IV-9-1. Direct and Indirect Basal Ganglia Pathways

Dopamine and Cholinergic Effects

In addition to the GABA neurons, two other sources of chemically significant neurons enhance the effects of the direct or indirect pathways.

Dopaminergic neurons in the substantia nigra in the midbrain project to the striatum. The effect of dopamine excites or drives the direct pathway, increasing cortical excitation. Dopamine excites the direct pathway through D_1 receptors and inhibits the indirect pathway through D_2 receptors.

Cholinergic neurons found within the striatum have the opposite effect. Acetylcholine drives the indirect pathway, decreasing cortical excitation.

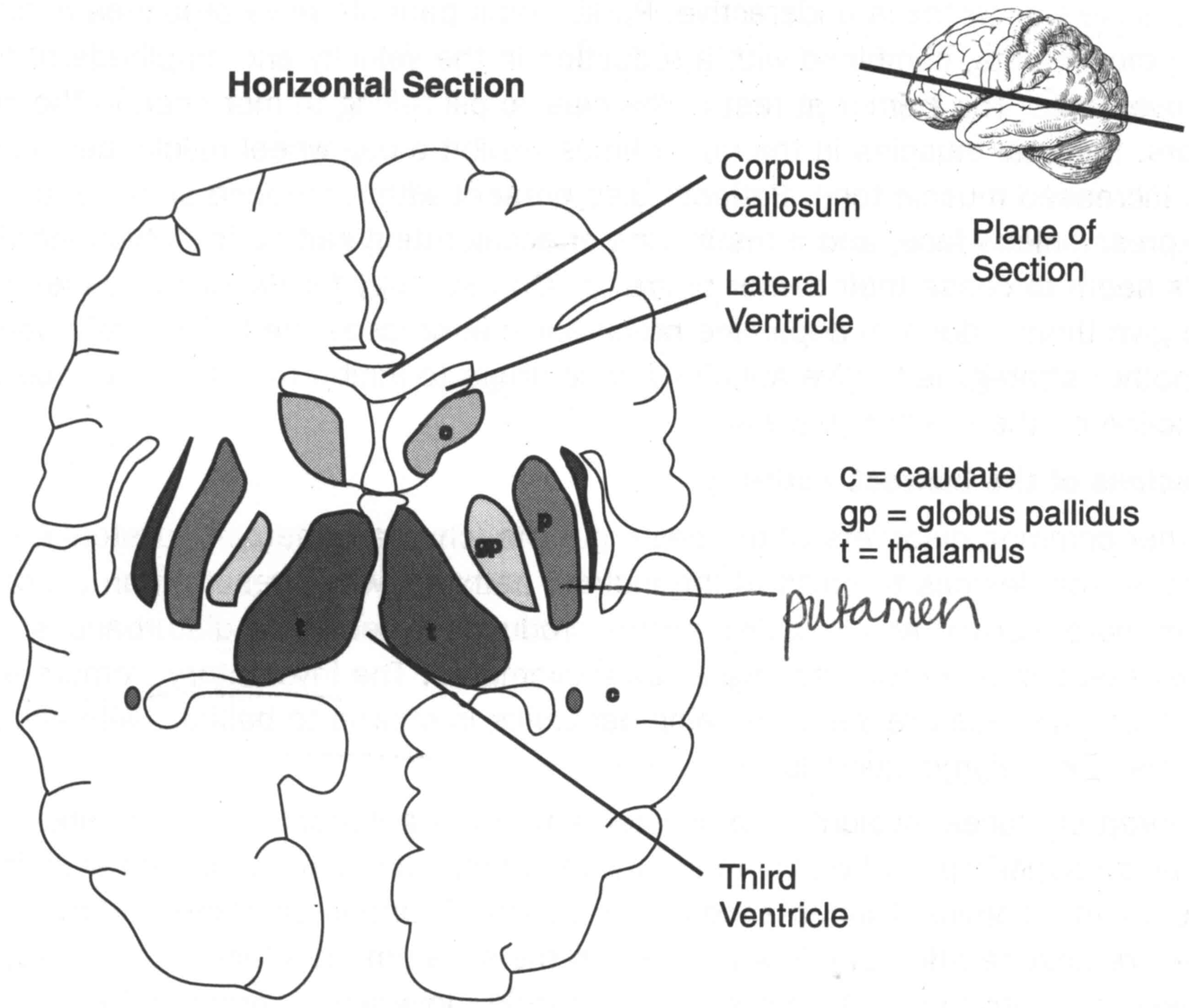

Figure IV-9-2. The Basal Ganglia

Table IV-9-1. Basal Ganglia—Clinicopathological Correlations

Movement Disorder	Lesion
Chorea: multiple quick, random movements, usually most prominent in the appendicular muscles	Atrophy of the **striatum.** Huntington's chorea.
Athetosis: low writhing movements, which are usually more severe in the appendicular muscles	Diffuse hypermyelinization of the **corpus striatum** and **thalamus** cerebral palsy.
Hemiballismus: wild flinging movements of half of the body	Hemorrhagic destruction of the **contralateral subthalamic nucleus.** Hypertensive patients.
Parkinsonism: pill-rolling tremor of the fingers at rest, lead-pipe rigidity, and akinesia	Degeneration of the **substantia nigra**

Lesions or Diseases of the Basal Ganglia

Lesions or diseases of the basal ganglia generally present with movement disorders, known as dyskinesias, and an involuntary tremor, or tremor at rest.

Most basal ganglia disorders seem to preferentially affect either the direct or the indirect pathways, altering the balance between the two.

Lesions of the Direct Pathway

Lesions of the direct pathway result in an underactive cortex and hypokinetic disturbances in which there is a slowing or absence of spontaneous movements. The best known disorder of the direct pathway is caused by the degeneration of dopaminergic neurons of the substantia nigra in Parkinson's disease. Because the cortex is underactive, Parkinson's patients have problems initiating movements, combined with a reduction in the velocity and amplitude of the movements. The tremor at rest is the classic pill rolling tremor seen in the fingers. Skeletal muscles in the upper limbs exhibit a cog wheel rigidity because of increased muscle tone. Patients also present with a stooped posture, an expressionless face, and a festinating or accelerating gait during which individuals seem to chase their center of gravity. One strategy for Parkinson patients is to give them L-dopa, a dopamine precursor that crosses the blood–brain barrier. Another strategy is to give anticholinergic drugs to inhibit the effects of acetylcholine on the indirect pathway.

Lesions of the Indirect Pathway

Other common disorders of the basal ganglia (chorea, athetosis, dystonia, tics) result from lesions to parts of the indirect pathway, which result in an overactive motor cortex. An overactive cortex produces hyperkinetic disturbances, expressed in numerous spontaneous movements. The involuntary tremors seen in these diseases range from being dancelike in chorea to ballistic with lesions to the subthalamic nucleus.

Chorea produces involuntary movements that are purposeless, quick jerks that may be superimposed on voluntary movements. Huntington's chorea exhibits autosomal dominant inheritance (chromosome 4) and is characterized by severe degeneration of GABA neurons in the striatum. In addition to chorea, these patients frequently suffer from athetoid movements, progressive dementia, and behavioral disorders. Sydenham's chorea is a transient complication in some children with rheumatic fever.

Athetosis refers to slow, wormlike, involuntary movements that are most noticeable in the fingers and hands but may involve any muscle group. It is present in Huntington's disease and may be observed in many diseases that involve the basal ganglia.

Dystonia refers to a slow, prolonged movement involving predominantly the truncal musculature. Dystonia often occurs with athetosis. Blepharospasm (contraction of the orbicularis oculi causing the eyelids to close), spasmodic torticollis (in which the head is pulled toward the shoulder), and writer's cramp (contraction of arm and hand muscles on attempting to write) are all examples of dystonic movements.

Lesions or Diseases of the Basal Ganglia *(continued)*

Hemiballismus results from a lesion of the subthalamic nucleus usually seen in hypertensive patients. Hemiballismus refers to a violent projectile movement of a limb and is typically observed in the upper limb contralateral to the involved subthalamic nucleus.

Tourette's syndrome involves facial and vocal tics that progress to jerking movements of the limbs. It is frequently associated with explosive, vulgar speech.

Wilson's disease results from an abnormality of copper metabolism, causing the accumulation of copper in the liver and basal ganglia. Personality changes, tremor, dystonia, and athetoid movements develop. Untreated patients usually succumb because of hepatic cirrhosis. A thin brown ring around the outer cornea, the Kayser-Fleischer ring, may be present and aid in the diagnosis.

Cerebral Cortex

10

The surface of the cerebral cortex is highly convoluted with the bulges or eminences referred to as gyri and the spaces separating the gyri called sulci (Figs IV-10-1 and IV-10-2). Lobes of the cerebrum are divided according to prominent gyri and sulci that are fairly constant in humans. Two prominent sulci on the lateral surface are key to understanding the divisions of the hemispheres. The lateral fissure (of Sylvius) separates the frontal and temporal lobes rostrally; further posteriorly, it partially separates the parietal and the temporal lobes. The central sulcus (of Rolando) is situated roughly perpendicular to the lateral fissure. The central sulcus separates the frontal and the parietal lobes. The occipital lobe extends posteriorly from the temporal and parietal lobes, but its boundaries on the lateral aspect of the hemisphere are indistinct. On the medial aspect of the hemisphere, the frontal and parietal lobes are separated by a cingulate sulcus from the cingulate gyrus. The cingulate is part of an artificial limbic lobe. Posteriorly, the parieto-occipital sulcus separates the parietal lobe from the occipital lobe. The calcarine sulcus divides the occipital lobe horizontally into a superior cuneus and an inferior lingual gyrus.

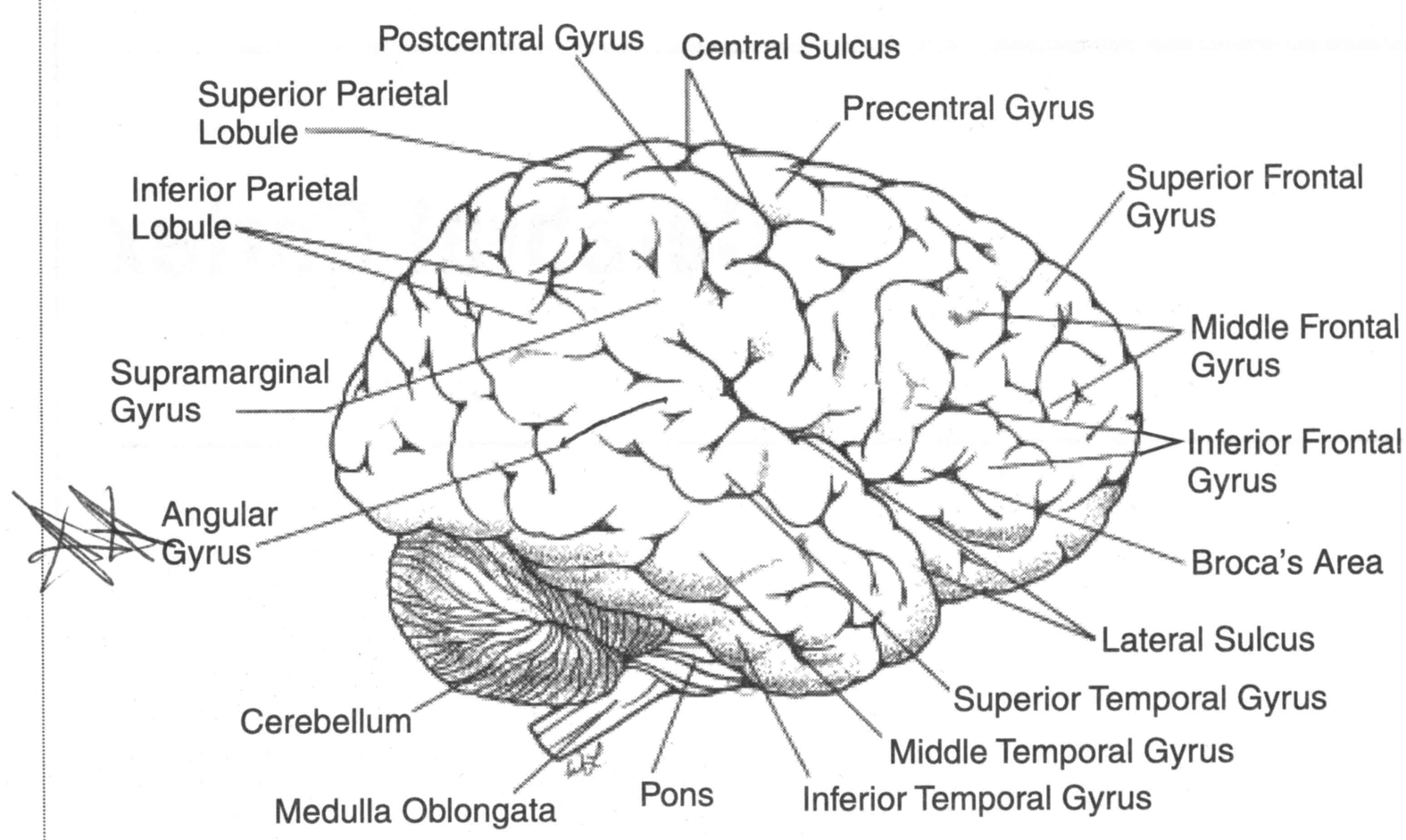

Figure IV-10-1. Lateral View of the Right Cerebral Hemisphere

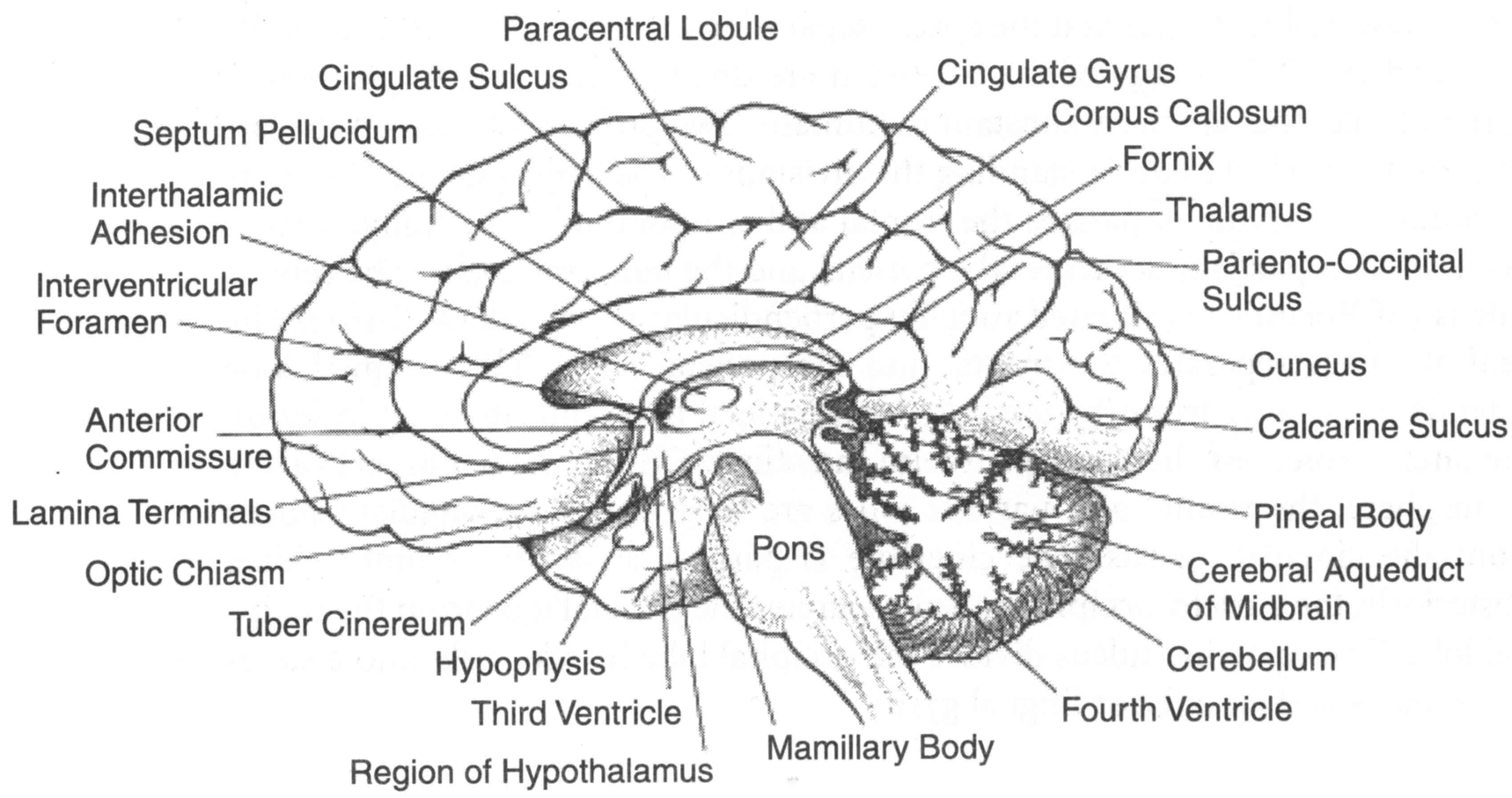

Figure IV-10-2. Medial View of the Cerebral Hemisphere

About 90% of the cortex is composed of six layers, which form the neocortex (Fig IV-10-3). The olfactory cortex and hippocampal formation are three-layered structures and together comprise the allocortex. All of the neocortex contains a six-layer cellular arrangement, but the actual structure varies considerably between different locations. On the basis of these variations in the cytoarchitecture, Brodmann divided the cortex into 47 areas, but only a few Brodmann numbers are used synonymously with functionally specific cortical areas.

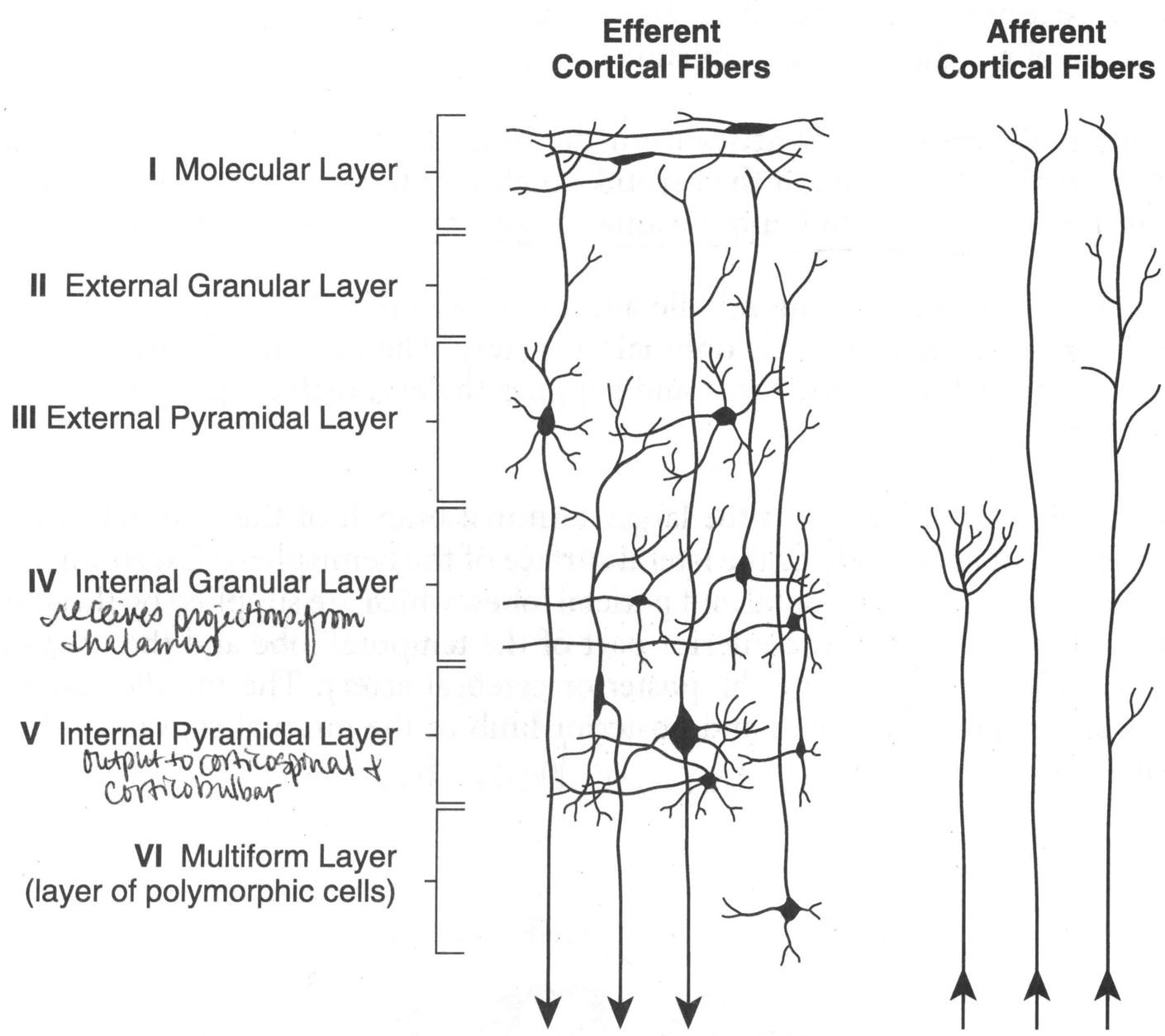

Figure IV-10-3. The Six-Layered Neocortex

Note

The internal granular layer is the site of termination of the thalamocortical projections. In primary visual cortex, these fibers form a distinct Line of Gennari. The internal pyramidal layer gives rise to axons that form the corticospinal and corticobulbar tracts.

LANGUAGE AND THE DOMINANT HEMISPHERE

Most people (about 80%) are right-handed, which implies that the left side of the brain has more highly developed hand-controlling circuits. In the vast majority of right-handed people, speech and language functions are also predominantly organized in the left hemisphere. Most left-handed people show language functions bilaterally, although a few, with strong left-handed preferences, show right-sided speech and language functions.

BLOOD SUPPLY

The cortex is supplied by the two internal carotid arteries and the two vertebral arteries (Figs IV-10-4 and IV-10-5). On the base (or inferior surface) of the brain, branches of the internal carotid arteries and the basilar artery anastomose to form the circle of Willis. The anterior part of the circle lies in front of the optic chiasm, whereas the posterior part is situated just below the mammillary bodies. The circle of Willis is formed by the terminal part of the internal carotid arteries; the proximal parts of the anterior and posterior cerebral arteries and the anterior and posterior communicating arteries. The middle, anterior, and posterior

A clot from carotid most likely ends up in middle cerebral a.

Clinical Correlate

Occlusion of the Middle Cerebral Artery

Occlusion of the middle cerebral artery results in spastic paresis of the contralateral lower face and upper limb and anesthesia of the contralateral face and upper limb.

An aphasia (e.g., Broca's, Wernicke's, or conduction) may result when branches of the left middle cerebral artery are affected, and left-sided neglect may be seen with a blockage of branches of the right middle cerebral artery to the right parietal lobe.

The middle cerebral artery also supplies the proximal parts of the visual radiations as they emerge from the lateral geniculate nucleus of the thalamus and course in Meyer's loop. These fibers course into the temporal lobe before looping posteriorly to rejoin the rest of the visual radiation fibers.

Occlusion of the branches that supply Meyer's loop fibers in the temporal lobe results in a contralateral superior quadrantanopsia.

cerebral arteries, which arise from the circle of Willis, supply all of the cerebral cortex, basal ganglia, and diencephalon.

The internal carotid artery arises from the bifurcation of the common carotid and enters the skull through the carotid canal. It enters the subarachnoid space and terminates by dividing into the anterior and middle cerebral arteries.

Just before splitting into the middle and anterior cerebral arteries, the internal carotid artery gives rise to the ophthalmic artery. The ophthalmic artery enters the orbit through the optic canal and supplies the eye, including the retina and optic nerve.

The middle cerebral artery is the larger terminal branch of the internal carotid artery. It supplies the bulk of the lateral surface of the hemisphere. Exceptions are the superior inch of the frontal and parietal lobes, which are supplied by the anterior cerebral artery, and the inferior part of the temporal lobe and the occipital pole, which are supplied by the posterior cerebral artery. The middle cerebral artery also supplies the genu and posterior limb of the internal capsule and the basal ganglia. leticulostriate branches

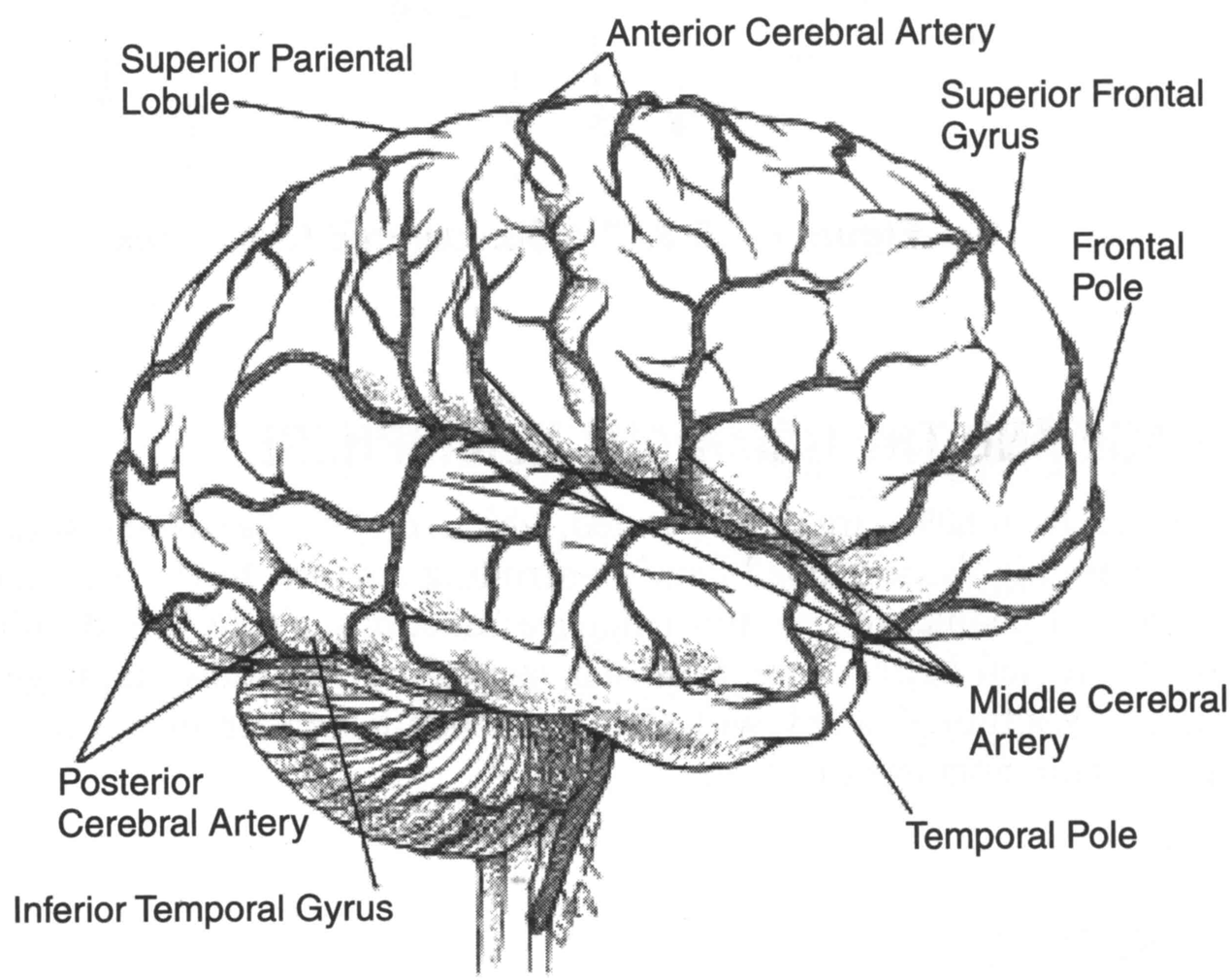

Figure IV-10-4. The Distributions of the Cerebral Arteries: I

The anterior cerebral artery is the smaller terminal branch of the internal carotid artery. It is connected to the opposite anterior cerebral artery by the anterior communicating artery, completing the anterior part of the circle of Willis. The anterior cerebral artery supplies the medial surface of the frontal and parietal lobes, which include motor and sensory cortical areas for the pelvis and lower limbs. The anterior cerebral artery also supplies the anterior four fifths of the corpus callosum and approximately 1 inch of the frontal and parietal cortex on the superior aspect of the lateral aspect of the hemisphere.

Occlusion of the anterior cerebral artery results in spastic paresis of the contralateral lower limb and anesthesia of the contralateral lower limb. Urinary incontinence may be present, but this usually occurs only with bilateral damage. A transcortical apraxia of the left limbs may result from involvement of the anterior portion of the corpus callosum. A transcortical apraxia occurs because the left hemisphere (language dominant) has been disconnected from the motor cortex of the right hemisphere. The anterior cerebral artery also supplies the anterior limb of the internal capsule.

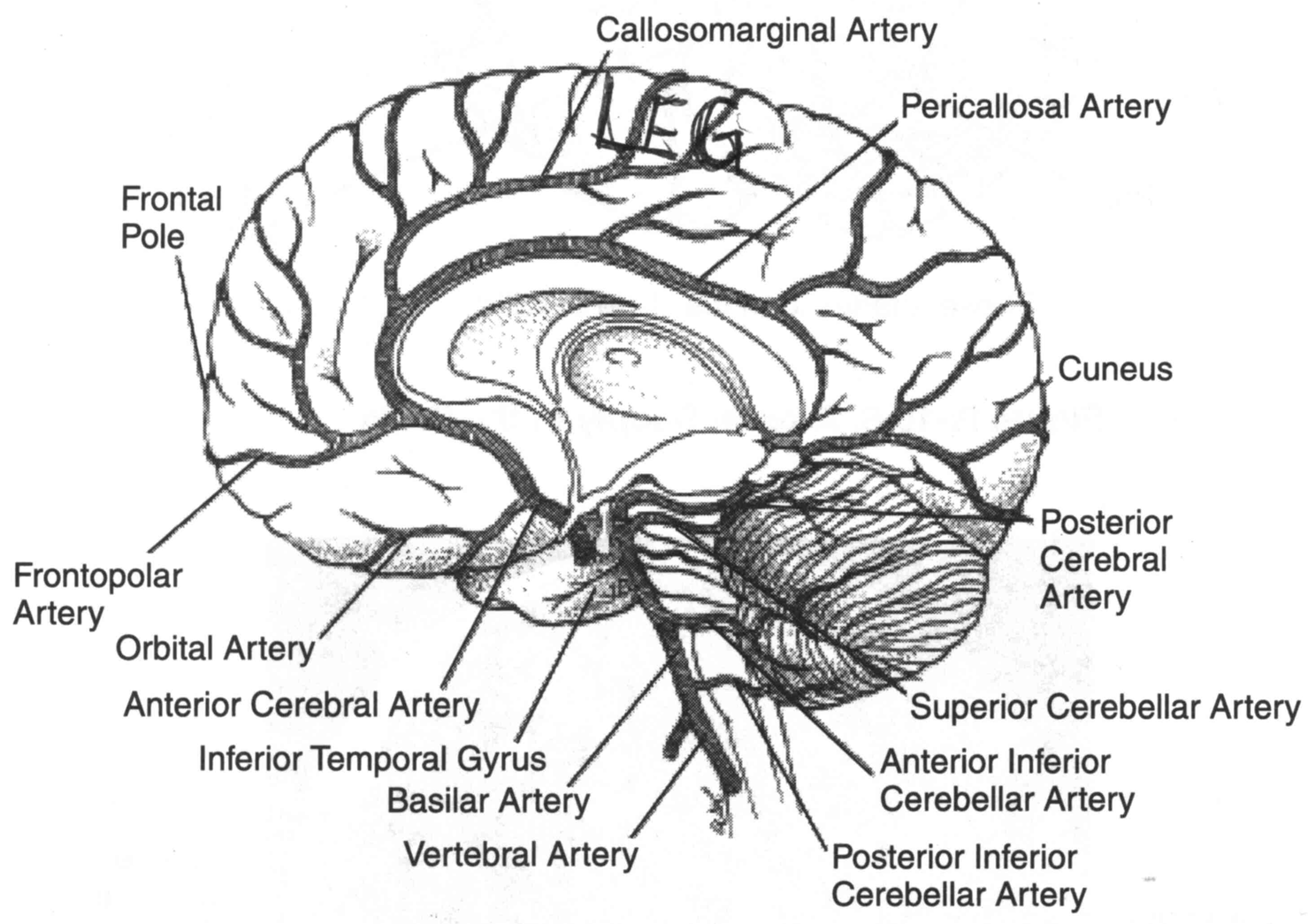

Figure IV-10-5. The Distributions of the Cerebral Arteries: II

Clinical Correlate

The most common aneurysm site in the circle of Willis is where the anterior communicating artery joins an anterior cerebral artery. The aneurysm presses on the fibers in the optic chiasm from the upper quadrant of each temporal field producing a bitemporal inferior quadrant anopsia.

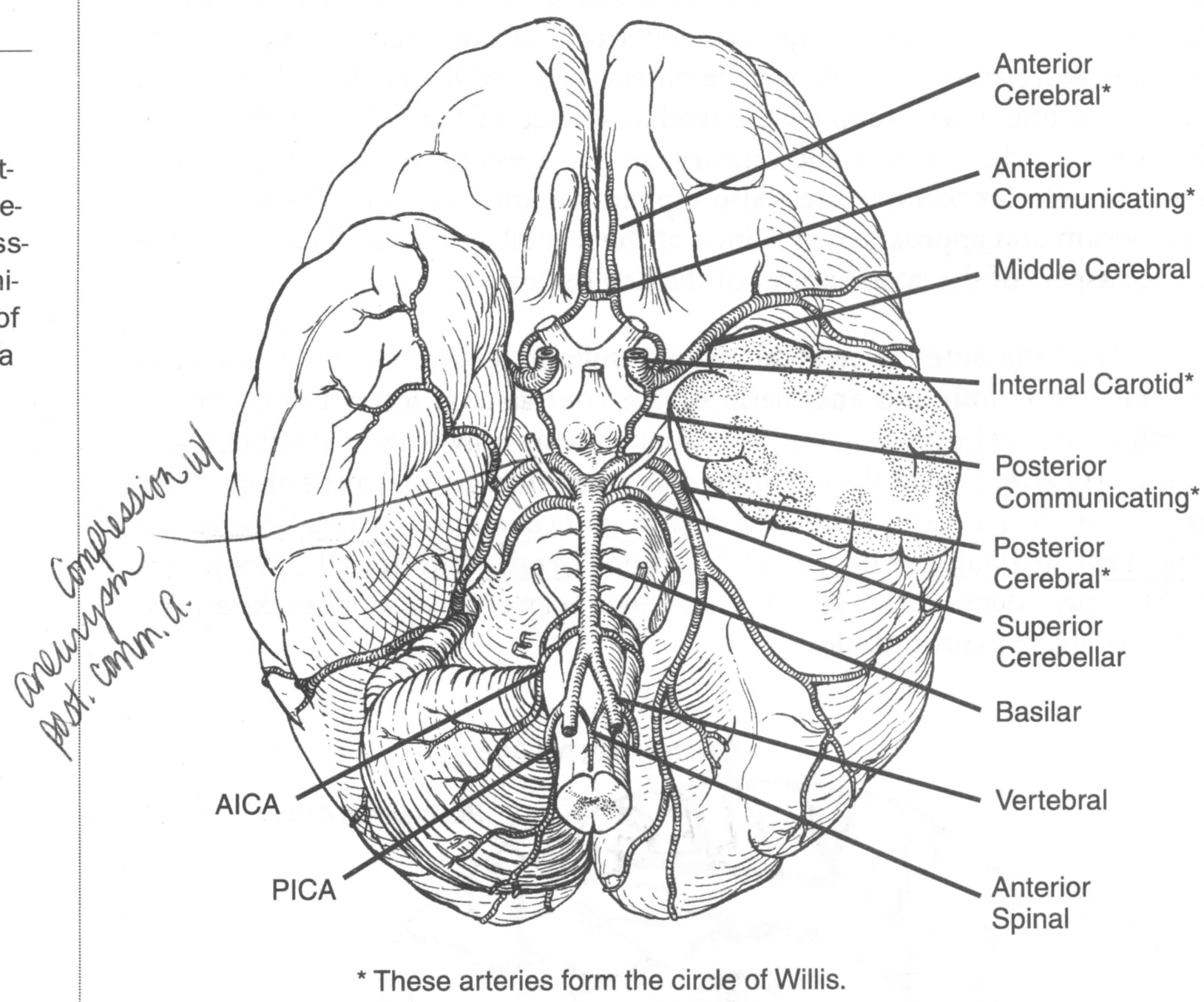

* These arteries form the circle of Willis.

Figure IV-10-6. Arterial Supply of the Brain

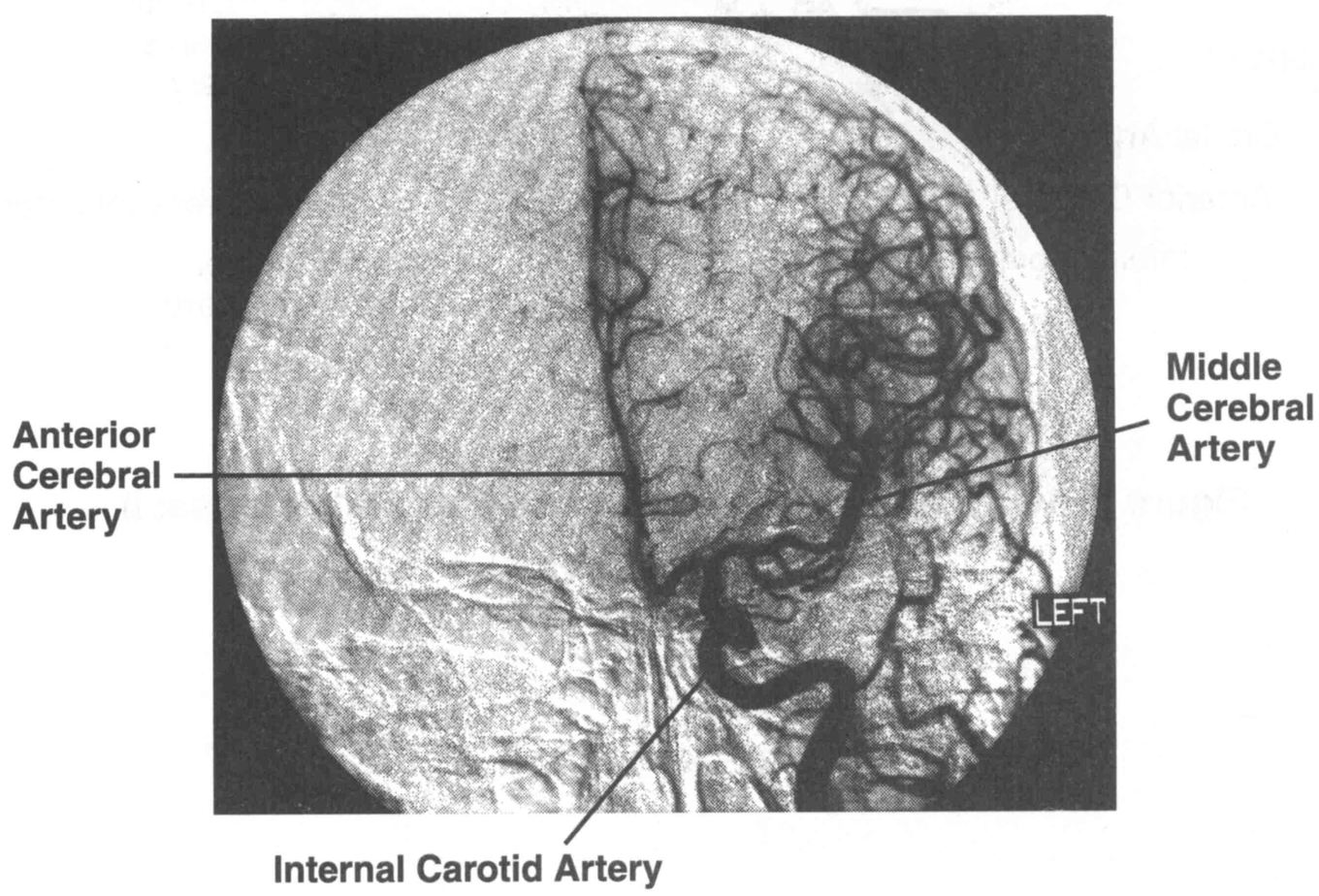

Figure IV-10-7. Anteroposterior View of Left Internal Carotid

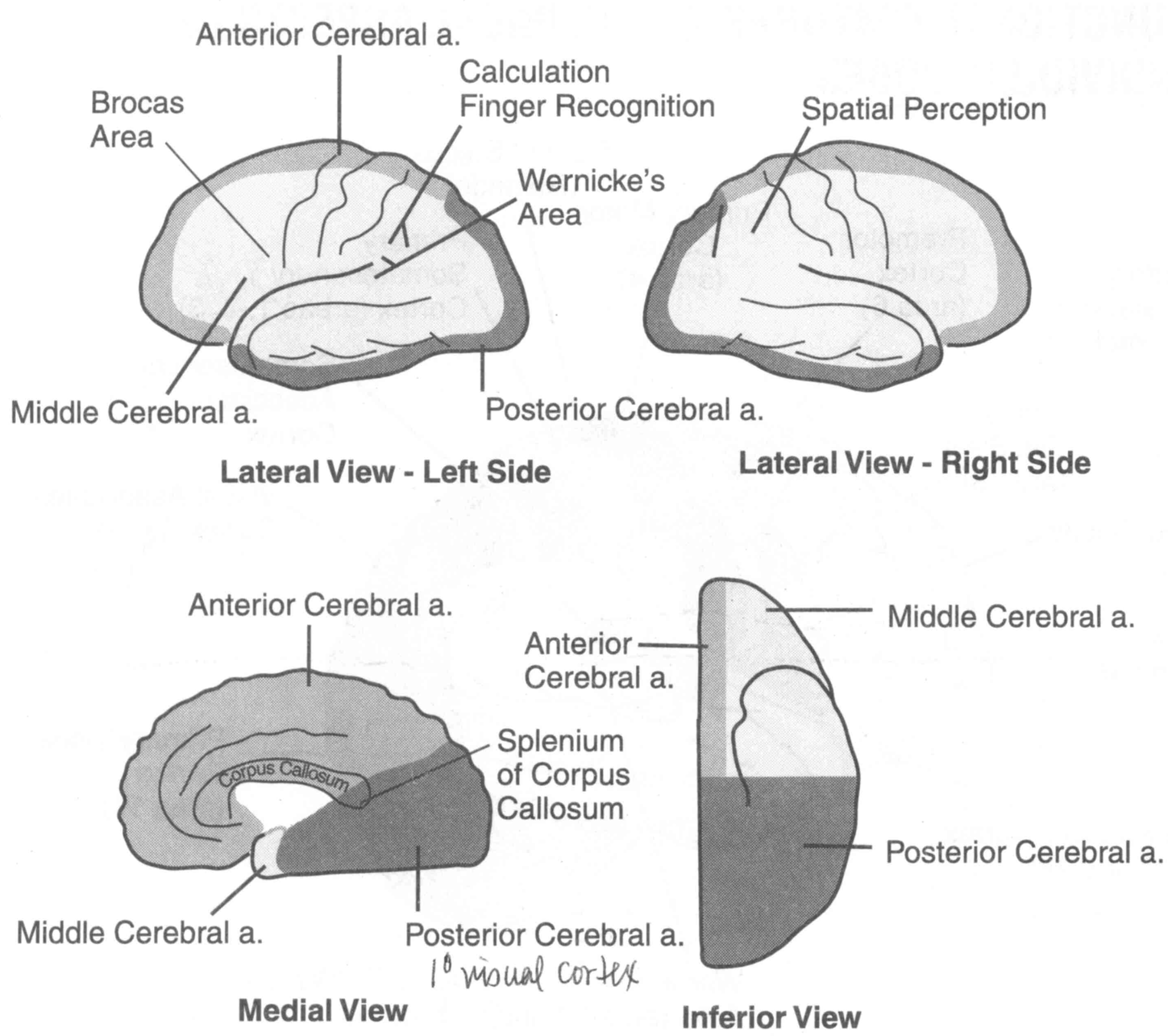

Figure IV-10-8. Territories Supplied by the Cerebral Arteries

The posterior cerebral artery is formed by the terminal bifurcation of the basilar artery. The posterior communicating artery arises near the termination of the internal carotid artery and passes posteriorly to join the posterior cerebral artery. The posterior communicating arteries complete the circle of Willis by joining the vertebrobasilar and carotid circulations. The posterior cerebral artery supplies the occipital and temporal cortex on the inferior and lateral surfaces of the hemisphere, the occipital lobe and posterior two thirds of the temporal lobe on the medial surface of the hemisphere, and the thalamus and subthalamic nucleus.

Occlusion of the posterior cerebral artery results in a homonymous hemianopia of the contralateral visual field with macular sparing.

FUNCTIONAL FEATURES AND CLINICAL ASPECTS OF INDIVIDUAL LOBES

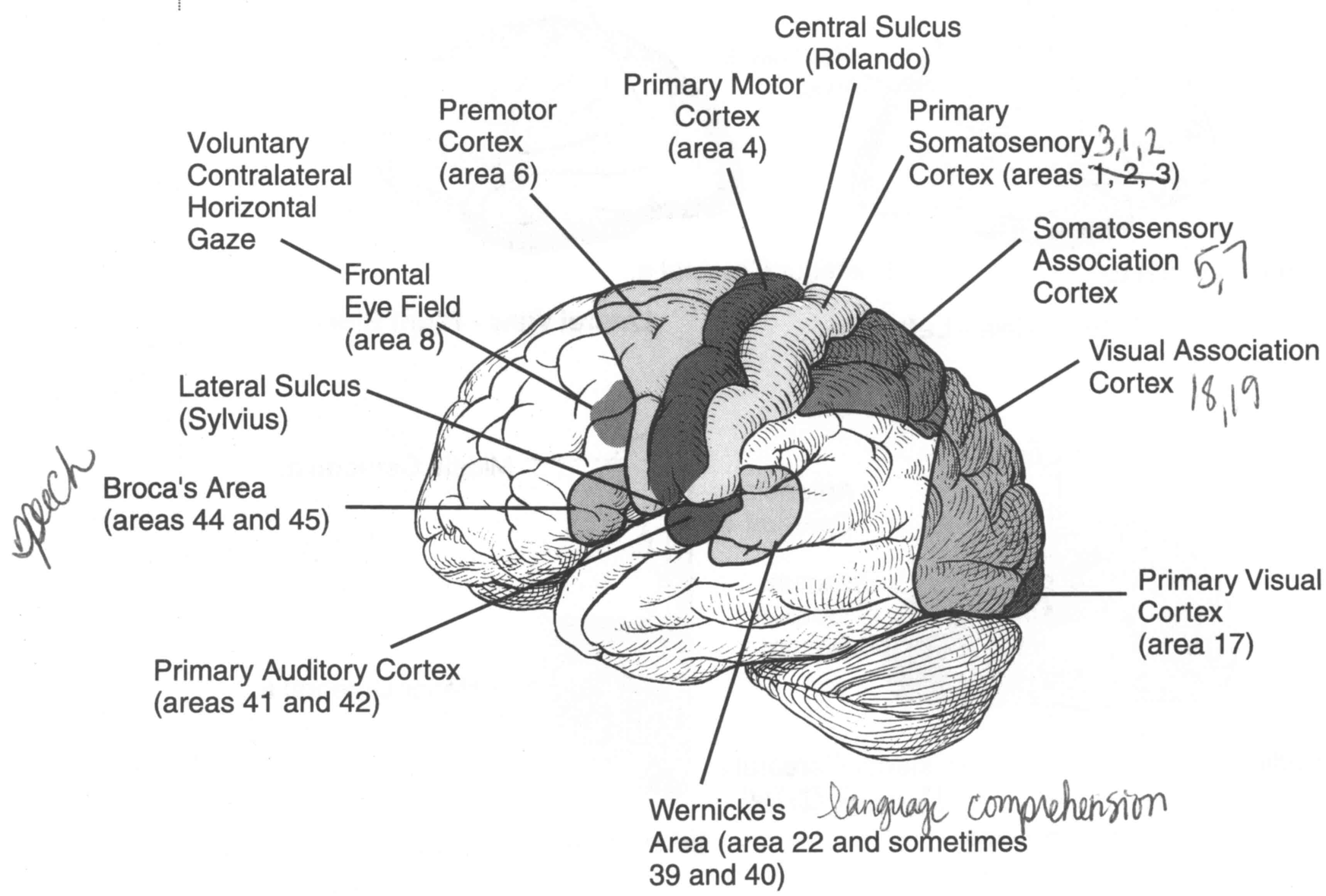

Figure IV-10-9. Cerebral Cortex: Functional Areas

Frontal Lobe

A large part of the frontal cortex rostral to the central sulcus is related to the control of movements, primarily on the opposite side of the body. These areas include primary motor cortex (Brodmann area 4), premotor cortex (area 6), the frontal eye field (area 8), and the motor speech areas of Broca (area 44 and 45). Traditionally, area 4 is considered the primary motor cortex. It is in the precentral gyrus, immediately anterior to the central sulcus, and contains an orderly skeletal motor map of the contralateral side of the body (Fig IV-10-10).

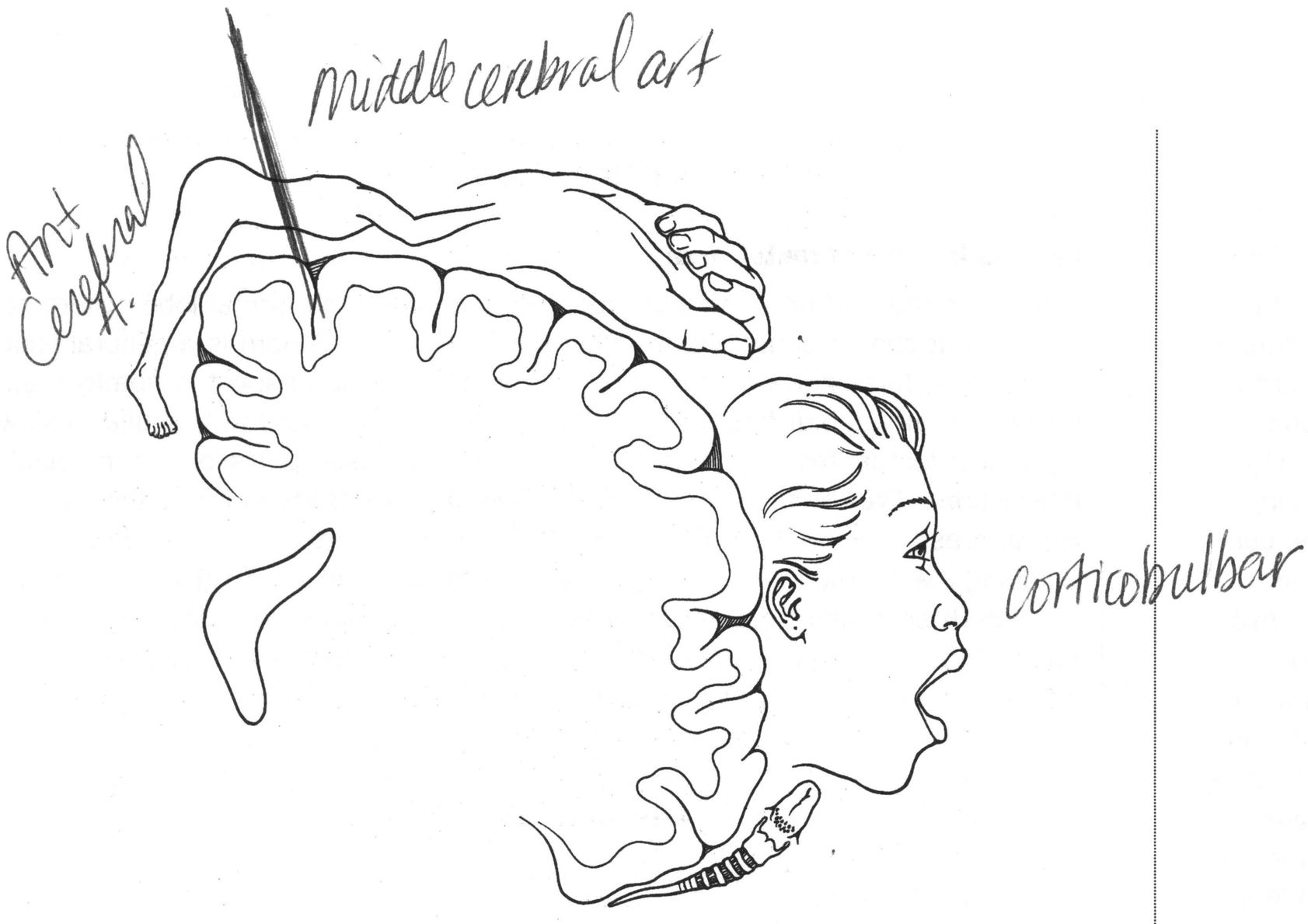

Figure IV-10-10. The Motor Homunculus in Precentral Gyrus (Area 4) Frontal Lobe

The muscles of the head are represented most ventrally closest to the lateral fissure, then, proceeding dorsally, are the regions for the neck, upper limb, and trunk on the lateral aspect of the hemisphere. On the medial aspect of the hemisphere is the motor representation for the pelvis and lower limb.

Premotor Cortex association area

Just anterior to area 4 is the premotor cortex (area 6). Neurons here are particularly active prior to the activation of area 4 neurons, so it is thought that the premotor cortex is involved in the planning of motor activities. Damage here results in an apraxia, a disruption of the patterning and execution of learned motor movements. Individual movements are intact, and there is no weakness, but the patient is unable to perform movements in the correct sequence.

Prefrontal Cortex personality

The prefrontal cortex is located in front of the premotor area and represents about a quarter of the entire cerebral cortex in the human brain. This area is involved in organizing and planning the intellectual and emotional aspects of behavior, much as the adjacent premotor cortex is involved in planning its motor aspects.

Clinical Correlate

Lesion of the Frontal Eye Field

The frontal eye field lies in front of the motor cortex in Brodmann area 8. This cortical area is the center for contralateral horizontal gaze. A lesion here results in an inability to make voluntary eye movements toward the contralateral side. Because the activity of the intact frontal eye field in the opposite cortex would also be unopposed after such a lesion, the result is conjugate slow deviation of the eyes toward the side of the lesion. If motor cortex is involved in the lesion, the patient may have a contralateral spastic paresis. The intact frontal eye field in the opposite hemisphere deviates the eyes **away** from the paralysed limbs.

Clinical Correlate

Lesions in the Prefrontal Area

Lesions in the prefrontal area produce what is called the frontal lobe syndrome. The patient cannot concentrate and is easily distracted; there is a general lack of initiative, foresight, and perspective. Another common aspect is apathy (i.e., severe emotional indifference). Apathy is usually associated with abulia, a slowing of intellectual faculties, slow speech, and decreased participation in social interactions. Prefrontal lesions also result in the emergence of infantile suckling or grasp reflexes that are suppressed in adults. In the suckling reflex, touching the cheek causes the head to turn toward the side of the stimulus as the mouth searches for a nipple to suckle. In the grasp reflex, touching the palm of the hand results in a reflex closing of the fingers, which allows an infant to grasp anything that touches the hand.

Clinical Correlate

Expressive Aphasia

Broca's area is just anterior to the motor cortex region that provides upper motoneuron innervation of cranial nerve motor nuclei. This area in the left or dominant hemisphere is the center for motor speech and corresponds to Brodmann areas 44 and 45. Damage to Broca's area produces a motor, nonfluent, or expressive aphasia that reflects a difficulty in piecing together words to produce expressive speech. Patients with this lesion can understand written and spoken language but normally say almost nothing. When pressed on a question such as "what did you do today?" they might reply "went town." The ability to write is usually also affected in a similar way (agraphia) in all aphasias, although the hand used for writing can be used normally in all other tasks. Patients are keenly aware and frustrated by an expressive aphasia, because of their lack of the ability to verbalize their thoughts orally or in writing.

Broca's area damage often extends posteriorly into the primary motor cortex and might be combined with a contralateral paralysis of the muscles of the lower face, resulting in a drooping of the corner of the mouth. If the lesion is larger, the patient might have a spastic hemiparesis of the contralateral upper limb.

Parietal Lobe

Primary Somatosensory Cortex

The parietal lobe begins just posterior to the central sulcus with the postcentral gyrus. The postcentral gyrus corresponds to Brodmann areas 3, 1, and 2 and contains primary somatosensory cortex. Like primary motor cortex, there is a similar somatotopic representation of the body here, with head, neck, upper limb, and trunk represented on the lateral aspect of the hemisphere, and pelvis and lower limb represented medially (Fig IV-10-11). These areas are concerned with discriminative touch, vibration, position sense, pain, and temperature. Lesions in

somatosensory cortex result in impairment of all somatic sensations on the opposite side of the body, including the face and scalp.

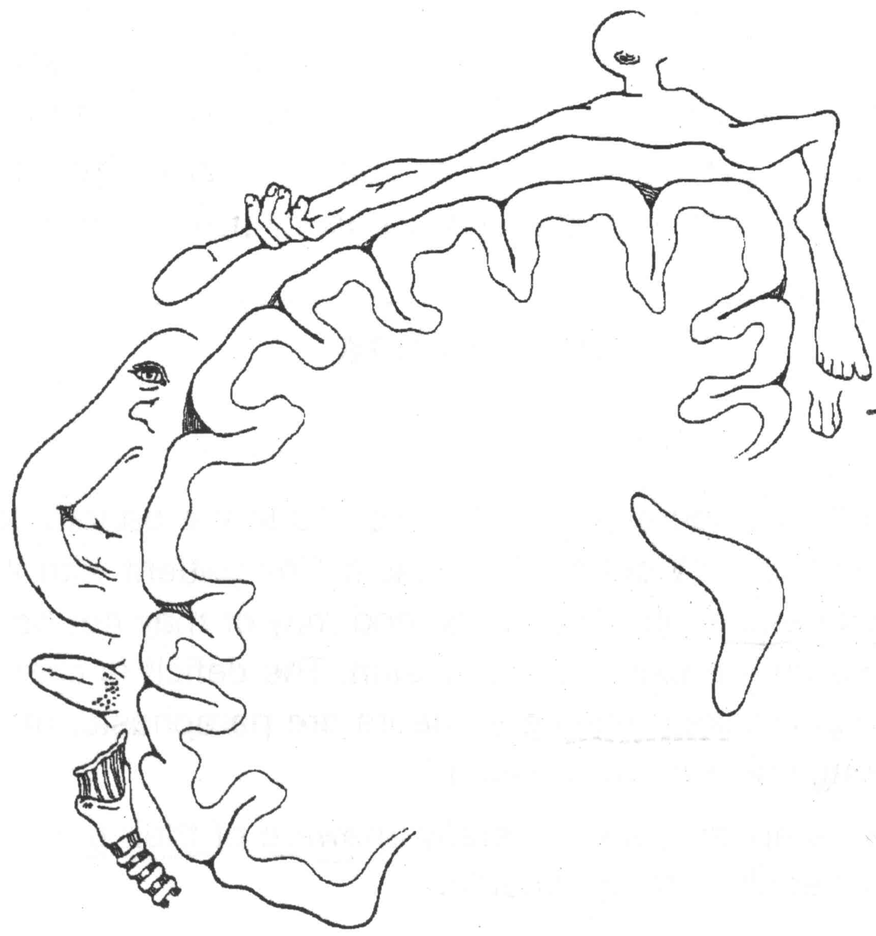

- look out for incontinence

Figure IV-10-11. The Sensory Homunculus in Postcentral Gyrus (Areas 3, 1, 2) Parietal Lobe

Posterior Parietal Association Cortex

Just posterior and ventral to the somatosensory areas is the posterior parietal association cortex, including Brodmann areas 5 and 7.

Clinical Correlate

Lesions, usually in the dominant hemisphere and which include areas 5 and 7 of the posterior parietal association areas, often result in apraxia (also seen with lesions to the premotor cortex). Apraxia is a disruption of the patterning and execution of learned motor movements. This deficit seems to reflect a lack of understanding how to organize the performance of a pattern of movements (i.e., what should be done first, then next, etc.). The patient may be unable, for example, to draw a simple diagram (constructional apraxia) or describe how to get from his home to work.

Another deficit, with lesions of areas 5 and 7 is astereognosia (inability to recognize objects by touch). There is no loss of tactile or proprioceptive sensation; rather, it is the integration of visual and somatosensory information that is impaired. Both apraxia and astereognosia are more common after left hemisphere damage than in right hemisphere damage. The astereognosia is usually confined to the contralateral side of the body; in contrast, apraxia is usually bilateral. Apraxia is probably a result of the loss of input to the premotor cortex (area 6), which is involved in the actual organization of motor movements into a goal-directed pattern.

Note

Any blockage of the left middle cerebral artery that results in an aphasia (Broca's Wernicke's, conduction) or Gerstmann's syndrome will also result in **agraphia**.

Wernicke's Area

The inferior part of the parietal lobe and adjacent part of the temporal lobe in the dominant (left) hemisphere, known as Wernicke's area, are cortical regions that function in language comprehension. At a minimum, Wernicke's area consists of area 22 in the temporal lobe but may also include areas 39 and 40 in the parietal lobe. Areas 39 (the angular gyrus) and 40 (the supramarginal gyrus) are regions of convergence of visual, auditory, and somatosensory information.

Clinical Correlate

Receptive Aphasia

Lesions in area 22 in the temporal lobe and 39 or 40 in the parietal lobe produce a nonfluent, receptive, or Wernicke's aphasia. The patient with Wernicke's aphasia cannot comprehend spoken language and may or may not be able to read (alexia) depending on the extent of the lesion. The deficit is characterized by fluent verbalization but lacks meaning. Patients are paraphasic, often misusing words as if speaking using a "word salad."

Patients with Wernicke's aphasia are generally unaware of their deficit and show no distress as a result of their condition.

Gerstmann's Syndrome

If the lesion is confined to just the angular gyrus (area 39), the result is a loss of ability to comprehend just written language (alexia) and to write it (agraphia), but spoken language may be understood. Alexia with agraphia in pure angular gyrus lesions is often seen with three other unique symptoms: acalculia (loss of the ability to perform simple arithmetic problems), finger agnosia (inability to recognize one's fingers), and right–left disorientation. This constellation of deficits constitutes Gerstmann's syndrome and underscores the role of this cortical area in the integration of how children begin to count, add, and subtract using their fingers.

Conduction Aphasia

There is a large fiber bundle connecting areas 22, 39, and 40 with Broca's area in the frontal lobe, known as the superior longitudinal fasciculus (or the arcuate fasciculus). A lesion affecting this fiber bundle results in a conduction aphasia. In this patient, verbal output is fluent, but there are many paraphrases and word-finding pauses. Both verbal and visual language comprehension are also normal, but if asked to, the patient cannot repeat words or execute verbal commands by an examiner (such as count backwards beginning at 100) and also demonstrates poor object naming. This is an example of a **disconnect** syndrome in which the deficit represents an inability to send information from one cortical area to another. Like an expressive aphasia, the patient is aware of the deficit and is frustrated by their inability to execute a verbal command that they fully understand.



Clinical Correlate *(continued)*

Transcortical Apraxia

Lesions to the corpus callosum caused by an infarct of the anterior cerebral artery may result in another type of disconnect syndrome known as a transcortical apraxia. As in other cases of apraxia, there is no motor weakness, but the patient cannot execute a command to move their left arm. They understand the command, which is perceived in Wernicke's area of the left hemisphere, but the callosal lesion disconnects Wernicke's area from the right primary motor cortex so that the command cannot be executed. The patient is still able to execute a command to move the right arm because Wernicke's area in the left hemisphere is able to communicate with the left primary motor cortex without using the corpus callosum.

Asomatognosia

The integration of visual and somatosensory information is important for the formation of the "body image" and awareness of the body and its position in space. Widespread lesions in areas 7, 39, and 40 in the nondominant right parietal lobe may result in unawareness or neglect of the contralateral half of the body known as asomatognosia. Although somatic sensation is intact, the patients ignore half of their body and may fail to dress, undress, or wash the affected (left) side. Patients will have no visual field deficits, so they can see, but deny the existence of things in the left visual field. Asking them to bisect a horizontal line produces a point well to the right of true center. If asked to draw a clock face from memory, they will draw only numbers on the right side, ignoring those on the left. The patients may deny that the left arm or leg belongs to them when the affected limb is passively brought into their field of vision. Patients may also deny their deficit, an anosognosia.

Occipital Lobe

The occipital lobe is essential for the reception and recognition of visual stimuli and contains primary visual and visual association cortex.

Visual Cortex

The visual cortex is divided into striate (area 17) and extrastriate (areas 18 and 19). Area 17, also referred to as the primary visual cortex, lies on the medial portion of the occipital lobe on either side of the calcarine sulcus. Its major thalamic input is from the lateral geniculate nucleus. Some input fibers are gathered in a thick bundle that can be visible on the cut surface of the gross brain, called the line of Gennari. The retinal surface (and therefore the visual field) is represented in an orderly manner on the surface of area 17, such that damage to a discrete part of area 17 will produce a scotoma (i.e., a blind spot) in the corresponding portion of the visual field. A unilateral lesion inside area 17 results in a contralateral homonymous hemianopsia with macular sparing, usually caused by an

infarct of a branch of the posterior cerebral artery. The area of the macula of the retina containing the fovea is spared because of a dual blood supply from both the posterior and middle cerebral arteries. The actual cortical area serving the macula is represented in the most posterior part of the occipital lobe. Blows to the back of the head or a blockage in occipital branches of the middle cerebral artery that supply this area may produce loss of macular representation of the visual fields. Bilateral visual cortex lesions result in cortical blindness; the patient cannot see, but pupillary reflexes are intact.

Visual Association Cortex

Anterior to the primary visual or striate cortex are extensive areas of visual association cortex. Visual association cortex is distributed throughout the entire occipital lobe and in the posterior parts of the parietal and temporal lobes. These regions receive fibers from the striate cortex and integrate complex visual input from both hemispheres. From the retina to the visual association cortex, information about form and color, versus motion, depth and spatial information are processed separately. Form and color information is processed by the parvocellular-blob system. This "cone stream" originates mainly in the central part of the retina, relays through separate layers of the lateral geniculate, and projects to blob zones of primary visual cortex. Blob zones project to the inferior part of the temporal lobe in areas 20 and 21. Unilateral lesions here result in achromatopsia, a complete loss of color vision in the contralateral hemifields. Patients see everything in shades of gray. Additionally, these patients may also present with prosopagnosia, an inability to recognize faces.

Motion and depth are processed by the magnocellular system. This "rod stream" originates in the peripheral part of the retina, relays through separate layers of the lateral geniculate, and projects to thick stripe zones of primary visual cortex. Striped areas project through the middle temporal lobe to the parietal lobe in areas 18 and 19. Lesions here result in a deficit in perceiving visual motion; visual fields, color vision, and reading are unaffected (Fig IV-10-8).

Clinical Correlate

Visual Agnosia

Damage to parts of the temporal lobes involving the cone stream produces a visual agnosia. Visual agnosia is the inability to recognize visual patterns (including objects) in the absence of a visual field deficit. For example, you might show a patient with an object agnosia a pair of glasses, and the patient would describe them as two circles and a bar. Lesions in areas 20 and 21 of the temporal lobe that also include some destruction of adjacent occipital lobe in either hemisphere result in prosopagnosia, a specific inability to recognize faces. The patient can usually read and name objects. The deficiency is an inability to form associations between faces and identities. On hearing the voice of the same person, the patient can immediately identify the person.

Alexia Without Agraphia

A principal "higher-order" deficit associated with occipital lobe damage is alexia without agraphia (or pure word blindness). The patients are unable to read at all and, curiously, often have a color anomia (inability to name colors). However, they are able to write. This is another example of a disconnect syndrome in which information from the occipital lobe is not available to the parietal or frontal lobes to either understand or express what has been seen.
(Recall that alexia with agraphia—inability to read or write—occurs with lesions encompassing the angular gyrus in the dominant parietal lobe.) The cause of the syndrome is usually an infarction of the left posterior cerebral artery that affects not only the anterior part of the occipital lobe but the splenium of the corpus callosum. Involvement of the left occipital cortex results in a right homonymous hemianopsia with macular sparing. Involvement of the splenium of the corpus callosum prevents visual information from the intact right occipital cortex from reaching language comprehension centers in the left hemisphere. Patients can see words in the left visual field but do not understand what the words mean.

Temporal Lobe

Primary Auditory Cortex

On its superior and lateral aspect, the temporal lobe contains the primary auditory cortex. Auditory cortex (areas 41 and 42) is located on the two transverse gyri of Heschl, which cross the superior temporal lobe deep within the lateral sulcus. Much of the remaining superior temporal gyrus is occupied by area 22 (auditory association cortex), which receives a considerable projection from both areas 41 and 42 and projects widely to both parietal and occipital cortices.

Patients with unilateral damage to the primary auditory cortex show little loss of auditory sensitivity but have some difficulty in localizing sounds in the contralateral sound field. Area 22 is a component of Wernicke's area in the dominant hemisphere, and lesions here produce a Wernicke's aphasia.

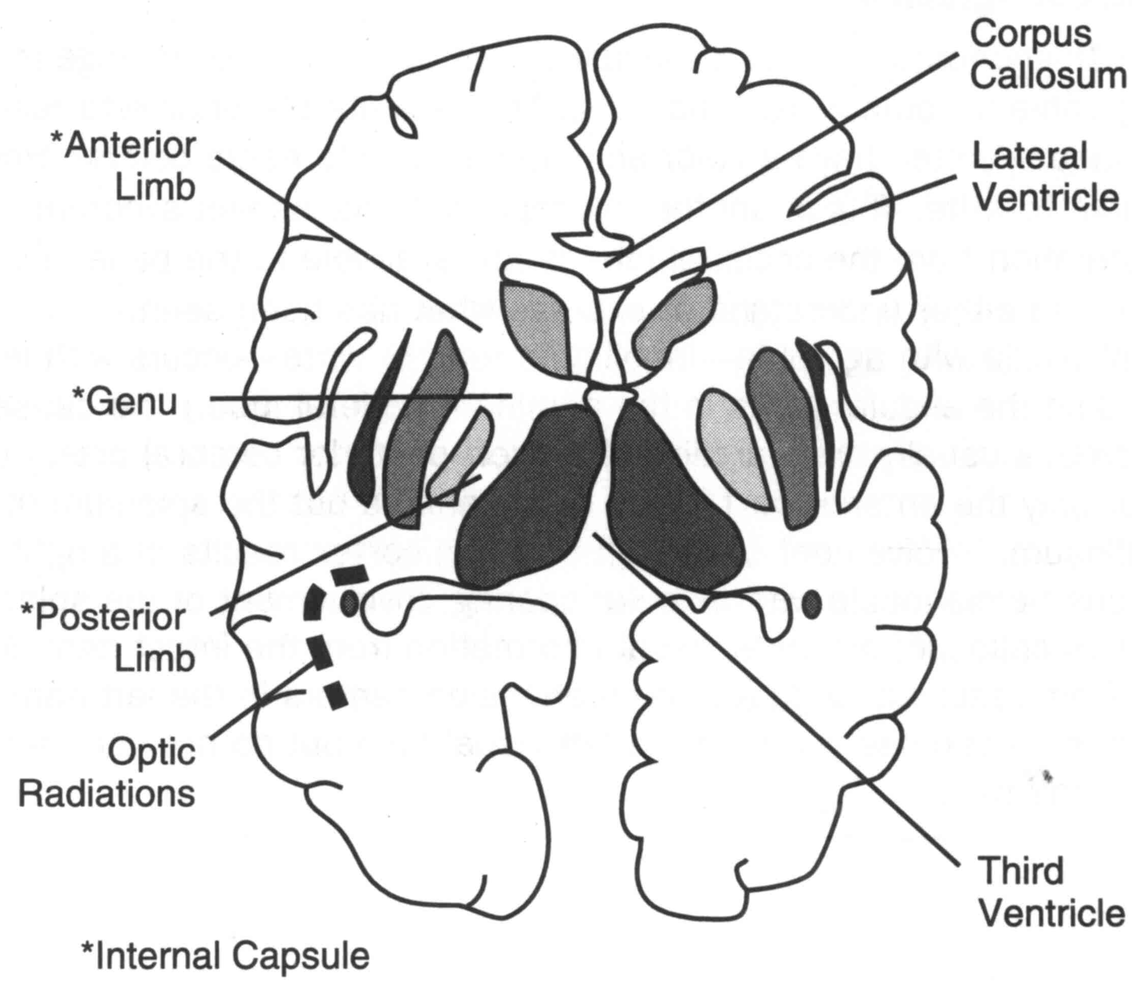

Figure IV-10-12. Internal Capsule: Arterial Supply

Table IV-10-1. Internal Capsule: Arterial Supply

Internal Capsule	Arterial Supply	Tracts
Anterior limb	Anterior cerebral artery	Thalamocortical
Genu	Middle cerebral artery	Corticobulbar
Posterior limb	Middle cerebral artery Lenticulostriate	Corticospinal, all somatosensory thalamocortical projections

Note: The posterior cerebral artery also supplies the optic radiations

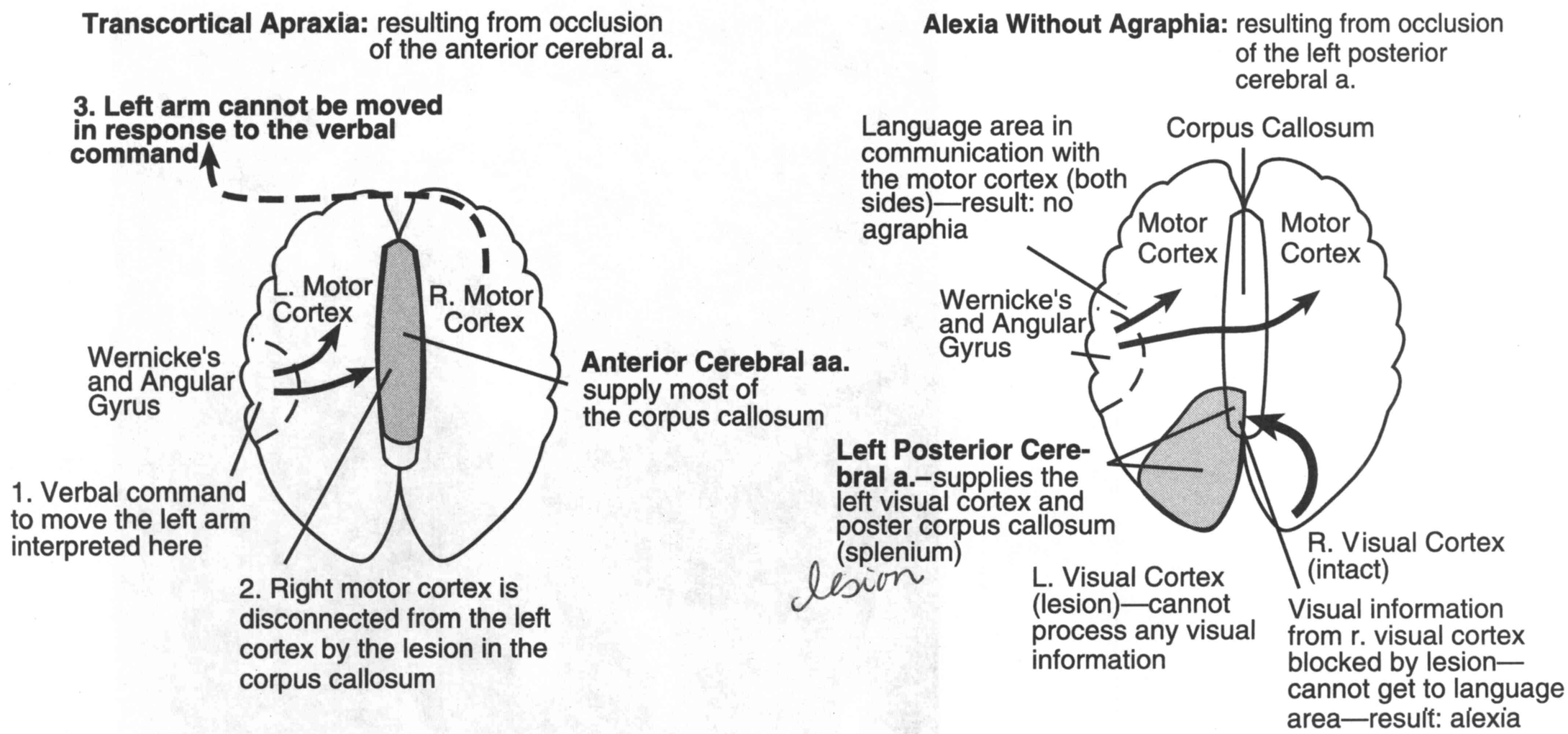

Figure IV-10-13. Symptoms Following Occlusion of the Cerebral Arteries

Table IV-10-2. Symptoms Following Occlusion of the Cerebral Arteries

Anterior Cerebral	Middle Cerebral		Posterior Cerebral
Contralateral spastic paralaysis and anesthesia of the lower limbs	Contralateral spastic paralysis and anesthesia of the body excluding the lower limbs (mainly arms and face)		Contralateral homonomous hemianopsia (usually with macular sparing)
Urinary incontinence	LEFT SIDE	RIGHT SIDE	LEFT SIDE: Alexia without agraphia (see above)—cannot read, but can write
Transcortical apraxia—cannot move left arm in response to a command	Aphasias: Broca's, Wernicke's, or Global	Parietal lobe: 1. Inattention and neglect of the contralateral side of the body 2. Spatial perception defects	
	Gerstmann's Syndrome (parietal lobe-angular gyrus): 1. R-L disorientation 2. Finger agnosia 3. Acalcula 4. Agraphia		

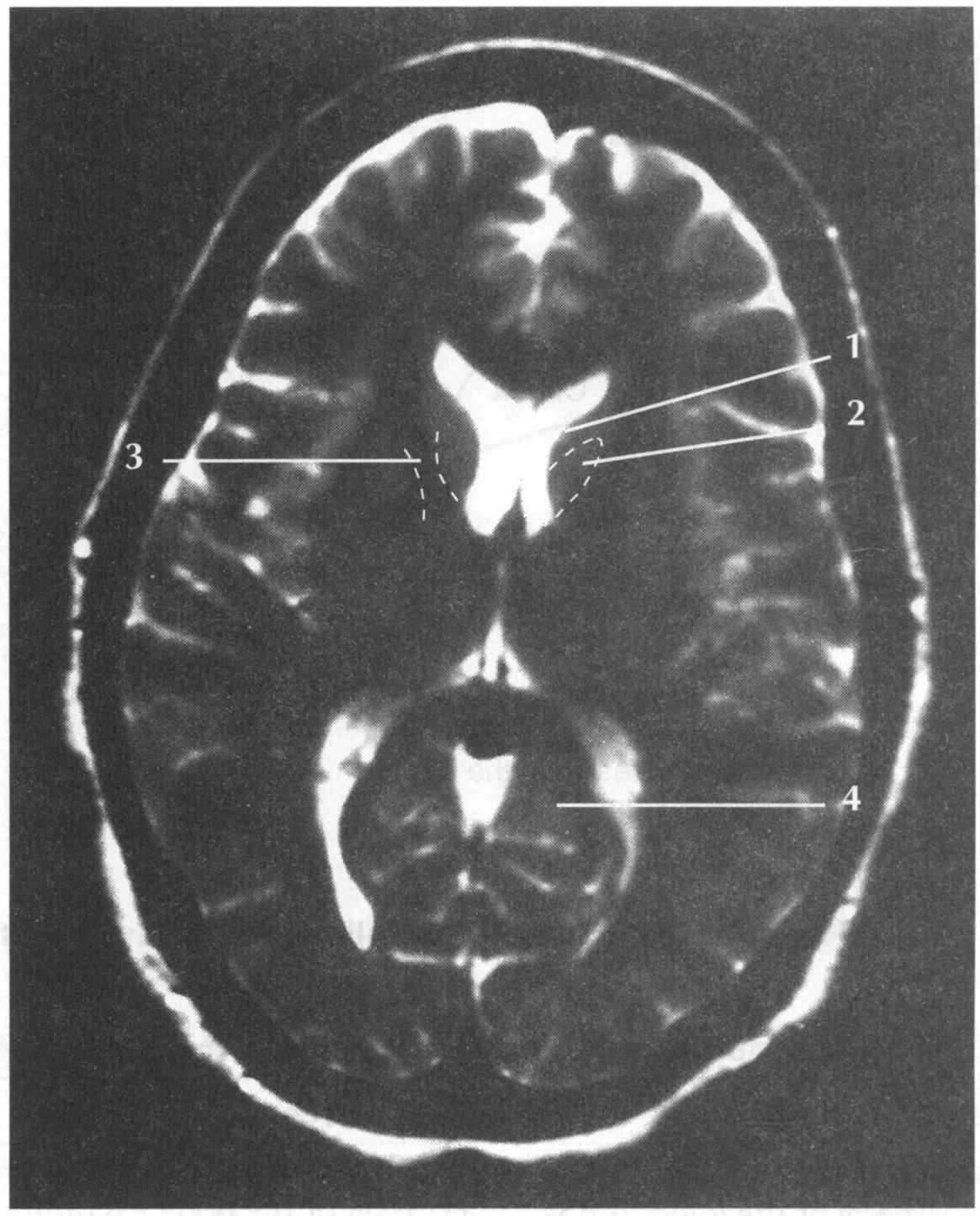

1. Lateral Ventricle
2. Caudate nucleus
3. Internal Capsule
4. Cerebellum

Figure IV-10-14. Horizontal Section

The Limbic System

11

GENERAL FEATURES

The limbic system is involved in emotion, memory, attention, feeding, and mating behaviors. It consists of a core of cortical and diencephalic structures found on the medial aspect of the hemisphere. A prominent structure in the limbic system is the hippocampal formation on the medial aspect of the temporal lobe. The hippocampal formation extends along the floor of the inferior horn of the lateral ventricle in the temporal lobe and includes the hippocampus, the dentate gyrus, the subiculum, and adjacent entorhinal cortex. The hippocampus is characterized by a three-layered cerebral cortex. Other limbic-related structures include the amygdala, which is located deep in the medial part of the anterior temporal lobe rostral to the hippocampus, and the septal nuclei, located medially between the anterior horns of the lateral ventricle. The limbic system is interconnected with thalamic and hypothalamic structures, including the anterior and dorsomedial nuclei of the thalamus and the mammillary bodies of the hypothalamus. The cingulate gyrus is the main limbic cortical area. The cingulate gyrus is located on the medial surface of each hemisphere above the corpus callosum. Limbic-related structures also project to wide areas of the prefrontal cortex.

OLFACTORY SYSTEM

Central projections of olfactory structures reach parts of the temporal lobe and the amygdala. The olfactory nerve consists of numerous fascicles of the central processes of bipolar neurons, which reach the anterior cranial fossa from the nasal cavity through openings in the cribriform plate of the ethmoid bone. These primary olfactory neurons differ from other primary sensory neurons in two

Clinical Correlate

Alzheimer's disease results from neurons, beginning in the hippocampus, that exhibit neurofibrillary tangles and amyloid plaques. Other nuclei affected are the cholinergic neurons in the nucleus basalis of Meynert, noradrenergic neurons in the locus coeruleus, and serotonergic neurons in the raphe nuclei. Patients with Down syndrome commonly present with Alzheimer's in middle age because chromosome 21 is one site of a defective gene.

ways. First, the cell bodies of these neurons, which lie scattered in the olfactory mucosa, are not collected together in a sensory ganglion, and second, primary olfactory neurons are continuously replaced. The life span of these cells ranges from 30 to 120 days in mammals.

Within the mucosa of the nasal cavity, the peripheral process of the primary olfactory neuron ramifies to reach the surface of the mucous membrane. The central processes of primary olfactory neurons terminate by synapsing with neurons found in the olfactory bulb. The bulb is a six-layered outgrowth of the brain that rests on the cribriform plate. Olfactory information entering the olfactory bulb undergoes a great deal of convergence before the olfactory tract carries axons from the bulb to parts of the temporal lobe and amygdala.

Clinical Correlate

Olfactory Deficits

Olfactory deficits may be incomplete (hyposmia), distorted (dysosmia), or complete (anosmia). Olfactory deficits are caused by transport problems or by damage to the primary olfactory neurons or to neurons in the olfactory pathway to the CNS. Head injuries that fracture the cribriform plate can tear the central processes of olfactory nerve fibers as they pass through the plate to terminate in the olfactory bulb, or they may injure the bulb itself. Because the olfactory bulb is an outgrowth of the CNS covered by meninges, separation of the bulb from the plate may tear the meninges, resulting in CSF leaking through the cribriform plate into the nasal cavity.

THE PAPEZ CIRCUIT

A summary of the simplified connections of the limbic system is expressed by the Papez circuit (Fig IV-11-1). The Papez circuit oversimplifies the role of the limbic system in modulating feelings, such as fear, anxiety, sadness, happiness, sexual pleasure, and familiarity; yet, it provides a useful starting point for understanding the system. Arbitrarily, the Papez circuit begins and ends in the hippocampus. Axons of hippocampal pyramidal cells converge to form the fimbria and, finally, the fornix. The fornix projects mainly to the mammillary bodies in the hypothalamus. The mammillary bodies, in turn, project to the anterior nucleus of the thalamus by way of the mammillothalamic tract. The anterior nuclei project to the cingulate gyrus through the anterior limb of the internal capsule, and the cingulate gyrus communicates with the hippocampus through the cingulum and entorhinal cortex.

The amygdala functions to attach an emotional significance to a stimulus and helps imprint the emotional response in memory.

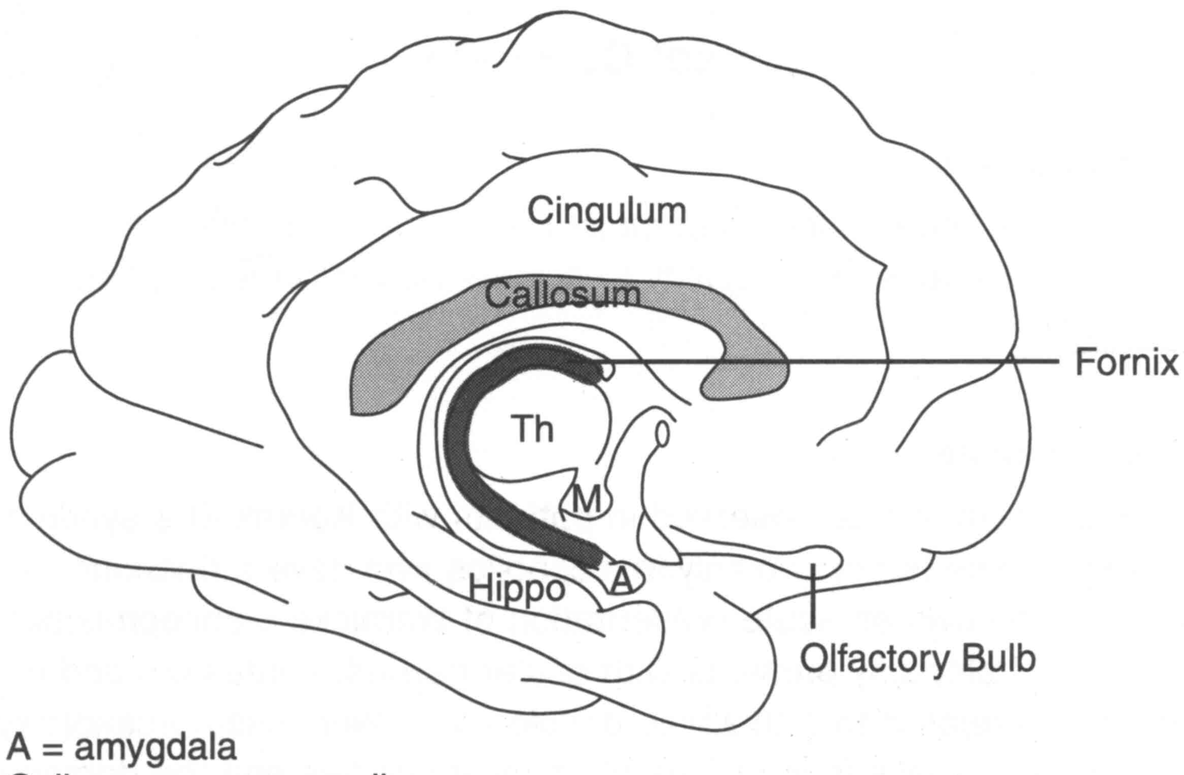

A = amygdala
Callosum = corpus callosum
M = mammillary body
Th = thalamus
Hippo = hippocampus

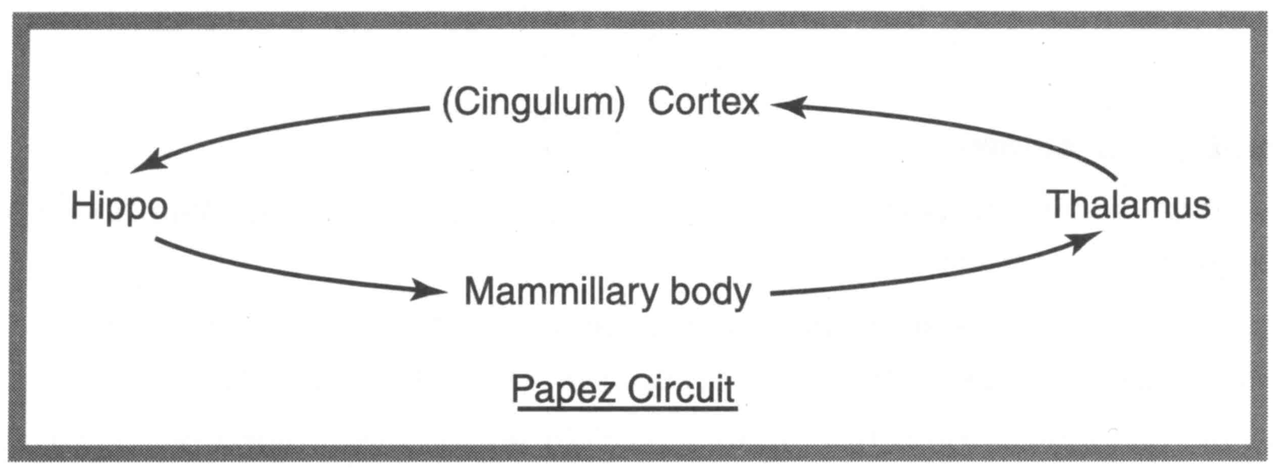

Figure IV-11-1. The Limbic System

Clinical Correlate

Alzheimer's Disease and Anterograde Amnesia
Alzheimer's patients lose episodic memory (events in time) earliest and most severly. Also impaired may be working memory (short-term retention) and semantic memory (objects or facts). Procedural memory (how to use tools) is affected late.

Korsakoff's patients have both anterograde and retrograde amnesia but it is limited to episodic memory.

Clinical Correlate

Thiamine treatment improves signs of Wernicke's encephalopathy, but it does not reverse amnesia in Korsakoff's syndrome.

Clinical Correlate

consolidation of memory

Anterograde Amnesia

Bilateral damage to the medial temporal lobes including the hippocampus results in a profound loss of the ability to acquire new information, known as anterograde amnesia.

Korsakoff's Syndrome

Anterograde amnesia is also observed in patients with Korsakoff's syndrome. Korsakoff's syndrome is seen mainly in alcoholics who have a thiamine deficiency and often follows an acute presentation of Wernicke's encephalopathy. Wernicke's encephalopathy presents with ocular palsies, confusion, and gait ataxia and is also related to a thiamine deficiency. In Wernicke-Korsakoff syndrome, lesions are always found in the mammillary bodies and the dorsomedial nuclei of the thalamus.

In addition to exhibiting an anterograde amnesia, Korsakoff's patients also present with retrograde amnesia. These patients confabulate, making up stories to replace past memories they can no longer retrieve.

Klüver-Bucy Syndrome

Klüver-Bucy syndrome results from bilateral lesions of the amygdala and hippocampus. These lesions result in:

- Placidity—there is marked decrease in aggressive behavior; the subjects become passive, exhibiting little emotional reaction to external stimuli.
- Psychic blindness—objects in the visual field are treated inappropriately. For example, monkeys may approach a snake or a human with inappropriate docility.
- Hypermetamorphosis—visual stimuli (even old ones) are repeatedly approached as though they were completely new.
- Increased oral exploratory behavior—monkeys put everything in their mouths, eating only appropriate objects.
- Hypersexuality and loss of sexual preference
- Anterograde amnesia

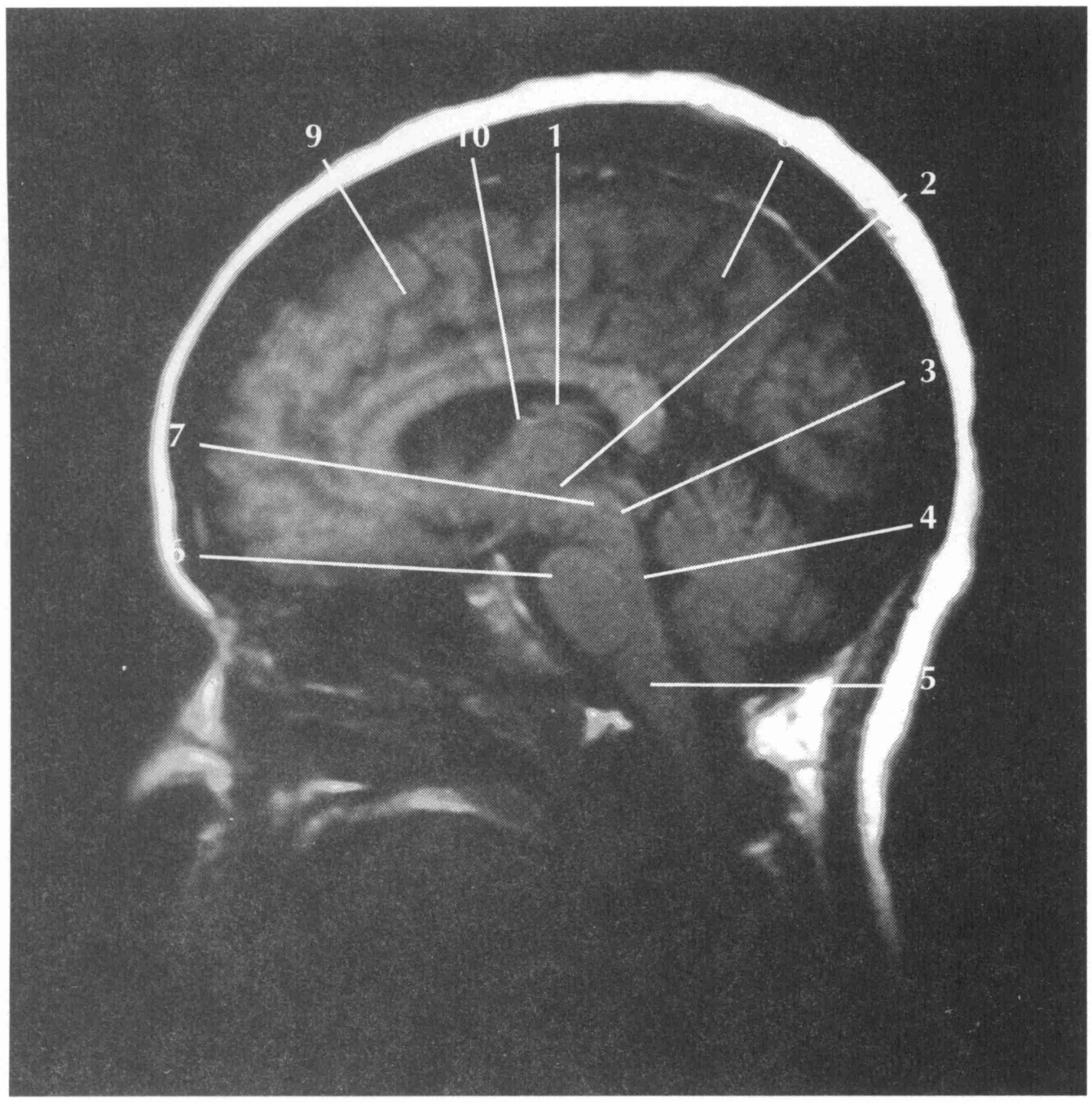

1. Corpus Callosum
2. Thalamus
3. Tectum (superior and inferior colliculi)
4. Fourth Ventricle
5. Medulla
6. Pons
7. Cerebral Aqueduct
8. Superior Sagittal Sinus
9. Subarachnoid Space
10. Lateral Ventricle

Figure IV-11-2. Sagital View of the Brain